

# Borderline Endometrioid Adenocarcinoma of the Ovary Arising in Endometriosis During Tamoxifen Therapy of Postmenopausal Breast Cancer

POSTMENOPOZAL MEME KANSERİ TEDAVİSİNDE KULLANILAN TAMOKSİFEN İLE ENDOMETRİOSİS ZEMİNİNDE GELİŞEN OVER BORDERLINE ENDOMETRİOİD ADENOKANSERİ

Tufan BİLGİN\*, Nedret KOLSAL\*\*, Candan CENGİZ\*, Ömer YERCİ\*\*\*

\* Prof.Dr., Department of Obstetrics and Gynecology, Uludağ University Faculty of Medicine,

\*\* Dr., Department of Obstetrics and Gynecology, Uludağ University Faculty of Medicine,

\*\*\* Prof.Dr., Department of Pathology, Uludağ University Faculty of Medicine, Bursa, TURKEY

## Summary

**Objective:** Tamoxifen has antiestrogenic activity and widely used to treat breast cancer. It also exerts weak estrogenic activity in postmenopausal women where estrogenic environment is low.

**Case Report:** A 75 year old woman receiving tamoxifen for her breast cancer developed a borderline endometrioid adenocarcinoma of the ovary arising in endometriosis is presented.

**Conclusion:** She was surgically staged as I C due to surgical rupture of the cyst. She is well and free of disease after five years.

**Key Words:** Tamoxifen,  
Borderline endometrioid adenocarcinoma, Ovary

T Klin J Gynecol Obst 2003, 13:152-154

## Özet

**Amaç:** Meme kanseri tedavisinde yaygın kullanılan tamoksifenin antiestrogenik aktivitesi vardır. Estrojenik ortamın düşük olduğu postmenopozal kadınlarda zayıf estrojenik aktivite gösterilebilir.

**Olgu Sunumu:** Meme kanseri nedeniyle tamoksifen almakta olan 75 yaşındaki hastada endometriosis zemininde gelişen over borderline endometrioid adenokanser olgusu sunuldu.

**Sonuç:** Kistin cerrahi sırasında rüptürüne bağlı olarak cerrahi evre I C olarak evrelendirildi. Beş yıl sonra hasta sağ ve hastaliksız olarak yaşamını sürdürmektedir.

**Anahtar Kelimeler:** Tamoksifen,  
Borderline endometrioid adenokanser, Over

T Klin Jinekoloj Obst 2003, 13:152-154

Malignant transformation of endometriosis has been well documented by Sampson (1). Foci of endometriosis usually regress following menopause since estrogenic stimulus disappears. Estrogen replacement therapy may activate these foci. Tamoxifen is a well known unique drug which has antiestrogenic activity and is widely used to treat breast cancer. This drug competes with estrogens upon the level of receptors and has some weak estrogenic activity. It has been reported that it may induce endometrial hyperplasia, polyps, even cancer (2,3). Endometriosis has also been reported to develop in postmenopausal women with tamoxifen and recently two endometrioid carcinomas arisen in endometriosis during tamoxifen treatment have been reported (4,5).

This following is a case of borderline endometrioid adenocarcinoma arising from endometriosis of the ovary in a postmenopausal breast cancer patient treated with tamoxifen.

## Case Report

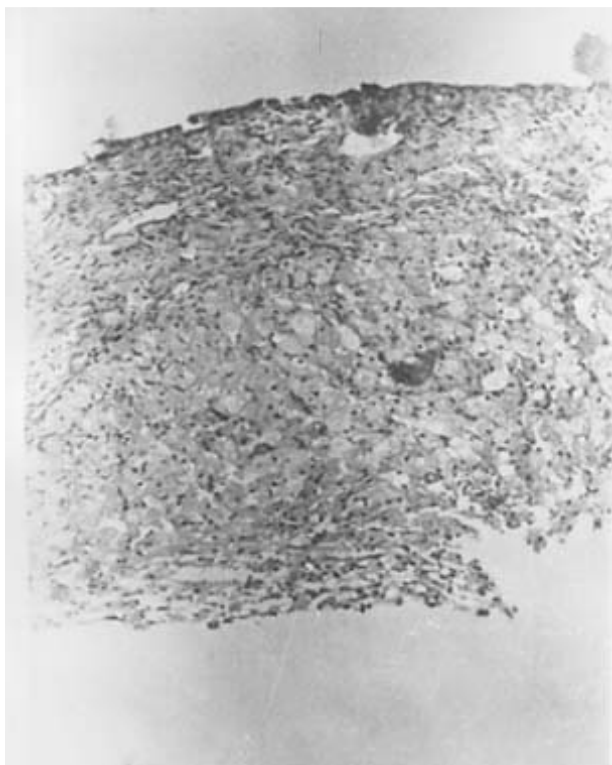
A 75 year old woman, gravida 4, para 3, was referred to our department for unilateral adnexal mass. She had a right modified radical mastectomy for an infiltrating ductal

carcinoma of a tumor 2 cm in size with no regional lymph node metastasis. Estrogen receptors were found to be positive. Tamoxifen (20 mg/day) therapy started after a normal pelvic ultrasonographic examination. A cystic left adnexal mass, 45 mm in diameter was discovered one year later. Pelvic examination revealed a tender, mobile, 4-5 cm. cul de sac mass. Endometrial thickness was reported as 10 mm on transvaginal ultrasonography. No tissue was obtained at endometrial biopsy. Tumor markers including CA 125 were in normal range. At laparotomy, a 5 cm unruptured, regular shape left ovarian cyst was found. Cyst was ruptured during dissection from the adjacent bowel. The patient underwent total abdominal hysterectomy, bilateral oophorectomy, bilateral pelvic and paraaortic lymph node sampling and infracolic omentectomy after frozen section of the left ovarian mass revealed borderline endometrioid tumor.

On histological examination, tumor was composed of atypical adenoid glands with back to back appearance resembling endometrial tissue. Areas of squamous differentiation and ciliary metaplasia and hobnail appearance were also observed (Figure 1). Small foci of endometriosis with macrophages filled with hemosiderin were seen (Fig-



**Figure 1.** Hobnail appearance of tumor cells in back to back glandular architecture of the tumor.



**Figure 2.** Macrophages filled with hemosiderin in a focus of endometriosis.

re 2). There were 2-3 mitosis per 10 high power field. Estrogen receptors were found to be positive. The disease stage was assigned as I C due to surgical rupture of the cyst. The patient is well and free of disease after five years.

## Discussion

Tamoxifen is a unique drug which has surprising effects on the female genital system. Its main effect is anti-estrogenism and for this reason it is widely used in the treatment of breast cancer. It also exerts beneficial effect on bone, on cholesterol preventing fatal myocardial infarction and osteoporosis (6). In postmenopausal patients where estrogenic environment is extremely low, it may exert weak estrogenic stimulus on endometrium. Endometrial hyperplasia, polyps, even cancer are reported with prolonged tamoxifen exposure. Transvaginal ultrasound examination reveals abnormalities in the endometrium and the adjacent myometrium (7).

Tamoxifen is also reported to be an ovulation induction agent and can be a treatment option in clomiphene resistant patients (8). In premenopausal women, especially at the beginning of the treatment, simple functional cysts in the ovaries may appear. These cysts will disappear in the following several months.

A pelvic mass in a postmenopausal woman with a known history of endometriosis may arise the suspicion of malignant transformation of these foci. Demonstration of both cancerous and benign endometrial tissues in the same ovary, demonstration of cancer arising in the tissue and not invading it from another source and presence of endometrial stroma surrounding typical epithelial glands are the histological criteria for a diagnosis of a malignancy arising from endometriosis (9). Destruction of the tissue of origin by the adjacent tumor eliminates the histopathologic evidence of endometriosis in most of the cases (10). Macrophages with hemosiderin provide an additional support. The most frequent malignancy seen to arise in endometriosis is endometrioid adenocarcinomas (11). Sarcomas and mixed mesodermal tumors may be also seen. Endometriosis and endometrioid adenocarcinomas have been reported to contain estrogen and progesterone receptor activity (12).

The signs and symptoms of endometriosis usually regress after the menopause and its low estrogenic environment ensues. Estrogen replacement therapy may aggravate the endometriosis foci, so even in hysterectomized women progestins should be added to the treatment for at least six months. Some authors advocate a short course of progestin, danazol or gonadotropin releasing analog treatment (3-6 months) to suppress the residual endometriosis before the hormonal replacement therapy with estrogen and progesterone (9). There are reports of reactivation of endometriosis in postmenopausal women on tamoxifen (13). Tamoxifen, also increases myometrial volume and uterine size, probably associated reactivation of preexisting adenomyosis (14).

Endometrioid low malignant potential tumors of the ovary can be divided into two groups. Benign endometrioid

tumors with cytologically atypical epithelium are called proliferative endometrioid tumors (PET). If the tumor has more extensive atypical proliferative endometrium with a focus more than 5 mm in diameter is called endometrioid tumors of low malignant potential (ETLMP). It is reported that endometriosis was present in the pelvis, outside the ovary in 43 and 52% of PET and ETLMP respectively and in the same ovary in 100% and 69% respectively (15). Lower percentages were reported in some other articles (16). It is unclear how many neoplasms actually arise in endometriosis. It has been estimated around 5% of endometrioid carcinomas arise from endometriotic cysts (15).

In this presented case, we may just see a coincidence since exposure duration to tamoxifen is relatively short. The possibility of a metastasis from the previous breast cancer should be considered, but histologic architecture is clearly different. Tamoxifen which has weak estrogenic stimulus may act as a cancer promoter in the endometriotic foci in postmenopausal patients. Therefore, ovaries, besides endometrium, should be thoroughly observed during tamoxifen treatment.

#### REFERENCES

1. Sampson JA. Endometrial carcinoma of ovary rising in endometrial tissue in that organ. *Arch Surg* 1925; 10: 1-72.
2. Seoud MAF, Johnson J, Weed JC Jr. Gynecologic tumors in tamoxifen treated women with breast cancer. *Obstet Gynecol* 1993; 82: 165-9.
3. De Muylder X, Neven P, De Somer M, Van Belle Y, Vanderick G, De Muylder E. Endometrial lesions in patients undergoing tamoxifen therapy. *Int J Gynecol Obstet* 1991; 36: 127-30.
4. Cohen I, Altaras MM, Lew S, Tepper R, Beyth Y, Ben-Baruch G. Ovarian endometrioid carcinoma and endometriosis developing in a postmenopausal breast cancer patient during tamoxifen therapy: A case report and review of the literature. *Gynecol Oncol* 1994; 55: 443-7.
5. Bardi M, Arnoldi E, Pizzocchero G, Pezzica E, Mattioni D, Perotti M. Endometrioid carcinoma in pelvic endometriosis in a postmenopausal woman with tamoxifen adjuvant therapy for breast cancer. A case report. *Eur J Gynecol Oncol* 1994; 15: 393-5.
6. Ugwumadu AHN, Carmichael PL, Neven P. Tamoxifen and the female genital tract. *Int J Gynecol Cancer* 1998; 8: 6-15.
7. Bese T, Kosebay D, Demirkiran F, Arvas M, Bese N, Mandel N. Ultrasonographic appearance of endometrium in postmenopausal breast cancer patients receiving tamoxifen. *Eur J Obstet Gynecol Reprod Biol* 1996; 67: 157-162.
8. Gulekli B, Ozaksit G, Turhan NO, Senoz S, Oral H, Gokmen O. Tamoxifen: an alternative approach in clomiphene resistant polycystic ovarian syndrome patients. *J Pak Med Assoc* 1993; 43: 89-90.
9. Heaps JM, Nieberg RK, Berek JS. Malignant neoplasms arising in endometriosis. *Obstet Gynecol* 1990; 75: 1023-8.
10. Fishman A, Demirel D, Laucirica R, Ramzy I, Klima T, Lyzak J, Kaplan AL. Malignant tumors arising in endometriosis: clinical-pathological study and flow cytometry analysis. *Eur J Obstet Gynecol Reprod Biol* 1996; 70: 69-74.
11. Mostoufizadeh M, Scully RE. Malignant tumors arising in endometriosis. *Clin Obstet Gynecol* 1980; 23: 951-63.
12. Gould SF, Shannon JM, Cunha GR. Nuclear estrogen binding sites in human endometriosis. *Fertil Steril* 1983; 39: 520-4.
13. Ford MRW, Turner MJ, Wood C, Soutter WP. Endometriosis developing during tamoxifen therapy. *Am J Obstet Gynecol* 1988; 158: 1119.
14. Cohen I, Beyth Y, Tepper R, Figer A, Shapira J, Cordoba M, et al. Adenomyosis in postmenopausal breast cancer patients treated with tamoxifen: a new entity? *Gynecol Oncol* 1995; 58: 86-91.
15. Snyder RR, Norris HJ, Tavassoli F. Endometrioid proliferative and low malignant potential tumors of the ovary: A clinicopathologic study of 46 cases. *Am J Surg Pathol* 1988; 12: 661-71.
16. Bell DA, Scully RE. Atypical and borderline endometrioid adenofibromas of the ovary: a report of 27 cases. *Am J Surg Pathol* 1985; 9: 205-14.

**Geliş Tarihi:** 30.01.2002

**Yazışma Adresi:** Dr. Tufan BİLGİN  
Uludağ Üniversitesi Tıp Fakültesi  
Kadın Hastalıkları ve Doğum AD,  
16059 BURSA  
tbilgin@uludag.edu.tr