

# A Case of McCune-Albright Syndrome

BİR McCUNE-ALBRIGHT SENDROMU OLGUSU

Yard.Doç.Dr.Yılmaz ŞAHİN\*, Prof.Dr.Selim KURTOĞLU\*\*, Yrd.Doç.Dr.Mustafa KENDİRCİ

Erciyes University Faculty of Medicine, "Department of Obstetrics and Gynecology,  
"Department of Pediatrics, Kayseri-TÜRKİYE

## SUMMARY

We presented a 3-year-old girl with McCune-Albright syndrome. She had the episodes of vaginal bleeding and scattered cutaneous pigmentations. Radiologic investigations revealed no evidence of polyostotic fibrous dysplasia. On pelvic ultrasonographic examination a follicle cyst 33 mm in diameter was seen in the right ovary. The values of estradiol was high, despite low levels of gonadotropins. The findings of hyperfunction of other endocrine glands such as acromegaly, hyperthyroidism, Cushing syndrome and hyperparathyroidism were not observed in our patient. The ovarian cysts was disappeared and the episodes of vaginal bleeding reduced during testosterone treatment.

**Key Words:** McCune-Albright syndrome, Precocious puberty

Anatolian J Gynecol Obst 1993, 3:286-288

McCune-Albright syndrome (MAS) is characterized by the triad of polyostotic fibrous dysplasia, cutaneous pigmentation called cafeau lait spot, and sexual precocity. Recently, additional endocrinologic disorders have been described as part of this syndrome, including hyperthyroidism, acromegaly, hyperprolactinemia, hyperparathyroidism and Cushing syndrome (1-6). The underlying defect this disorder remains unclear. Recent studies have revealed there is autonomous hyperfunction of these affected glands and organs (3-5).

We present our observations on a girl with MAS who was referred to our hospital for evaluation of her precocious puberty.

**Geliş Tarihi:** 30.11.1992

**Kabul Tarihi:** 13.07.1993

**Yazışma Adresi:** Yard.Doç.Dr.Yılmaz ŞAHİN  
Erciyes Üniversitesi Tıp Fakültesi  
Kadın Hastalıkları ve Doğum ABD,  
KAYSERİ

## ÖZET

Üç yaşında vajinal kanama şikayeti ile başvuran bir McCune-Albright sendromu olgusu sunuldu. Ciltte yaygın pigmente alanlar mevcut olup, iskelet grafilerinde fibröz displazi bulguları yoktu. Pelvik ultrasonografide sağ överde 33 mm çapında follikül kisti görüldü. Düşük gona-dotropiniere rağmen östradiol değeri yüksekti. Olgumuzda akromegali, hipertiroidizm, Cushing sendromu ve hiperparatiroidizm gibi diğer endokrin organların hiperfonksiyon bulguları gözlenmedi. Testolactone tedavisi ile ovoidan kistler kayboldu ve vajinal kanamaları azaldı.

**Anahtar Kelimeler:** McCune-Albright sendromu,  
Puberte prekoks

T Klin Jinekoloj Obst 1993, 3:286-288

## CASE REPORT

A 3 year and four months girls was referred because of episodes of vaginal bleeding. On admission, her height was 106 cm and weight 17.5 kg. Her growth and psychomotor development were normal. On physical examination, scattered, macular, flat, light-brown cutaneous pigmentations with irregular borders were seen on the neck, trunk, arms and legs (Figure 1). Hyperpigmented skin lesions were noted at birth.

The thyroid gland was not palpable. Breast development had reached Tanner stage II, but neither axillary nor pubic hair was present and galactorrhea was absent. The external genitalia were normal. Results of neurologic, ophthalmoscopic examinations and visual fields were normal. On pelvic ultrasonographic examination the uterus measured 49x18 mm, endometrial thickness was 6 mm, the right ovarian size was 37x31 mm and a follicle cyst 33 mm in mean diameter seen [ in the right ovary, left ovarian size was 22x13 mm and [

Tablet. Response to gonadotropin-releasing hormone (100 ug)

Time (minutes)	FSH (mIU/ml)	LH (mIU/ml)
0	2	1.54
20	2.13	1.66
40	2.11	1.61
60	2.10	1.60

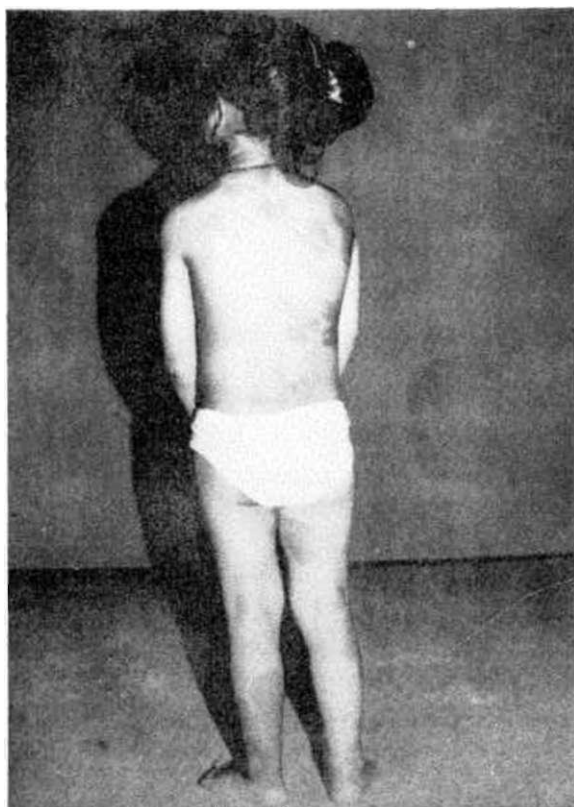


Figure 1. Characteristic cutaneous pigmentations

there were multiple cysts 4 to 5 mm in diameter (Figure 2A).

The bone age was that of a 5-year-old girl. Complete radiologic survey showed no evidence of polyostotic fibrous dysplasia. Computed brain tomography was normal.

Hormones were measured by radioimmunoassay techniques, using commercial test kits. Only estradiol was measured by fluoroimmunoassay technique. Luteinizing hormone-releasing hormone (LH-RH) test was performed by intravenous injection of 100 ug LH-RH. Results of routine blood analyses were normal. Laboratory examinations showed the following data: the serum calcium concentration 9.7 mg/dl, phosphorus 4.2 mg/dl, alkaline phosphatase 222 IU/L, blood glucose 83 mg/dl, GOT 27 U/L, GPT 11 U/L.

The values of serum thyroid hormones were T4 8.8 ug/dl, T3 209.6 ng/dl and TSH 0.60 mg/dl. Serum cortisol was 5.38 ug/dl (at 8:00 AM), and prolactin 9.38 ng/ml. The serum estradiol level was 6.09 nmol/L (normal value at 1-5 year of age: 0.004-0.073 nmol/L), while basal values of luteinizing hormone (LH) and follicle stimulating hormone (FSH) were 1.54 mIU/ml and 2 mIU/ml, respectively. We found very high values of estradiol, despite very low levels of gonadotropins. Furthermore, these low concentrations of FSH and LH did not increase after the administration of 100 jig GnRH (Table 1).

Thyroid and adrenal function were normal initially and at subsequent evaluation. The growth hormone (GH) level was slightly high to be 18.18 ng/ml. Our patient had not clinical evidence of GH excess. Basal GH level of 18.18 ng/ml during a oral glucose loading was partially suppressed to 11.74 ng/ml at one hour in which blood glucose was 116 mg/dl.

The diagnosis of MAS was made on the basis of these hormonal results and on the presence of both cutaneous pigmentation and sexual precocity. Because of testolacton was not supplied, the patient was treated

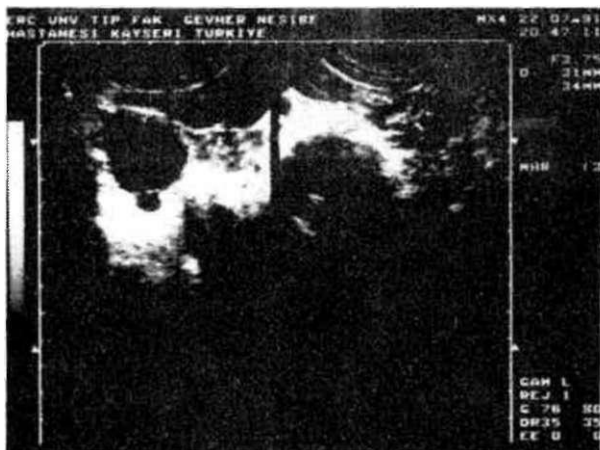


Figure 2A. Right ovarian cyst, endometrium and left ovary

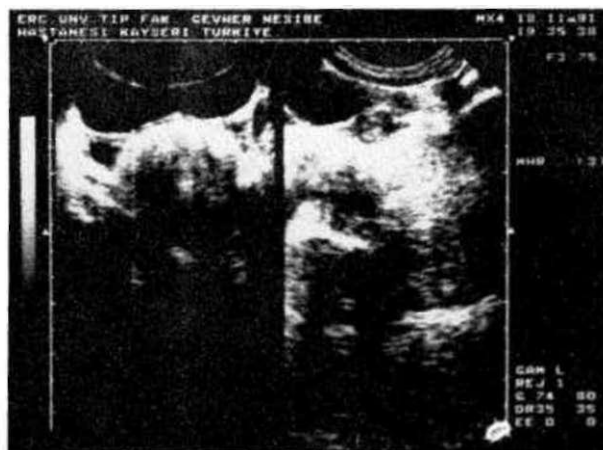


Figure 2B. Bilaterally ovaries at 6 months of treatment

ted with medroxyprogesterone acetat (150 mg/3 weeks, im) for three months, therapy was then changed to the aromatase inhibitor testolactone (40 mg/kg day, orally), which has been effective in treating girls with puberty due to MAS. Evaluations were performed after three and six months. Serum gonadotropin levels remained suppressed throughout treatment. Serum estradiol levels were decreased to 0.05 and 0.017 nmol/ml, respectively. Both ovarian size gradually decreased and unilateral large ovarian cyst disappeared (Figure 2B). She had a single episode of vaginal bleeding during therapy. The Growth hormone levels were 4.91 and 10.70 ng/ml. Skeletal roentgenograms were normal.

## DISCUSSION

The etiology and the pathogenesis of MAS have remained uncertain. Most cases of the syndrome were sporadic and a familial pattern of inheritance has not been reported (3,7). There are two main explanations for the origin of the endocrinopathies: hypothalamic-pituitary abnormalities; autonomous hyperfunction of target glands. Many recent reports have supported the latter hypothesis. These studies indicate that despite absent or low plasma levels of trophic hormones, various endocrine organs may be activated (3,4,7,8). Lee et al (3) proposed an altered regulation of intracellular cAMP as a possible mechanism. This hypothesis can well explain the enigma of the diversity of affected endocrine glands in MAS, all of which are activated by a common cAMP mediated mechanism. However, again this can not explain the cause of both the cutaneous and the osseous lesions.

Precocious puberty is associated with episodic elevations in serum estrogens that often parallel the growth and disappearance of large unilateral ovarian cysts. Baseline and LH-RH stimulated serum LH and FSH levels are frequently suppressed below the normal range, particularly when serum estrogen levels are high. These findings suggest that the precocious puberty is independent of pituitary gonadotropin secretion and probably results from autonomous ovarian activity or hypersensitivity of the ovaries to low gonadotropin levels (3,8). The low basale and LH-RH stimulated levels of FSH and LH in our case were consistent with an autonomous hyperfunction of the ovaries.

This syndrome occurs frequently in fameles. While ovarian cysts may persist during adulthood, most women with the MAS have normal sexual function and fertility. The presence of hyperthyroidism, multinodular adrenal hyperplasia, and Cushing syndrome, gigantism, or hyperparathyroidism in children with this syndrome, suggests that it may be related to the multiple endocrine neoplasia syndrome (4,7).

Treatment modalities for the sexual precocity include medroxyprogesterone and testolactone. Medroxy-

progesterone suppresses gonadal steroidogenesis and appears to modify the recurrence of ovarian cysts. Testolactone blocks estrogen synthesis by inhibiting aromatase, the enzyme that converts androstenedione to estrone and testosterone to estradiol (7). Feullian et al (9) have shown the effectiveness of the aromatase inhibitor testolactone in decreasing estrogen levels, ovarian volume, frequently of menses, growth rate, and the rate of bone maturation in girls with the MAS. Testolactone may reduce the estrogen concentration in or around the ovarian granulosa cell and thus inhibit the formation and enlargement of ovarian cysts. Diminished cyst formation may limit the synthesis of estrogen precursors. Serum gonadotropin levels are usually low and LH-RH agonists have been ineffective in treating gonadotropin agonists may be required if true or central precious puberty develops.

In our patient, serum estradiol levels and both ovarian size gradually decreased, large right ovarian cyst gradually became small and disappeared during six months treatment. Testolactone treatment is being continued. The patient will be evaluated every 3 months.

## REFERENCES

1. Benedict PH. Endocrine features in Albright's syndrome (fibrous dysplasia of bone). *Metabolism* 1962; 11:30.
2. Chung KF, Zadeh JA, Guz A. Acromegaly and hyperprolactinemia in McCune-Albright syndrome, evidence of hypothalamic dysfunction. *Am J Dis Child* 1983; 137:134.
3. Lee PA, Dop CV, Migeon CJ. McCune-Albright syndrome, long-term follow-up. *JAMA* 1986; 256:2980.
4. D'Amleto M, Reda G, Camagna A, Tardella L. McCune-Albright syndrome: Evidence for autonomous multiendocrine hyperfunction. *J Pediatr* 1983; 102:584.
5. Yoshimoto M, Nakayama M, Baba T, Uehara Y, Niikawa N, Ito M, Tsuji Y. A case of neonatal McCune-Albright syndrome with Cushing syndrome and hyperthyroidism. *Acta Pediatr Scand* 1991; 80:984.
6. Feullian PP, Shawker T, Rose SR, Jones J, Jeevanram RK, Nisula BC. Thyroid abnormalities in the McCune-Albright syndrome: ultrasonography and hormonal studies. *J Clin Endocrinol Metab* 1990; 71:1596.
7. Kaplan SL, Grumbach MM. Pathophysiology and treatment of sexual precocity. *J Clin Endocrinol Metab* 1990; 71:785.
8. Foster CM, Ross JL, Shawker T, Pescovitz OH, Lorioaux DL, Cutler CB, Comité F. Absence of pubertal gonadotropin secretion in girls with McCune-Albright syndrome. *J Clin Endocrinol Metab* 1984; 58:1161.
9. Feullian PP, Foster CM, Pescovitz OH, Hench KD, Shawker T, Dwyer A, et al. Treatment of precocious puberty in the McCune-Albright syndrome with the aromatase inhibitor testolactone. *N Engl J Med* 1986; 315:1115.