

Reed's Syndrome: Case Report

Reed Sendromu

Münire ERMAN AKAR, MD,^a
Nurten KAYACAN, MD,^b
Funda ŞATIR, MD,^a
İrem Hicran ÖZBUDAK, MD^c

Departments of
^aObstetrics and Gynecology,
^bAnesthesiology and Reanimation,
^cPatology,
Akdeniz University Faculty of Medicine,
Antalya

Geliş Tarihi/Received: 27.02.2009
Kabul Tarihi/Accepted: 16.06.2009

Yazışma Adresi/Correspondence:
Münire ERMAN AKAR, MD
Akdeniz University Faculty of Medicine,
Department of Obstetrics and
Gynecology, Antalya,
TÜRKİYE/TURKEY
mnirea@yahoo.com

ABSTRACT A 42-year-old woman with a history of subtotal hysterectomy for myoma uteri and painful dermal lesions on left arm and leg presented for chronic pelvic pain to our clinic. On gynecological examination, cervix was visualised as nullipar without any particular lesion. Pelvic ultrasound showed multiple myomatous lesions on the cervical surface. She had the diagnosis of Reed's syndrome confirmed by genetic and histopathologic examination of the uteri and dermal lesions showing a proliferation of smooth muscle fascicles. The patients pelvic pain did not resolve with analgesics. Cervical resection was performed. Periodic gynecological follow up is essential in patients with Reed's syndrome even though hysterectomy is performed.

Key Words: Leiomyoma; hysterectomy; pelvic pain

ÖZET Miyoma uteri nedeniyle subtotal histerektomi ve sol kol ile bacağına ağrılı dermal lezyon hikâyesi olan 42 yaşındaki kadın hasta, kronik pelvik ağrı ile kliniğimize başvurdu. Jinekolojik muayenede nullipar serviksine ait bir lezyon izlenmedi. Pelvik ultrasonunda serviks yüzeyinde multipl miyom lezyonları ile uyumlu görüntü izlendi. Hastanın hikâyesinde uterusun ve dermal lezyonların genetik ve histopatolojik değerlendirilmesi sonrası kanıtlanmış düz kas liflerinin proliferasyonu ile karakterize Reed sendromu tanısı vardı. Analjeziklerle pelvik ağrısı gerilemeyen hastada servikal rezeksiyon yapıldı. Histerektomi uygulanmış olsa bile Reed sendromu hikâyesi olan hastaların periyodik jinekolojik takipten geçmeleri gereklidir.

Anahtar Kelimeler: Miyom; histerektomi; pelvik ağrı

Türkiye Klinikleri J Gynecol Obst 2009;19(6):361-4

A 42-year-old woman presented to the Akdeniz University Gynecology Clinic for chronic pelvic pain post subtotal hysterectomy. She had a history of multiple myomas and painful dermal lesions on left tibia. She notes that she first noticed the dermal lesions in 1991 around left forearm, which were painful even with touch. She had a history of myomectomies in 1987 and 1989 and subtotal hysterectomy in 1995. Dermal lesions progressively spread to the whole left leg and arm during this time period. She states that her brother has papillary renal cell carcinoma and her aunt on her father's side had hysterectomy in her late 20's due to multiple myomas. We found no further specific information upon investigation of the health status of her other relatives.

Our patient gave informed consent for the publication of her clinical findings.

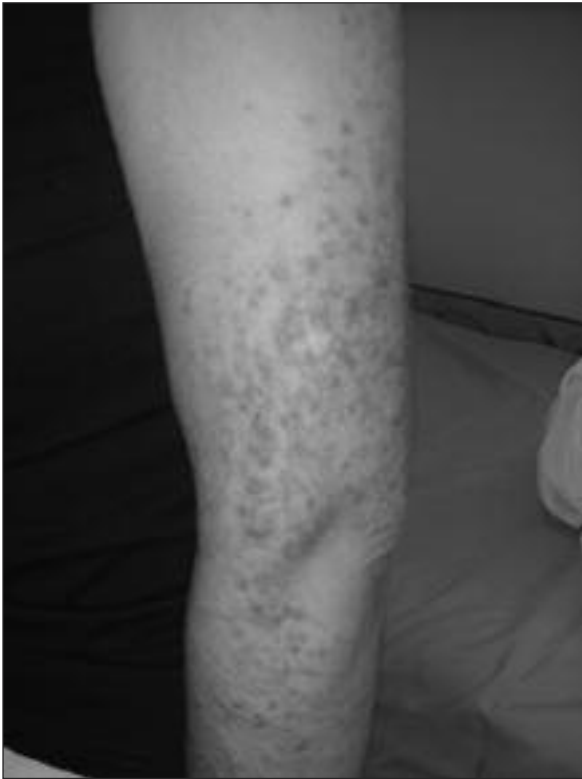

FIGURE 1: Left arm.

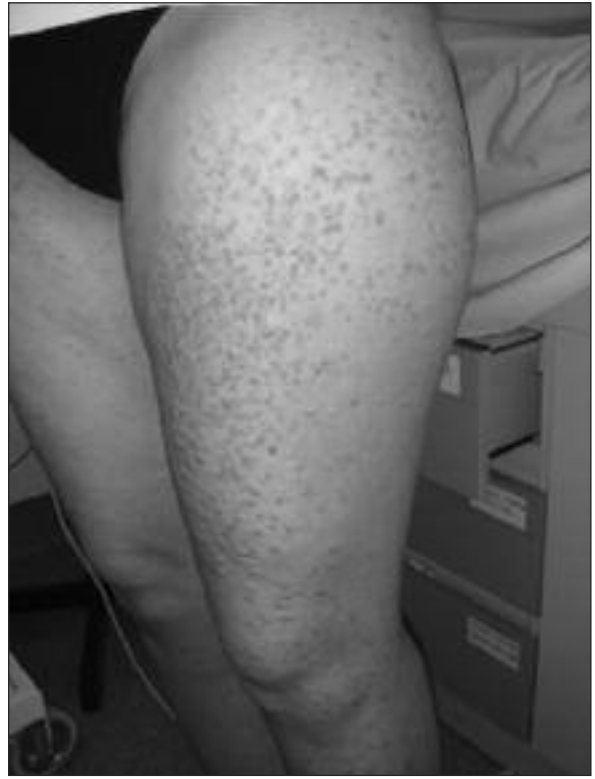


FIGURE 2: Left thigh.

On the lateral and anterior aspects of the left arm and leg in a dermatomal distribution were several firm, smooth, pink-to-brown papules (Figures 1, 2,3). Pathologic examination showed interlacing bundles and whorls of spindle smooth muscle cells with cigar shaped nuclei with a sparse lymphocytic infiltrate and variable amounts of collagen bundles in the dermis and cervical stump (Figure 4, 5). Pel-

vic ultrasound showed multiple myomatous lesions on the remnant cervical surface. Our patients pain did not resolve with oral nitroglycerin and topical anesthetics.

In her routine preoperative evaluation, there was no pathologic finding that would be a contraindication for general anesthesia. Standard general anesthesia was induced with intravenous anesthetics

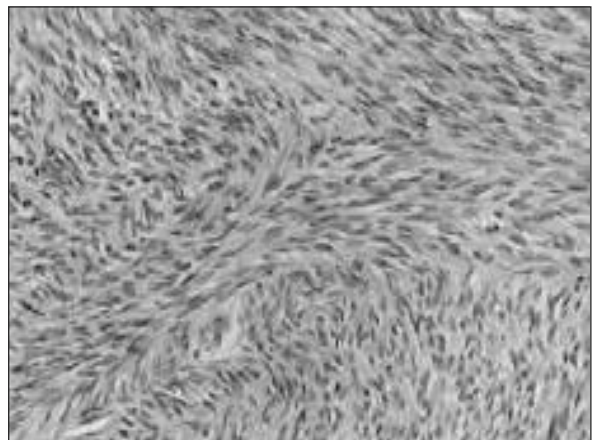
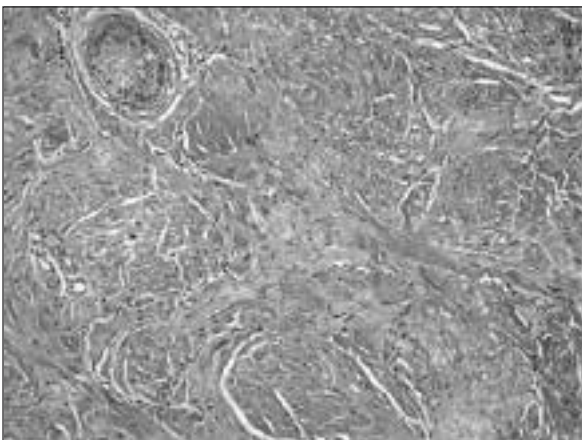


FIGURE 3 and 4: The sections of biopsy specimen showed interlacing bundles and whorls of spindle smooth muscle cells with cigar shaped nuclei with a sparse lymphocytic infiltrate and variable amounts of collagen bundles in the dermis H&E (A) x100, cervical stump H&E (B) x100.

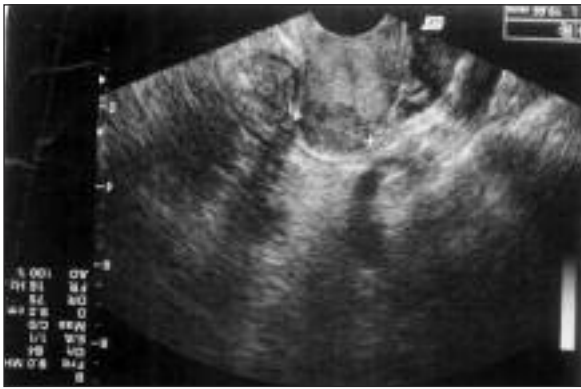

FIGURE 5: Ultrasound of the remnant cervix.

and maintenance was performed with inhalation agents. Surgical excision of the cervical stump has been performed for the myomatous lesions.

CLINICAL FINDINGS

Histopathologic examination of the uteri and dermal lesions showed a proliferation of smooth muscle fascicles consistent with the diagnosis of cutaneous leiomyomas. A missense novel mutation in the fumarate hydratase gene was demonstrated by genetic sequencing as stated in her previous reports.

Abdominal and pelvic computerized tomography scans in March 2008 demonstrated normal appearing kidneys and ovaries.

COMMENT

Cutaneous leiomyomas are rare benign tumors originating from smooth muscle cells.¹ They usually appear as multiple, in size from a few millimeters to 1.1 cm brown-yellowish, reddish, bluish or skin-colored papules.^{2,3} They are usually located on the trunk, thighs, neck and face occurring multiple and disseminated or in a segmental pattern in about 80% of cases.

Multiple cutaneous and uterine leiomyoma syndrome -also known as Reed's syndrome- is an autosomal dominant disease with incomplete pe-

netrance.⁴ The gene for Reed's syndrome was mapped to chromosome 1q42.3-43 in 2001.⁵ The fumarate hydratase (FH) gene has been identified as the responsible gene in 2002.⁶ The FH gene is thought to act as tumor suppressor gene.⁵⁻⁸

The syndrome may comprise two different types. Type 1 shows lesions only in a segmental area, whereas type 2 which is more frequent shows more lesions in various areas.⁷

Since, an association between Reed's syndrome and papillary renal-cell carcinoma has been found, all patients with a family history of cutaneous leiomyomas and uterine fibroids should be questioned regarding renal function and symptoms of renal disease.^{6,7,9} The US National Cancer Institute recommends screening of all patients with leiomyomatosis with a computed tomographic scan to detect early renal cell carcinoma.⁷

Cutaneous leiomyomas do not resolve spontaneously causing enormous pain. Therefore surgical excision appear to be the best treatment for solitary lesions.

The cause of pain is unknown and treatment is often difficult. It is noted that it might be due to pressure on the cutaneous nerve or might originate from the contraction of smooth muscle fibers arising from the tumor itself.^{10,11} It has been reported that symptomatic therapy of pain by the blockage of smooth muscle contraction with oral nitroglycerol, calcium channel blockers, adrenoreceptor blockers, analgesics, antidepressants, antiepileptics or a combination of these drugs might be helpful as presented in our case.^{1,12-14}

As a conclusion, Reeds syndrome is a rare nontreatable autosomal dominant disorder which requires periodic gynecological and urinary system monitoring even though hysterectomy is performed.

REFERENCES

- Garman ME, Blumberg MA, Ernst R, Raimer SS. Familial leiomyomatosis: a review and discussion of pathogenesis. *Dermatology* 2003;207(2):210-3.
- Jolliffe DS. Multiple cutaneous leiomyomata. *Clin Exp Dermatol* 1978;3(1):89-92.
- Bozdağ KE, Aydın O, Yetimalar H, Aydın Ç. [Reed's syndrome: Case report]. *Turkiye Klinikleri J Dermatol* 2007;17(1):60-2.
- Reed WB, Walker R, Horowitz R. Cutaneous leiomyomata with uterine leiomyomata. *Acta Derm Venereol* 1973;53(5):409-16.
- Alam NA, Bevan S, Churchman M, Barclay E, Barker K, Jaeger EE, et al. Localization of a gene (MCUL1) for multiple cutaneous leiomyomata and uterine fibroids to chromosome 1q42.3-q43. *Am J Hum Genet* 2001;68(5):1264-9.
- Tomlinson IP, Alam NA, Rowan AJ, Barclay E, Jaeger EE, Kelsell D, et al.; Multiple Leiomyoma Consortium. Germline mutations in FH predispose to dominantly inherited uterine fibroids, skin leiomyomata and papillary renal cell cancer. *Nat Genet* 2002;30(4):406-10.
- Kiuru M, Lehtonen R, Arola J, Salovaara R, Järvinen H, Aittomäki K, et al. Few FH mutations in sporadic counterparts of tumor types observed in hereditary leiomyomatosis and renal cell cancer families. *Cancer Res* 2002;62(16):4554-7.
- Martinez-Mir A, Glaser B, Chuang GS, Horev L, Waldman A, Engler DE, et al. Germline fumarate hydratase mutations in families with multiple cutaneous and uterine leiomyomata. *J Invest Dermatol* 2003;121(4):741-4.
- Launonen V, Vierimaa O, Kiuru M, Isola J, Roth S, Pukkala E, et al. Inherited susceptibility to uterine leiomyomas and renal cell cancer. *Proc Natl Acad Sci U S A* 2001;98(6):3387-92.
- Toro JR, Nickerson ML, Wei MH, Warren MB, Glenn GM, Turner ML, et al. Mutations in the fumarate hydratase gene cause hereditary leiomyomatosis and renal cell cancer in families in North America. *Am J Hum Genet* 2003;73(1):95-106.
- Stewart EA. Uterine fibroids. *Lancet* 2001;357(9252):293-8.
- Holst VA, Junkins-Hopkins JM, Elenitsas R. Cutaneous smooth muscle neoplasms: clinical features, histologic findings, and treatment options. *J Am Acad Dermatol* 2002;46(4):477-90.
- Ritzmann S, Hanneken S, Neumann NJ, Ruzicka T, Kruse R. Type 2 segmental manifestation of cutaneous leiomyomatosis in four unrelated women with additional uterine leiomyomas (Reed's Syndrome). *Dermatology* 2006;212(1):84-7.
- Kim G. Multiple cutaneous and uterine leiomyomatosis (Reed's syndrome). *Dermatol Online J* 2005;11(4):21.