

Applications of Office Mini-Hysteroscopy: Rationales and Advantages

Ofis Mini Histeroskopik Uygulamalar: Gerekçeleri ve Avantajları

Cemil KAYA, MD,^a
Recai PABUÇCU, MD^a

^aDepartment of Obstetrics and
Gynecology,
Ufuk University School of Medicine,
ANKARA

Geliş Tarihi/Received: 10.04.2007
Kabul Tarihi/Accepted: 22.05.2007

Yazışma Adresi/Correspondence:
Cemil KAYA, MD,
Ufuk University School of Medicine,
Department of Obstetrics and
Gynecology, ANKARA
kayacemil000@yahoo.com

ABSTRACT Hysteroscopy can be regarded as the gold standart for the evaluation of the uterine cavity and subsequent detection of intrauterine pathology. The technological advances made in recent years- for example the introduction of small-diameter hysteroscopes- have brought about remarkable progresses in the field of office hysteroscopy, even though large-diameter instruments are still widely used. It is safe and simple procedure and, if it can be carried out successfully in an outpatient setting without anesthesia, it would be an attractive practice. In recent years, a new technique based on the employment of mini hysteroscopes and vaginoscopic approach has been developed in order to improve feasibility and reduce pain and side effects. Office mini hysteroscopy has become the modality of choice for the evaluation of the endometrial cavity, including assessment of abnormal uterine bleeding, endometrial polyps, infertility and suspected intrauterine pathology.

Key Words: Hysteroscopy, infertility

ÖZET Histeroskopi uterin kavitenin değerlendirilmesi ve intrauterin patolojilerin saptanmasında "altın standart" bir teknik olarak kabul edilmektedir. Büyük boyutlu cihazların hala yaygın olarak kullanılmasına rağmen, teknolojik gelişmeler ile birlikte küçük çaplı histeroskoplara kullanıma girmesi, ofis histeroskopi alanında kayda değer ilerlemeler sağlamıştır. Güvenli ve basit bir işlem olup, anestezi gerektirmeden poliklinik uygulamalarında bile yapılabilmesi cazip hale getirmektedir. Ofis mini histeroskopinin kullanıma girmesi ile vaginoskopik yaklaşım geliştirilmiş, ağrı ve prosedürlere bağlı yan etkiler en aza indirilmiştir. Ofis mini histeroskopi anormal uterin kanamalar, endometrial polip, infertilite ve şüpheli intrauterin patolojilerde ilk tercihtir.

Anahtar Kelimeler: Histeroskopi, infertilite

Türkiye Klinikleri J Gynecol Obst 2008, 18:41-51

Hysteroscopy can be regarded as the gold standart for the evaluation of the uterine cavity and subsequent detection of intrauterine pathology. Endoscopic techniques for diagnosis and treatment of several diseases have gained importance in medicine, especially over recent years.¹ The advantage lies in the direct optical judgement of body cavities and frequently the possibility of surgical treatment during the same procedure. For the patient the endoscopic access is less traumatic than laparotomy, resulting in reduced postoperative pain and shorter hospital stay.

In the last decade, hysteroscopy has become the modality of choice for the evaluation of the endometrial cavity, including assessment of abnormal

uterine bleeding, infertility, recurrent pregnancy loss, and suspected intrauterine pathology. Operative hysteroscopy is a good example of minimal invasive surgery. Nevertheless the operative procedures call for a complex instrumentation setup, special training of the surgeon is required and knowledge of possible complications and their appropriate management are mandatory.² The technique of diagnostic hysteroscopy on the contrary has not yet been accepted generally as an ambulatory, well-tolerated office procedures, giving the gynaecologist reliable and important information regarding the cervical and intrauterine situation.

HISTORY

Endoscopic techniques for diagnosis and treatment of several diseases have gained importance in medicine, especially over recent years. During the early history of hysteroscopy (1805-1966) the organ-specific and technical problems had not been resolved.³ It was only in 1967 that Fritz Menken made a first step towards an atraumatic ambulatory approach using a pediatric cystoscope to perform a hysteroscopy. The distension of the uterine cavity was done with a high colloidal liquid, called luviscol, and an elastic cone was used to seal the cervical channel and prevent leakage of the liquid.⁴ In the 1970s and 1980s, however, hysteroscopy had to face some rather unscientific approaches such as hysteroscopic tubal sterilization and the micro-colposcopy. In the 1970s Lindemann et al.⁵ published their experimental findings regarding the influence of CO₂ gas during hysteroscopy. Here, for the first time, not only the advantages of this new method, but also the possible dangers and complications of gas insufflation were analysed. Cornier⁶ and Lin et al.⁷ tried to find a new way by using a flexible hysteroscope, a small flexible bored instrument with a channel for instrument application, through which for example laser wires could be applied. The use of the Nd-YAG laser for destruction of the endometrium in patients with idiopathic uterine bleeding disorders, was certainly the start for renewed interest in this method by the public, mainly because the transcervical approach offered a safe and valid alternative with extremely

high patient compliance in comparison to the transabdominal approaches.⁸ At the end of the 1980s CO₂ was replaced by watery or low viscosity solutions as a distention medium and the introduction of a continuous flow system enabled the surgeon to restore view in nearly every situation. The introduction of the atraumatic technique, the new mini hysteroscopes and the technically superior video documentation now raises the chances that hysteroscopy, both diagnostic and operative, may become established as a routine procedure by every gynaecologist.

THE ATRAUMATIC INSERTION TECHNIQUE (VAGINOSCOPIC APPROACHES)

The technique of diagnostic hysteroscopy, has changed only in the last years into a simple, safe and very efficient method to investigate intrauterine pathology. However, in general, diagnostic hysteroscopy still is considered an invasive and painful technique, so despite its great value it is still underused. In recent years, a new technique based on the employment of mini hysteroscopes and vaginoscopic approach has been developed in order to improve feasibility and reduce pain and side effects. To appreciate fully the safety, ease, and comfort of office hysteroscopy, one should be very familiar with the technique of performing office hysteroscopy. The modern advances in endoscopy have particularly benefited office hysteroscopy. Standard hysteroscopy, as described more than two decades ago, delivers gas or fluid through a 5 mm outer diameter (OD) sheath with a 4 mm telescope. A speculum enables the hysteroscopy to grasp the cervix with a tenaculum to steady uterus. Pain and vasovagal reactions may be triggered by the speculum, the tenaculum, cervical dilatation, and distention of the cavity. Light headedness and nausea have been reported in up to 13% of hysteroscopies in the general population with a higher incidence in women at risk for cervical stenosis such as postmenopausal and nulliparous women. Vaginoscopic approach consisting of insertion of the hysteroscope into vagina and the cervical canal under visual guidance avoids the use of speculum and tenacu-

TABLE 1: Technique of atraumatic diagnostic hysteroscopy.

No cervix dilatation
No blind insertion of instruments into the uterine cavity
No use of portio tenaculum
Atraumatic and sight-controlled insertion of the hysteroscope
Use non-irritating distension medium (ionic watery solution)
No anaesthesia or analgesia necessary

lum and improves patient acceptance. The following are not necessary hysteroscopy:

Tenaculum. While patients are not anaesthetized the portio has to be grasped only in rare cases.

Hegar dilator.

Local anaesthesia. There is no evidence whatsoever that local anaesthesia improves patient satisfaction and compliance during the procedure. On the contrary the application of local anaesthesia increases the operating time and the risks associated with the whole procedure (Table 1).

RATIONALES AND ADVANTAGES FOR THE USE OF OFFICE HYSTEROSCOPY

In conventional hysteroscopy, the speculum is used to expose the cervix and the anterior lip is grasped with forceps to permit the intracervical introduction of the hysteroscope. The conventional approach, which begins by insertion of a speculum and exposure of the cervix, is generally well accepted by patients but can be made difficult or painful by post-menopausal atrophy, vaginal malformation or vaginismus. It is rarely tolerated by virgins. Grasping the cervix with forceps is intended to exert traction to correct uterine anteversion but may also cause discomfort or pain. Bettocchi⁹ recently described a transvaginal “no-touch” approach, with no instruments to expose or hold the cervix, which is reportedly tolerated better. Several teams that have adopted this procedure report satisfactory results.^{10,11} There are a significant number of approaches and techniques for the performance to office hysteroscopy listed in the literature, according to preferences of each operator. The procedure is performed, when possible, in the proliferative phase of menstrual cycles, but a small amount of bleeding

is consequential because, when saline solution used as the distension medium, even a moderate amount of blood in the uterus irrigated away, allowing for good visualization. No premedication is required, unless the patient is extremely anxious. With therapeutic interventions such as the use of suction curettage or of biopsy or grasping forceps, it may be advisable to add injections of atropine (0.2 mg) or ketoralac (30 mg) 30 minutes before the actual procedure to reduce the risk of significant pain or vasovagal reaction. Physiological saline solution or Ringer’s lactate solution, in 250 or 500 mL bags is preferred because either one is isotonic and isoosmolar, meaning that there need to no concern about systemic absorption at those volumes (Table 2,3).

A recent randomized study comparing these two techniques could not demonstrate the superiority of the transvaginal approach, probably because of insufficient statistical power.¹² Reduced pain and greater safety of hysteroscopy performed with minihysteroscopes has been confirmed by results

TABLE 2: Patient compliance in 4204 conventional office hysteroscopies (1982-1989).

Patient compliance	n	%
No or minor discomfort	3332	79.3
Discomfort	112	2.7
Major discomfort	82	1.9
Examination impossible	217	5.2
No documentation	461	10.9
Total	4204	100

TABLE 3: Pain, incidence of side effects, and success rate in prospective randomized studies comparing hysteroscopy performed with conventional instruments and mini hysteroscopes.

Patients (n)	Pain		Side effects		Success rate(%)	
	H	MiniH	H	MiniH	H	MiniH
480	3.4 AS	1.8 AS	3.3	1.3	44.0	87.0
371	14.7 %*	8.7%*	H	MiniH†	77.0	81.6
200	4.6 AS	2.3 AS	0	5	95.3	98.1
100	1.5 AS	0.8 AS	12.0	2.2	72.5	

AS= arbitrary scale; H= standart 5-mm hysteroscope; MiniH=3.5 mm minihysteroscope. *Percentage of women who reported intolerable pain; † Data not reported in the paper; authors reported that nausea and vomiting were more frequent in H group with respect to MiniH group, although not significantly. Table 1 from Cicinelli E (2005).¹³

of other studies.¹³ In Table 1, data on pain and side effects reported in prospective randomized studies comparing hysteroscopy performed with 5 mm conventional instruments and 3.5 mm minihysteroscopes are displayed. A multicenter study demonstrated that mini hysteroscopy compared with conventional hysteroscopy was associated with significantly less pain ($p < 0.0001$) and that, although not significantly, the incidence of vasovagal reactions was lower (4/240, 1.6% vs 8/240, 3.3%, $p = \text{NS}$). The authors reported that this unexpected results could be related th the fact that endometrial biopsies were performed in about 40% of patients with a 4 mm Novak's curette and that they used CO₂ instead of saline as distention medium.^{12,13}

A recent retrospective study informed a very high success rate and a vey low complication rate during diagnostic hysteroscopy performed with a 2.3 mm pediatric cystoscope. The authors reported that hysteroscopy was successfully completed in 1298 patients (97.3%). Dilatation of the cervix was required in six women (0.46%), and local anesthesia was needed in only two women (0.15%). One uterine perforation was recorded, and eight women developed vasovagal reflex or severe abdominal cramps. Postprocedural oral analgesia was needed in 108 (8.0%) of the women.¹⁴

Therefore, in order to employ hysteroscopes as thin as possible, three options can be undertaken:

Employment of minitelescopes;

Use of single-flow sheath instead of continuous-flow sheath;

Use first of a simple diagnostic sheath instead of the larger operative sheath required for guided endometrial biopsy.

The employment of mini telescopes may raise concern about their quality of vision and resistance compared with standart 4 mm telescopes. However, thanks to recent technological improvements, new lens-based mini telescopes have a very high visual quality. New, narrow-diameter lens-based telescopes range in diameter from 2 to 2.9 mm (Figure 1, Mini hysteroscope, diameter 2 mm). The brightness, angle of view, and field of view are



FIGURE 1: Mini hysteroscope, diameter 2 mm.



FIGURE 2: Small hysteroscope, diameter 2.9 mm.

comparable to or better than that of standart 4 mm telescopes (Table 2),¹⁵ (Figure 2, Small hysteroscope, diameter 2.9 mm). It is noteworthy to understand that a wider angle of view allows better visualization of the cavity with less manipulation of the instrument. Moreover, a wider visual field offers brighter visualization with better image bundles as well. The improvement in fiberoptic technology has allowed the realization of both rigid and flexible small-diameter hysteroscopes. Small-diameter fiberoptic hysteroscopes are more damage resistant compared with lens-based instruments and have the additional advantage that in the same diameter they allow the introduction of larger operative instruments with greater surgical potentiality. However, even the great improvements in fiberoptic technology, it cannot match image quality of a rod-lens-based telescope system. Another disadvantage of fiberoptic technology is the standart 0 degree angle of vision (Figure 3, Continuous-flow resektoscope). Cavity exploration is better with a 30-degree endoscope. Moreover, the flat (not fluted) tip of the introduction through a stenotic cervix may be more difficult than with a 30-degree rigid hysteroscope.¹³



FIGURE 3: Continuous-flow resektoscope.

Until now in all published studies, the vaginoscopic approach has been performed with different-sized standart rigid hysteroscopes. In the recent years, a semi-rigid 3.5 mm fiber-optic mini-hysteroscope has been developed. The advantages of the semi-rigid fiberscopes are the smaller total diameter, the superior brightness and the instrument life-time. The advantage of the rigid optical system are the larger field and angle of view and superior resolution. Salin infusion eliminates the use of CO₂, which can cause abrupt distension of the uterine cavity, back and shoulder pain, and peritoneal irritation-all factors that can trigger vasovagal reactions. A pressure cuff installed between 80-150 mmHg delivers the necessary pressure for cavity distension. Physiological watery solutions have the advantage of being less irritating and painful than CO₂ gas. In contrast to CO₂ gas, delicate structures will not collapse in a watery distension medium, resulting in a more accurate diagnosis of subtle lesions. For optimal visualization and image quality a high performance light source is mandatory.

Campo et al.¹⁵ demonstrated the advantages of mini-hysteroscopy and the importance of patient parity and surgeon experience, suggesting that mini-hysteroscopy should always be used, especially for inexperienced surgeons and when difficult access to the uterine cavity is anticipated.

The atraumatic insertion technique can easily be performed in virgins without placing a speculum and without destroying the hymen. The distension medium is warmed to 37°C and progressively the vagina, cervix, cervical channel and uterine cavity are explored.

Contraindications to perform an office mini-hysteroscopy are symptomatic vaginal, uterine, or adnexial infections, menstrual bleeding, an evolutive pregnancy or severe uterine hemorrhage (Table 4, 5).

APPLICATIONS OF DIAGNOSTIC OFFICE MINI-HYSTEROSCOPY

Diagnostic office mini-hysteroscopy aims to differentiate normal cervical and intrauterine findings from abnormal ones. The information should be gathered in a simple, safe and efficient way with a

TABLE 4: Complications in 4204 conventional office hysteroscopies (1982-1989).

Complications	n	%
Fundal perforation	2	
Prolonged vagal reaction	4	
Epileptic insults	1	
Infections	0	
Total	7	0.16

TABLE 5: Failures in 530 consecutive ambulatory mini-hysteroscopies in infertile patients (1993-1995)

Failures	n	%
Pain	4	0.75
Internal cervical stenosis	3	0.57
Insufficient visualization	5	0.94
Complications	0	0.94
Total	12/530	2.26

Table 2, 3, 4, 5 from Campo R, et al.(1999).¹⁵

high patient compliance. Unnecessary hospital admissions can thus be avoided and in case of abnormal findings the patients can be correctly informed prior to further procedures or treatments (Table 3,4,5).¹⁵

ABNORMAL UTERINE BLEEDING

Uterine bleeding disorders are the most frequent indication for diagnostic hysteroscopy in a standart population. Using fractioned curettage, which currently is often conducted as the sole measure, intra-uterine polyps, myomas or early stages of endometrial carcinomas might escape diagnosis.¹⁵ Abnormal uterine bleeding (AUB) can be defined as any bleeding whose duration, frequency, and amount are excessive for a certain patient. It can be organic or functional.¹⁶ Abnormal uterine bleeding makes the patient uncomfortable due to the limitations that it poses, such as the increased need to use tampons and the concern about the cause of bleeding and the possibility of a malignant disease. In addition to the disturbance caused to women, AUB is viewed as a sign for possible uterine diseases, some of which are pre-malignant or malignant, confirming its relevance in scientific research.^{17,18} Vaginal bleeding is also the most frequent sign of malignant uterine disease, particularly in the post-menopausal women. Hysteroscopy is believed to be

the “gold standart” for diagnosis of abnormal uterine bleeding and misses less than 0.5% of serious disease such as endometrial cancer. Regarding ultrasound scanning for evaluation of abnormal uterine bleeding, two important studies compared the diagnostic accuracy of vaginal-probe ultrasonography against office hysteroscopy and SIS (saline infusion sonography) against office hysteroscopy.^{19,20} Both studies found that ultrasonography and hysteroscopy were effective for detecting intrauterine disease such as polyp, submucous myomata, and endometrial hyperplasia, but there were fewer false-positive and false-negative results with hysteroscopy. The Widrich et al.¹⁹ showed that patients had more discomfort with office hysteroscopy than with SIS, but they did not use any local anesthetic with either procedure.

Hysteroscopy with directed biopsy presents advantages over uterine dilatation and curettage (D&C) in the diagnosis of intracavitary diseases, particularly focal ones. Therefore, it is the chosen method for patients with AUB who have not achieved an accurate diagnosis by D&C.²⁰⁻²² Hysteroscopy is regarded as “the gold standart” for diagnosing endometrial diseases, especially when it is associated with directed biopsy performed under the hysteroscopic view.²³

Hysteroscopy does not easily lead to suspicion of endometrial hyperplasia even in patients with bleeding or in those who are postmenopausal, because such disorders was identified by hysteroscopic view in only 90.4% of patients with a previous diagnosis for endometrial hyperplasia.²¹ Deckart et al.²⁴ in a multicenter study comprising 1286 patients with pre- and postmenopausal bleeding, found 2.3% of patients had endometrial cancer, while Crescini et al.¹⁷ found cancer in 2.8% of 503 hysteroscopic examinations. Valli et al.²⁵ obtained an endometrial cancer diagnosis in 3.2% of the patients with AUB. Lasmar et al.²⁶ found that the incidence of the uterine cavity malignancy was of 2.6% in 4054 examinations, which is in accordance with the literature. These data led us to credit hysteroscopic view as an optimum diagnostic method in the study of malignant or pre-malignant diseases with excellent sensitivity.

Hysteroscopic view presents excellent specificity for endometrial cancer (99.5%) and good specificity for hyperplasia (89.1%). It shows good sensitivity for endometrial cancer (80.0%); however, it has low sensitivity for endometrial hyperplasia (56.3%). Despite the good validity of hysteroscopic view, biopsy is essential for endometrial hyperplasia and cancer diagnosis. A review of 26 346 women who underwent diagnostic hysteroscopy calculated that pretest probability of endometrial cancer was 3.9% (95% CI 3.7%-4.2%); a positive hysteroscopy results (pooled likelihood ratio 60.9; 95% CI 51.2-72.5) increased the probability of cancer to 71.8% (95%CI 67.0%-76.6%), whereas a negative hysteroscopy results (pooled likelihood ratio 0.15;95% CI 0.13-0.18) reduced the probability of cancer to 0.6% (95% CI 0.5%-0.8%). However, the overall accuracy for the diagnosis of endometrial disease was modest compared with that of cancer, and the results were heterogeneous. A retrospective study²⁷ on 1500 women undergoing hysteroscopy due to abnormal uterine bleeding matched the hysteroscopy imaging with results of endometrial biopsies. Hysteroscopy showed sensitivity, specificity, negative predictive value (NPV), and positive predictive value (PPV) of 94.2%, 88.8%, 96.3%, and 83.1%, respectively, in predicting normal or abnormal histopathology of endometrium. Highest accuracy was in diagnosing endometrial polyps, with sensitivity, specificity, NPV, and PPV of 95.3%, 95.4%, 98.9%, and 81.7%, respectively; the worst results was in estimating hyperplasia, with respective figures of 70%, 91.6%, 94.3%, and 60.6%. All failures of hysteroscopic assessment resulted from poor visualization of the uterine cavity or from underestimation or overestimation of irregularly shaped endometrium. The authors concluded that hysteroscopy is accurate in distinguishing between normal and abnormal endometrium and that endometrial sampling is recommended in all hysteroscopies showing unevenly shaped and thick endometrial mucosa and an anatomically distorted uterine cavity, and when endometrial visualization is less than optimal.²⁸

Lasmar et al.²⁶ reported that in their experience of 10 500 hysteroscopies, endometrial hyperpla-

sia was diagnosed in less than 10% of cases; whereas in 90% of cases, conditions in which diagnostic hysteroscopy is recognized to have high diagnostic accuracy were found (e.g., normal endometrium, atrophy, myomas, uterine malformations, adhesions, polyps, cancer, etc).

■ ENDOMETRIAL POLYPS

Endometrial polyps are localized overgrowth of the endometrial tissue that is composed of a variable amount of glands, stroma, and blood vessels that is covered by epithelium. They can be seen by hysteroscopy in women with abnormal uterine bleeding, but even incidentally diagnosed in asymptomatic women during a transvaginal sonography that is performed for other indications (Figure 4,5).

The prevalence in women with abnormal uterine bleeding varies widely in the literature, ranging around 10% to 30% in relation to hormonal status. It has been calculated that, as a consistent proportion of endometrial polyps does not produce symptoms, the prevalence in the general female population can be estimated at approximately 24% to 25%. The clinician has to face the issue of how to treat endometrial polyps because they are being

diagnosed in growing numbers even in asymptomatic women and because their malignant potential has not understood fully yet. Despite the high prevalence of polyps in women with abnormal uterine bleeding, there are few reports on efficacy of polypectomy for treating them. Outcome research is needed to guide clinical decision making for those patients. Although it is intuitive that polypectomy should be effective for treating women with abnormal bleeding, polyps frequently are associated with uterine myomas that can cause abnormal bleeding and are left behind after simple polypectomies. Many polyps treated were larger than 1 cm in diameter, so it is known whether removal of very small polyps results in the same satisfaction rates. Individual patient factors led to different treatment decisions. For instance, those treated with polypectomy plus myomectomy or polypectomy plus endometrial ablation more often self-reported menorrhagia. Nathani and Clark²⁹ who reported an 88% success rate an average of 3 years after polypectomy in 51 postmenopausal women. Gebauer et al.³⁰ reported on the 1-year outcomes of 45 women treated with hysteroscopic resection of large uterine masses and found that excessive bleeding was controlled in 93% of them.

Polyps are believed commonly to be risk factor for endometrial cancer because hyperplastic and neoplastic lesions can be found in their context. Unfortunately, most of the published reports are based on specimens obtained at curettage, which fails to remove many focally growing lesions in the endometrial cavity and often extracts only scarce fragments. Hysteroscopic polypectomy is the treatment of choice because it ensures the removal of the entire lesions and not the adjacent endometrium. Primary malignant degeneration of an endometrial polyp has been quoted variably in the scientific literature, ranging from 0.5% to 4.8%. This wide range is due to different sampling techniques and different classification of polyps by the investigators. In a large unselected population of women with endometrial polyps, the rate of malignancy is low (0.8%), although the prevalence of considerably high (hyperplasia without cytologic atypia, 25.7%; hyperplasia with atypia, 3.1%) multivariate analysis.³¹

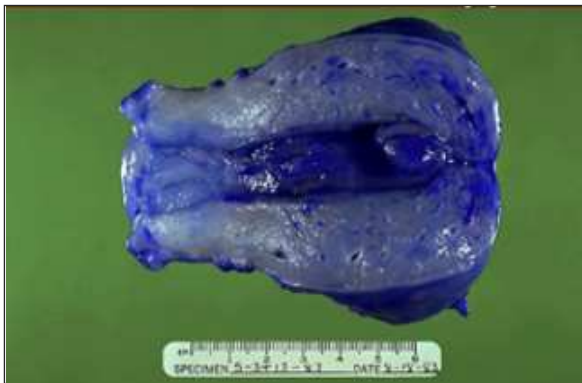


FIGURE 4: Endometrial polyps.




FIGURE 5: Endometrial polyp.

After hysteroscopic polypectomy, almost 60% of premenopausal women with abnormal uterine bleeding required further treatment because of persistence or recurrence of symptoms within a 4-year follow-up. This proportion decreased to 45% when endometrial ablation or insertion of a LNG_IUD was added to polypectomy. Probably because of the small number of patients, this difference was not statistically significant. Most patients who required further treatment received this within 1 year after polypectomy. The latter should be taken into consideration to improve counseling of patients.^{4,27,31}

To achieve complete removal of the polyp and a reliable histologic analysis, operative hysteroscopy is the treatment of choice and should be offered to symptomatic patients or to patients with risk factors (older menopausal women patients and patients with hypertension). Removal of the polyp is usually curative and probably should be done before further surgery is suggested.³²

INFERTILITY AND RECURRENT IVF FAILURE

The second important area of application of hysteroscopy is infertility diagnosis. The aim is to detect intrauterine changes which could interfere with implantation and/or growth of the conceptus. This includes cavity deformations from congenital or acquired origin such as septa, synechia, polyps or myomas. Very little is known about hysteroscopically detectable endometrial changes such as small polyps, marked and moderate mucosal elevations and endometrial hypervascularization and their significance for normal nidation, implantation and growth of the conceptus. Mini-hysteroscopy plays a key role in the evaluation of different modalities to restore the normal endometrial environment.^{15,33-35}

Infertility related to uterine cavity abnormalities has been estimated to be etiologic factor in as many as 10%-15% of couples seeking treatment.³⁶ Abnormal intrauterine findings occur in approximately 34%-62% of infertile women.^{37,38} Hysterosalpingography is a useful but indirect imaging test of the uterine cavity and remains one of the first

steps in the evaluation of the infertile couple. Routine evaluation of infertility patients with HSG has been accepted by more than 96% of board-certified reproductive endocrinologists in the United States.³⁹ Considerable variability in the interpretation as well as clinical management of HSG abnormalities has been shown among practitioners. Studies have shown that the HSG has a high sensitivity but low specificity (approximately 23%), accompanied by elevated false-negative (2%-50%) and false-positive results (15%-32%), all as compared with operative hysteroscopy as the definitive imaging technique.^{40,41}

In the routine evaluation of infertile couples, HSG has been the most commonly used diagnostic technique to determine congenital or acquired intrauterine abnormalities. Suspected pathology from HSG has traditionally been further evaluated and treated with inpatient diagnostic/operative hysteroscopy. Various studies have noted lack of agreement in approximately 30% of cases when HSG and hysteroscopy are compared.^{42,43} Outpatient diagnostic hysteroscopy has recently become available, with improved endoscopic developments and patient tolerance, as previously mentioned. Disadvantages of hysteroscopy include inadequate uterine visibility during uterine bleeding, inability to evaluate intramural and serosal portions of the uterus, as well as the adnexa for potential pathology.

One of the basic steps of the infertility workup is to assess the shape and regularity of the cavity. During the last two decades, however, several studies have demonstrated that when the uterine cavity has to be investigated within the infertility workup, hysteroscopy is much more accurate than HSG.³³ Kessler and Lancet³⁴ reported that in about two thirds of the cases hysteroscopy findings were not correlated with those found on HSG. It was shown that 54.3% of intrauterine adhesions diagnosed on HSG were not found on direct hysteroscopic examination. Another recent study comparing the diagnosis value of HSG and hysteroscopy in female infertility showed that among 79 women with normal HSG, 28 had abnormal findings on hysteroscopy, for a false negative rate of

35.4%.³⁵ Of the 135 women with an abnormal HSG, hysteroscopy demonstrated a normal uterine cavity in 21, a false positive rate of 15.6%. The sensitivity of HSG was 80.3% in revealing intrauterine abnormality and its specificity was 70.1%. Therefore, it appears that in more than one third of the cases where the HSG is interpreted as normal, it may supply a false reassurance.

Dicker et al.⁴⁴ demonstrated the value of repeated hysteroscopy in in-vitro fertilization (IVF)-embryo transfer patients in whom, without obvious reason, pregnancy did not occur. In 110 women with normal hysteroscopy findings and three or more failed IVF-embryo transfer cycles they performed a control hysteroscopy. They found in 20 cases (18.2%) abnormal findings possibly being the cause for implantation failure. It is well known that small intrauterine lesions, which may be of great significance in causing reproductive failure (such as adhesions, polyps, or submucous myomas) are diagnosed much more precisely by hysteroscopy. These lesions many times are missed by HSG or even by transvaginal ultrasonography.³³ This explains why hysteroscopy has become the routine test to assess the uterine cavity after recurrent IVF failure and recurrent aborters.

Besides the diagnosis of major pathology like uterine septa, polyps, myoma, synechia or total cavity obliteration, mini-hysteroscopy in the infertile patient frequently indicates the presence of minimal or subtle changes of the endometrium such as moderate or marked mucosal elevations, which are possibly a marker for inappropriate hormonal stimulation of the endometrium.

For women with reproductive problems, hysteroscopy is a reliable method for almost 100% detection of the intrauterine pathology and for, in a great extent, of its elimination. When hysteroscopy is routinely performed prior to in vitro fertilization, a significant percentage of patients have uterine pathology that may impair the success of fertility treatment. Patient tolerance, safety, and the feasibility of simultaneous operative correction make office hysteroscopy an ideal procedure.⁴⁵

CONCLUSION

The reduction of the total instrument diameter from 5 to 3.5 or 2.4 mm and the change of distension medium from CO₂ to watery solutions appears to increase significantly the compliance of the patient. Based on data in the current literature, hospital admissions for D&C can be avoided in > 50% of women who undergo mini-hysteroscopy for abnormal uterine bleeding disorders. The economic savings of mini-hysteroscopy can therefore be very significant. The performance of office hysteroscopy allows the surgeon to decide how best to treat the patient's problem and, often, manage it at the same setting, using suction curettage, hysteroscopically-directed, or blind biopsy, as with polyp forceps. Office hysteroscopy answers the question of whether the abnormality requires general anesthesia to dilate the cervix sufficiently to get larger-bore instruments (resectoscope, operating-channeled sheaths, etc) into the uterine cavity. In addition, office hysteroscopy most efficient allows the surgeon to plan the hospital procedure, such as whether a resectoscope can do the job adequately and if laparoscopic monitoring is needed.

With the mini-hysteroscopy, operative hysteroscopy is possible right after or even at the same time as the diagnostic examination, without anaesthesia. Simple diagnostic approach could be enough in many cases or may indicate the most convenient subsequent approach like a visually guided biopsy for local pathology or large sampling with a curette in the case of diffuse endometrial pathology. Office hysteroscopy is a safe, comfortable, enormously convenient, and precise method evaluating and managing at the same time most cases of abnormal uterine bleeding. Almost as important as its low risk and comfort to patients is the efficiency and cost effectiveness of performing the procedure at the surgeon's office rather than at a hospital or outpatient surgical center. As office hysteroscopy became a more widely applied technique for evaluation of the uterus, there were great efforts toward making the procedure even more comfortable and less hazardous by the elimination of anesthesia.

REFERENCES

- Garbin O, Kutnahorsky R, Göllner JL, Vayssiere C. Vaginoscopic versus conventional approaches to outpatient diagnostic hysteroscopy: A two-centre randomized prospective study. *Hum Reprod* 2006;21:2996-3000.
- Guida M, Di Spiezio Sardo A, Acunzo G, Sparice S, Bramante S, Piccoli R, et al. Vaginoscopic versus traditional office hysteroscopy: A randomized controlled study. *Hum Reprod* 2006;21:3253-7.
- Van Der Pas, H. *Hysterical aspects of hysteroscopy*. Hysteroscopy. Lancaster, England: MTP Press Ltd; 1983. p.3-9.
- Menken FC. Fortschritte der gynäkologischen endoskopie. In: Demling L, Ottenfann R, eds. Fortschritte der Endoskopie. Stuttgart: Bild I Schattauer; 1967.
- Lindemann HJ, Gallinat A, Lueken RP. Metro-mat. A new instrument for producing pneumometra. *J Reprod Med* 1979;23:73-5.
- Cornier E. [Ambulatory hysteroscopic treatment of persistent metrorrhagias using the Nd:YAG laser] *J Gynecol Obstet Biol Reprod (Paris)* 1986;15:661-4.
- Lin BL, Miyamoto N, Tomomatsu M, Horikoshi H, Nakamura H, Iwata Y. [The development of a new flexible hysteroscope and its clinical application] *Nippon Sanka Fujinka Gakkai Zasshi* 1987;39:649-54.
- Fayez JA. Comparison between abdominal and hysteroscopic metroplasty *Obstet Gynecol* 1986;68:399-403.
- Bettocchi S. New Era of Office Hysteroscopy *J Am Assoc Gynecol Laparosc.* 1996;3(4, Supplement):S4.
- Bettocchi S, Selvaggi L. A vaginoscopic approach to reduce the pain of office hysteroscopy. *J Am Assoc Gynecol Laparosc* 1997;4:255-8.
- Bettocchi S, Ceci O, Nappi L, Di Venere R, Masciopinto V, Pansini V, et al. Operative office hysteroscopy without anesthesia: analysis of 4863 cases performed with mechanical instruments. *J Am Assoc Gynecol Laparosc* 2004;11:59-61.
- Sharma M, Taylor A, di Spiezio Sardo A, Buck L, Mastrogamvrakis G, Kosmas I, et al. Out-patient hysteroscopy: traditional versus the 'no-touch' technique. *BJOG* 2005;112:963-7.
- Cicinelli E. Diagnostic minihysteroscopy with vaginoscopic approach: Rationale and advantages. *J Minim Invasive Gynecol* 2005; 12:396-400.
- Pansky M, Feingold M, Bahar R, Neeman O, Asiag O, Herman A, et al Improved patient compliance using pediatric cystoscope during office hysteroscopy. *J Am Assoc Gynecol Laparosc* 2004;11:262-4.
- Campo R, Van Belle Y, Rombauts L, Brosens I, Gordts S. Office mini-hysteroscopy. *Hum Reprod Update* 1999;5:73-81.
- Jones HW. III, Wentz CA, Burnett LS. *Tratado de Ginecologia de Novak*. 10th ed. Rio de Janeiro: Editora Guanabara; 1983. p.665.
- Crescini C, Artuso A, Repetti F, Reale D, Pezzica E. [Hysteroscopic diagnosis in patients with abnormal uterine hemorrhage and previous endometrial curettage] *Minerva Ginecol* 1992;44:233-5.
- Nagele F, O'Connor H, Baskett TF, Davies A, Mohammed H, Magos AL. Hysteroscopy in women with abnormal uterine bleeding on hormone replacement therapy: A comparison with postmenopausal bleeding. *Fertil Steril* 1996;65:1145-50
- Widrich T, Bradley LD, Mitchinson AR, Collins RL. Comparison of saline infusion sonography with office hysteroscopy for the evaluation of the endometrium. *Am J Obstet Gynecol* 1996;174:1327-34.
- Emanuel MH, Verdel MJ, Wamsteker K, Lammes FB. A prospective comparison of transvaginal ultrasonography and diagnostic hysteroscopy in the evaluation of patients with abnormal uterine bleeding: Clinical implications. *Am J Obstet Gynecol.* 1995;172(2 Pt 1):547-52.
- Gubbini G, Filoni M, Linsalata I, Stagnozzi R, Stefanetti M, Marabini A. [The role of hysteroscopy in the diagnosis and follow-up of endometrial hyperplasia] *Minerva Ginecol* 1998;50:125-33.
- Bedner R, Rzepka-Górska I. [Diagnostic hysteroscopy after D&C in women with perimenopausal bleeding] *Ginekol Pol* 2002; 73:577-82.
- Garuti G, Cellani F, Garzia D, Colonnelli M, Luerti M. Accuracy of hysteroscopic diagnosis of endometrial hyperplasia: a retrospective study of 323 patients. *J Minim Invasive Gynecol* 2005;12:247-53.
- Deckardt R, Lueken RP, Gallinat A, Möller CP, Busche D, Nugent W, et al. Comparison of transvaginal ultrasound, hysteroscopy, and dilatation and curettage in the diagnosis of abnormal vaginal bleeding and intrauterine pathology in perimenopausal and postmenopausal women. *J Am Assoc Gynecol Laparosc* 2002;9:277-82
- Valli E, Zupi E, Marconi D, Solima E, Nagar G, Romanini C. Outpatient diagnostic hysteroscopy. *J Am Assoc Gynecol Laparosc.* 1998;5:397-402.
- Lasmar RB, Barrozo PR, de Oliveira MA, Coutinho ES, Dias R. Validation of hysteroscopic view in cases of endometrial hyperplasia and cancer in patients with abnormal uterine bleeding. *J Minim Invasive Gynecol* 2006; 13:409-12.
- Garuti G, Sambruni I, Colonnelli M, Luerti M. Accuracy of hysteroscopy in predicting histopathology of endometrium in 1500 women. *J Am Assoc Gynecol Laparosc* 2001; 8:207-13.
- Clark TJ, Voit D, Gupta JK, Hyde C, Song F, Khan KS. Accuracy of hysteroscopy in the diagnosis of endometrial cancer and hyperplasia: A systematic quantitative review. *JAMA.* 2002;288:1610-21.
- Nathani F, Clark TJ. Uterine polypectomy in the management of abnormal uterine bleeding: A systematic review. *J Minim Invasive Gynecol* 2006;13:260-8.
- Gebauer G, Hafner A, Siebzehrübl E, Lang N. Role of hysteroscopy in detection and extraction of endometrial polyps: results of a prospective study. *Am J Obstet Gynecol* 2001;184:59-63.
- Bouda J Jr, Hradecký L, Rokyta Z. [Hysteroscopic polypectomy versus fractionated curettage in the treatment of corporal polyps-recurrence of corporal polyps] *Ceska Gynecol* 2000;65:147-51.
- Clark TJ, Godwin J, Khan KS, Gupta JK. Ambulatory endoscopic treatment of symptomatic benign endometrial polyps: A feasibility study. *Gynae Endosc* 2002;11:91-7.
- Shushan A, Rojansky N. Should hysteroscopy be a part of the basic infertility workup? *Hum Reprod* 1999;14:1923-4.
- Kessler I, Lancet M. Hysteroscopy and hysteroscopy: A comparison. *Fertil Steril* 1986;46: 709-10.
- Wang CW, Lee CL, Lai YM, Tsai CC, Chang MY, Soong YK. Comparison of hysterosalpingography and hysteroscopy in female infertility. *J Am Assoc Gynecol Laparosc* 1996;3: 581-4.
- Brown SE, Coddington CC, Schnorr J, Toner JP, Gibbons W, Oehninger S. Evaluation of outpatient hysteroscopy, saline infusion hysterosonography, and hysterosalpingography in infertile women: A prospective, randomized study. *Fertil Steril* 2000;74:1029-34
- Lindelmann HJ, Mohr J. CO2 hysteroscopy: Diagnosis and treatment. *Am J Obstet Gynecol* 1976;124:129-33.
- Gallinat A. *Hysteroscopy principles and practice*: Philadelphia: JB Lippincott 1984.
- Glatstein IZ, Harlow BL, Hornstein MD. Practice patterns among reproductive endocrinologists: The infertility evaluation. *Fertil Steril* 1997;67:443-51.

40. Goldenberg M, Bider D, Ben-Rafael Z, Dor J, Levran D, Oelsner G, et al. Hysteroscopy in a program of in vitro fertilization. *J In Vitro Fert Embryo Transf* 1991;8:336-8.
41. Golan A, Ron-El R, Herman A, Soffer Y, Bukovsky I, Caspi E. Diagnostic hysteroscopy: its value in an in-vitro fertilization/embryo transfer unit *Hum Reprod* 1992;7:1433-4.
42. Siegler AM. Hysterography and Hysteroscopy in the infertile patient. *J Reprod Med* 1977;18:143-8.
43. Valle RF. Hysteroscopy in the evaluation of female infertility. *Am J Obstet Gynecol* 1980;137:425-31.
44. Dicker D, Ashkenazi J, Feldberg D, Farhi J, Shalev J, Ben-Rafael Z. The value of repeat hysteroscopic evaluation in patients with failed in vitro fertilization transfer cycles. *Fertil Steril* 1992;58:833-5.
45. Brooks PG. In the management of abnormal uterine bleeding, is office hysteroscopy preferable to sonography? The case for hysteroscopy. *J Minim Invasive Gynecol* 2007;14:12-4.