

A Rare Type of Ectopic Kidney; Crossed Ectopy with Fusion: Case Report

Seyrek Bir Ektopik Böbrek Türü; Çapraz Kaynaşmış Renal Ektopi

İbrahim Halil KALELİOĞLU,^a
Burçin KARAMUSTAFAOĞLU BALCI,^a
Ercan BAŞTU,^a
Tayfun OKTAR,^b
Recep HAS,^a
Orhan ZİYLAN,^b
Atıl YÜKSEL^a

Departments of
^aGynecology and Obstetrics,
^bUrology,
İstanbul University İstanbul Faculty of Medicine,
İstanbul

Geliş Tarihi/Received: 25.09.2013
Kabul Tarihi/Accepted: 20.12.2013

Yazışma Adresi/Correspondence:
Burçin KARAMUSTAFAOĞLU BALCI
İstanbul University İstanbul Faculty of Medicine,
Department of Gynecology and Obstetrics,
İstanbul,
TÜRKİYE/TURKEY
burcinkaramustafaoglu@yahoo.com

ABSTRACT We herein report a case of prenatally diagnosed crossed renal ectopia with fusion. Crossed renal ectopia is a rare type of renal ectopia with an estimated occurrence of 1 in 1,000 live births. Crossed fused renal ectopia is a more rare type of ectopia, with a prevalence of 1/2000 in autopsy series. The number of reported antenatally diagnosed crossed renal ectopia is very limited in literature despite the advances in antenatal sonography. A 30-year-old, gravida 1, para 0 Caucasian woman was referred to our perinatology clinic at 36 weeks of gestation due to the difficulty in sonographic visualization of the right kidney. Ultrasound scan showed that renal parenchyma was not visible in the right renal fossa and in the right hemipelvis. In contralateral side, both renal pelvises were identifiable. Doppler ultrasonography showed two renal arteries in contralateral side, one arising from aorta, while the other one arising from left common iliac artery. Continuity between both renal parenchyma was observed; thus, the diagnosis was crossed ectopy with fusion. We want to present our case, emphasize the importance of prenatal diagnosis and summarize the difficulties and key points in prenatal diagnosis of this abnormality.

Key Words: Prenatal diagnosis; kidney pelvis; urogenital abnormalities

ÖZET Bu makalede prenatal dönemde tanısı koyulmuş çapraz kaynaşmış renal ektopi olgusunu sunmaktayız. Çapraz renal ektopi renal ektopinin seyrek görülen bir türüdür. Sıklığı canlı doğumlarda 1/1000 olarak bildirilmektedir. Çapraz kaynaşmış renal ektopi ise ektopinin daha seyrek bir türüdür ve otopsi serilerinde prevalansı 1/2000'dir. Antenatal ultrasonografideki ilerlemelere rağmen antenatal dönemde tanı konmuş çapraz renal ektopi olgu sayısı oldukça azdır. Olgumuz, 30 yaşında, gravida 1, para 0, Kafkas kökenli hasta, 36. gebelik haftasında sağ böbreğin ultrasonografide görülmemesi üzerine kliniğimize refere edilmişti. Ultrason ile incelemede sağ renal fossada ve sağ hemipelviste renal parankim izlenmedi. Her iki renal pelvis karşı tarafta izlendi. Doppler ultrason incelemede karşı tarafta, biri aortadan diğeri sol ana iliak arterden köken alan iki renal arter izlendi. Her iki renal parankim birbiriyle devam etmekteydi; böylece çapraz kaynaşmış renal ektopi olarak tanı kondu. Yazımızda olgumuzu sunmak, prenatal tanının önemini vurgulamak ve bu anomalinin prenatal tanısındaki zorluklar ile anahtar noktaları özetlemek istedik.

Anahtar Kelimeler: Prenatal tanı; renal pelvis; ürogenital anomaliler

Türkiye Klinikleri J Gynecol Obst 2014;24(4):257-60

Crossed renal ectopia is a rare type of renal ectopia with estimated occurrence of 1 in 1,000 live births.¹ In crossed renal ectopia, both kidneys are located on the same side with two separate ureters inserting into the bladder on opposite sides.² Kidneys can be fused or not. The number reports of antenatally diagnosed crossed renal ectopia is very limited in literature despite the advances in antenatal sonography. Absence of amni-

otic fluid abnormality and lack of systematic sonographic screening algorithms may contribute to the difficulties in diagnosis. We want to represent a prenatally diagnosed crossed renal ectopia to emphasize the importance of prenatal diagnosis and to summarize the difficulties and key points in prenatal diagnosis of this abnormality.

CASE REPORT

A 30-year-old, gravida 1, para 0 Caucasian woman was referred to our perinatology clinic at 36 weeks of gestation due to the difficulty in sonographic visualization of the right kidney. Her family and medical history were unremarkable. No consanguinity, no allergic reaction and no drug use except ferrous supplementation were noted. Her physical examination was normal. Her fetal sonography at 23 weeks of gestation was reported as normal. Her second trimester Down syndrome screening was normal. During the routine antenatal visit at 36 weeks of gestation, her obstetrician was unable to identify the right kidney at sonographic examination. During sonographic evaluation in our clinic, renal parenchyma was not visible in the right renal fossa and in the right hemipelvis. Ultrasonographic images of the longitudinal and transvers views of right hemithorax revealed homogeneous right lung and no different echogenicity were found in right side of thorax. Ipsilateral adrenal gland had a lying-down appearance in coronal planes. In contralateral side, both renal pelvises were identifiable, but ureters were not visible (Figure 1A). Amniotic fluid volume was normal. Doppler ultrasonography showed two renal arteries in contralateral side, one arising from aorta, while the other one arising from left common iliac artery (Figure 1B). Continuity between both renal parenchyma was observed; thus, the diagnosis was crossed ectopy with fusion. Remainder weeks of the pregnancy were uneventful and the patient delivered at 38 weeks of gestation. Postnatal ultrasonography of the newborn confirmed the diagnosis of crossed ectopic kidney and showed no hydronephrosis. Physical examination of the newborn was unremarkable. However, the urine culture obtained at 3 days of age revealed *Escherichia*

coli colonization (100,000 cfu/ml). A voiding cystourethrography was performed and no vesicoureteral reflux was detected (Figure 1C). A DMSA (technetium dimercaptosuccinic acid) scan revealed a normally located and sized left kidney with right kidney connected to its inferior pole, without any scar formation (Figure 1D). The child was on regular follow-up and no urinary tract infection and no hypertensive disorder were developed.

DISCUSSION

Most common sites of ectopia are immediately inferior to the aortic bifurcation, predominantly in left side, which is referred as pelvic kidney. Lumbar kidneys are localized anterior to iliac vessels and are the consequence of migration ending at L2. Superior ectopia in thorax is rare and unexpectedly always asymptomatic with few associated anomalies. Crossed fused renal ectopia is a more rare type of ectopia, with a prevalence of 1/2000 in autopsy series.³

Crossed renal ectopia occurs more often in men (3:2) and is usually a left-to-right ectopia.³ In our case, the crossing was right-to-left style. Several variations of crossed-fused renal ectopia exist and they are mainly classified in four different groups: crossed ectopia with fusion, crossed ectopia without fusion, solitary crossed renal ectopia and bilaterally unfused crossed ectopia.⁴ If two developing metanephros come into contact, fusion abnormalities may develop. The fusion anomalies have been classified as unilateral fused kidney with inferior ectopia which is the most common type, followed by sigmoid or S shaped, lump or cake, L-shaped or tandem, disc or doughnut and unilateral fused kidneys with superior ectopia.^{1,5} In our case, unilateral fused kidney with inferior ectopia was detected, not in antenatal period but postnatally. In fact, crossed fused renal ectopia is usually diagnosed in postnatal period, as an incidentally when the patient is examined for other reasons.

Renal anomalies leading to unilateral empty renal fossa such as unilateral renal agenesis and renal ectopia are difficult to diagnose in antenatal sonography due to the fact that kidneys are not examined with standard methods. In such cases, am-

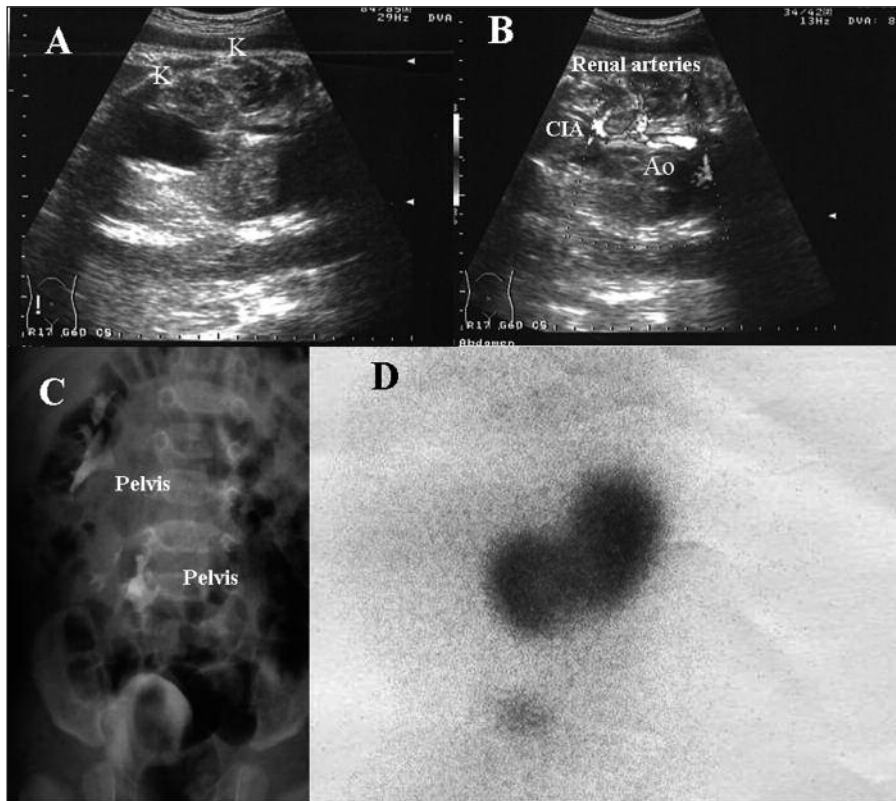


FIGURE 1: The visualization of the kidneys in different modalities and renal vasculature. **A)** Both renal pelvises are identifiable on ipsilateral side, but ureters are not. (K: kidney) **B)** Two renal arteries on ipsilateral side, one arising from aorta, the other one from left common iliac artery. (Ao: aorta, CIA: common iliac artery) **C)** Voiding cystourethrography without vesicoureteral reflux. **D)** DMSA scan showing a normally located and sized left kidney with right kidney connected to its inferior pole.

niotic fluid volume is usually normal and do not cause suspicion. It is also easy to make the misdiagnosis of an abnormal or even normal kidney if the bowel fills the contralateral renal fossa.

The initial and most important stage in fetal renal sonographic evaluation is the observation of both renal pelvises. If a difficulty in visualization of renal pelvis is noted during sonography, fetus must be screened for empty renal fossa and lying-down suprarenal gland. Ipsilateral fetal pelvis, lumbar area and even thorax and contralateral side must be explored. If an ectopic kidney is not noted during the sonographic scan, the probable diagnosis is renal agenesis.

If a crossed renal ectopia is diagnosed, both kidneys must be reevaluated for fusion and type of crossed ectopia but prenatal classification is almost impossible in some cases. Renal fusion can mimic a renal mass, a duplicated system or a hypertrophic kidney and lead to a misdiagnosis. Classification of

crossed fused renal ectopy is not easy in antenatal period and is expected to add nothing to antenatal and neonatal management. Even in postnatal period there is no evidence supporting that this classification contributes to the long-term prognosis.

The blood supply of the fused kidney is extremely variable and may be from contralateral side. Doppler sonography will reveal the type of vascular supply. In our case, Doppler ultrasonography showed two renal arteries in contralateral side, one arising from aorta, the other from left common iliac artery (Figure 1B). In cases with anomalous course of the renal artery, hypertensive disorders may occur. Our case did not have hypertension in childhood.

Following final diagnosis of crossed ectopia, other systems must be scanned for possible associated anomalies. Cardiovascular, musculoskeletal, genital and gastrointestinal system anomalies may be associated with crossed ectopia.⁶ The antenatal

ultrasound of our case did not reveal any additional abnormality; neither did other postnatally done investigations.

Because of its abnormal shape, rotation, and vasculature, crossed renal ectopia has a higher association with other diseases of the urinary tract system which are vesicoureteral reflux, hydro-nephrosis, nephrolithiasis, urinary tract infections, ureteropelvic junction obstruction, multicystic dysplasia, ectopic ureterocele, and renovascular hypertension later in life, and in rare cases renal tumors.⁶ This is the reason why prenatal diagnosis is important; it leads to close follow-up of affected neonates and may prevent long term complications. The drainage from the collecting system may be impaired due to the abnormal renal position and this, in turn, may predispose to urinary

tract infection and calculus formation. A voiding cystourethrography is recommended to all patients because of the high incidence of vesicoureteral reflux. Voiding cystourethrography was performed to our patient and no vesicoureteral reflux was detected (Figure 1C). Treatment of crossed-fused renal ectopia is indicated for the complications of the anomaly.¹

In conclusion, fetal urinary system must be evaluated in a standard discipline during sonography even though amniotic volume is normal. Crossed renal ectopia must be excluded when an empty renal fossa is noted during fetal sonographic scan because this can lead to more severe complications in postnatal period when compared with other types of renal ectopia. It can also be associated with congenital anomalies of other systems.

REFERENCES

1. Ghosh BC, DeSantis M, Kleyner Y, Zak Y. Crossed fused renal ectopia with calculi. *J Am Coll Surg* 2008;206(4):753.
2. Rinat C, Farkas A, Frishberg Y. Familial inheritance of crossed fused renal ectopia. *Pediatr Nephrol* 2001;16(3):269-70.
3. Patel TV, Singh AK. Crossed fused ectopia of the kidneys. *Kidney Int* 2008;73(5):662.
4. Oh KY, Holznagel DE, Ameli JR, Sohaey R. Prenatal diagnosis of renal developmental anomalies associated with an empty renal fossa. *Ultrasound Q* 2010;26(4):233-40.
5. Bauer SB. Anomalies of the upper urinary tract. In: Wein AJ, Kavoussi LR, Novick AC, Partin AW, Peters CA, Ramchandani P. *Campbell-Walsh Urology*. 9th ed. Philadelphia: Saunders Elsevier; 2007. p.3283-327.
6. Bauer SB. Anomalies of the upper urinary tract. In: Walsh PC, Retik AB, Vaughan ED, Wein AJ, eds. *Campbell's Urology*. 8th ed. Philadelphia: WB Saunders; 2002. p.1898-906.