

# The Role of HPV Infection in the Cervical Intraepithelial Neoplasia

HPVİNFEKSİYONUNUN SERVİKAL İNTRAEPİTELYAL NEOPLAZİDEKİ ROLÜ

Dr.İlkan DÜNDER\*, Dr.Selda SEÇKİN\*\*, Prof.Dr.Sevgi TEZCAN\*,  
Yrd.Doç.Dr.Fırat ORTAÇ\*, Doç.Dr.Fehmi AKSOY\*\*, Prof.Dr.Hikmet YAVUZ\*

\* University of Ankara, Faculty of Medicine, Department of Gynecology and Obstetrics  
\*\* Ankara Numune Hospital, Department of Pathology, ANKARA

## SUMMARY

Fifty patients with the complaints of vaginal discharge and postcoital bleeding were evaluated clinically and colposcopically. Biopsy specimens and smears were taken during colposcopic examination and were diagnosed as Cervical Intraepithelial Neoplasia Grade I (CIN I) in 39 and Cervical Intraepithelial Neoplasia Grade II (CIN II) in 11 cases. The cytopathologic findings in 13 of 39 cases with CIN II were consistent with dysplasia and HPV infection in cases which were clinically suspicious was confirmed, on the other hand, besides the evaluation of patients with the findings of HPV infection for co-existing CIN, the importance of assessment of patients with the diagnosis of CIN for HPV infection was emphasized.

**Keywords:** Human papilloma virus infection, Cervical intraepithelial neoplasia

Anatolian J Gynecol Obst 1992 2:185-186

In gynecologic pathology, precancerous cervical lesions and the processes of progression to invasive carcinoma has been one of the most attractive and intensively studied subjects of the last few decades (1). In this respect, HPV infections and HPV related lesions are probably the most important issues in assesment the patients in high-risk category.

Papillomaviruses are double-stranded DNA tumor viruses and are epitheliotropic (2). It is clear by many examples that papillomavirus has potential as an oncogenic virus in human (3). HPV infection shares

Geliş Tarihi: 1.1.1992

Kabul Tarihi: 25.1.1992

Yazışma Adresi: Dr.Selda SEÇKİN  
23.Sokak7/8  
Bahçelievler - ANKARA

This paper has been presented at International istanbul  
Symposium on Obstetrics and Gynecology,. 3-6 June 1991

Anatolian J Gynecol Obst 1992, 2

## ÖZET

Vajinal akıntı ve postkoital kanama yakınmaları ile başvuran 50 hasta klinik ve kolposkobik olarak değerlendirildiler. Kolposkobik muayene sırasında alınan smear biopsi örnekleri 39 vakada Servikal İntraepitelyai Neoplazi Grade I (CIN I), 11 vakada Servikal İntraepitelyai Neoplazi Grade II (CIN II) olarak tanı aldılar. 39 CIN I'li hastanın onüçünde, 11 CIN II'li hastanın sitopatolojik bulgular HPV enfeksiyonu bulgularını saptamada biopsinin önemi ve gerekliliği belirtildi. Ayrıca, HPV enfeksiyonu bulguları olan hastaların CIN yönünden, CIN tanısı alan hastaların da HPV enfeksiyonu açısından değerlendirilmesinin önemi vurgulandı.

**Anahtar Kelimeler:** Human papilloma virüs enfeksiyonu,  
Servikal intraepitelyai neoplazi

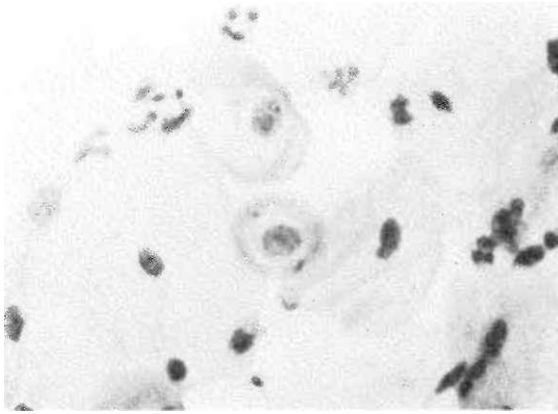
TKlin Jinekoloj Obst 1992, 2:185-186

many of the epidemiologic features of cervical neoplasia and this strengthens the possibility that it may be a causative agent in cervical cancer (2).

Cervical intraepithelial neoplasia (CIN), which has been the term proposed and widely accepted for defining the precancerous status of cervix, is usually divided into 3 grades (CIN I, CIN II, CIN III) and this emphasizes that all lesions require treatment (2).

## MATERIALS AND METHODS

Patients peresented with the symptoms of vaginal discharge and postocital bleeding admitted to University of Ankara, Faculty of Medicine, Department of Gynecology and Obstetrics were evaluated clinically and colposcopically. Then cervical smears and colposcopically directed biopsies were taken and diagnosed at Numune Hospital, Department of Pathology. Cervical smears were stained by PAP stain and routinely processes biopsy specimens were stained by NE stain and both were evaluated under light microscopy. Out



**Figure 1** Koilocytes in the center with hyperchromatic nuclei, prominent perinuclear halos and blunted cellular margins (PAP smear).

of these patients, 50, who had been diagnosed as CIN cases, were included in this study.

## RESULTS

Of these 50 patients, 39 were diagnosed as CIN I and 11 as CIN II. Besides, these cases were evaluated for HPV infection and 13 of 39 CIN I cases and 4 of 11 CIN II cases were found to have findings consistent with HPV infection (34%). Koilocytes that have dysplastic nuclei with perinuclear halo, binuclear cells, cells with blunted margins that lost their polygonal forms, loss of cytoplasmic transparency and large aggregates of squamous epithelial cells were the features diagnostic for consistency of HPV infection in PAP smears (Figure 1). In tissue sections, HPV infections, HPV infections was characterized particularly by koilocytotic atypia in superficial layers. Individual cell keratinization, parakeratosis, acanthosis were the other features (Figure 2).

In 13 CIN I cases findings consistent with HPV infection were found in 2 cases in only smears, in 5 cases in only biopsies and in 6 cases in both smears and biopsies. In 4 CIN II cases findings consistent with HPV infection were found in only biopsies. No cases were diagnosed by smear.

## DISCUSSION

It is well known that HPV is associated with CIN and invasive carcinoma (2). Unfortunately diagnosis of HPV infection has increased in incidence so that now may be the most common sexually transmitted disease (4). There might be no difference between HPV (+) and (-) cases clinically and colposcopically but by cytopathologic evaluation this certainty could be stated. If the characteristic cytologic and histologic findings consistent with HPV infection are noted, over 95% of such cases will be detected to contain the virus (4). In our study, out of 50 CIN cases, 17 have



**Figure 2** CIN I lesion with findings consistent with HPV infection (tissue section).

been diagnosed as findings consistent with HPV infection.

CIN cases should be searched for HPV infection findings although it is not certainly established that HPV infection increases the risk of progression of this intraepithelial neoplastic process to invasive carcinoma. Still it is enough for alarming the clinician and the pathologist as HPV is an oncogenic virus and highly detected in carcinoma patients (3).

On the other hand, patients with findings of HPV infection should be evaluated for CIN by cervical smear and biopsy as it is indicated that HPV detection in women with cervical lesions predicts current or future CIN in such patients (4).

In the present study, most of the cases with HPV infection findings have been diagnosed by biopsy. Therefore we want to stress the importance of evaluating particularly the biopsy specimens of clinically and colposcopically suspicious patients.

This is a preliminary report of our study which is to be continued by clinical and pathological findings of follow ups after treatment.

## REFERENCES

1. Crum CP. Identifying High-Risk Precursors of Cervical Cancer. *AJCP* 1989; 92:379-82.
2. Wright TC, Richard RM. Role of Human Papillomavirus in the Pathogenesis of Genital Traet Warts and Cancer. *Gyn Oncol* 1990; 37:151-64.
3. Arends MJ, Wyllie AH, Bird CC. Papillomaviruses and Human Cancer. *Human Pathol* 1990; 21:686-98.
4. Nuovo GJ, Blanco JS, Leipzig S, Smith D. Human Papillomavirus Detection in Cervical Lesions Nondiagnostic for Cervical Intraepithelial Neoplasia: Correlation with Papanicolaou Smear, Colposcopy and Occurrence of Cervical Intraepithelial Neoplasia. *Obs Gyn* 1990; 75:1006-11.