

Incidental Diagnosis of Primary Fallopian Tube Carcinoma at Vaginal Hysterectomy and Bilateral Salpingo-oophorectomy in a Patient with Uterine Prolapse and No Macroscopically Pathological Findings on Ovaries and Tuba Uterine

MAKROSKOPİK OLARAK OVER VE TUBALARINDA PATOLOJİK BULGUSU BULUNMAYAN, UTERUS PROLAPSUSU OLAN BİR HASTADA VAJİNAL HİSTEREKTOMİ VE BİLATERAL SALPINGOOFEREKTOMİ SIRASINDA TESADÜFİ PRİMER FALLOP TÜP KANSERİ TEŞHİSİ

Münire ERMAN AKAR, MD,^a Tayup ŞİMŞEK, MD,^a Esra TAMBURACI, MD,^a Gülgün ERDOĞAN, MD,^b Elif PEŞTERELİ, MD^b

Departments of ^aGynecology and Obstetrics, ^bPathology, Akdeniz University Faculty of Medicine, ANTALYA

Abstract

A 52-year old woman with uterine prolapse who was diagnosed as primary fallopian adenocarcinoma following pathological evaluation of the vaginal hysterectomy and bilateral salpingo-oophorectomy specimen was presented. After adenocarcinoma diagnosis, the patient had undergone pelvic, paraaortic lymph node dissection, peritoneal washing, peritoneal sample biopsy, omentectomy and appendectomy. She was staged as FIGO IIIC because of two positive lymph nodes out of 35 lymph nodes.

We suggest transvaginal ultrasonography and elective oophorectomy to be performed in all postmenopausal patients undergoing hysterectomy for the possible diagnosis of gynecologic malignancies.

Key Words: Fallopian tube cancer, vaginal hysterectomy, bilateral salpingo-oophorectomy

Özet

Bu vaka takdiminde rahim sarkması şikayeti ile kliniğimize başvuran ve yapılan vajinal histerektomi ve bilateral salpingooferektomi işlemi sonrası primer fallop tüpü adenokarsinomu tanısı konan 52 yaşındaki bir hastayı sunuyoruz. Adenokarsinom tanısının ardından hastaya pelvik, paraaortik lenf nodu diseksiyonu, periton yıkama ve apendektomi işlemleri yapıldı. Otuz beş lenf nodundan ikisinde metastaz tespit edilen hastada tümör, FIGO sınıflamasına göre Evre IIIC olarak sınıflandırıldı.

Histerektomi planlanan tüm postmenopozal hastalarda, olası jinekolojik kanserlerin teşhis imkanı için, transvajinal ultrasonografi ve elektif ooferektomi yapılmasını öneriyoruz.

Anahtar Kelimeler: Fallop tüpü kanseri, vajinal histerektomi, bilateral salpingooferektomi

Türkiye Klinikleri J Gynecol Obst 2005, 15:222-224

Primary fallopian tube carcinoma represents less than 1% of all gynecological malignancies.^{1,2} Most common presenting symptoms are perimenopausal or postmenopausal bleeding or amber coloured vaginal discharge and abdominal pain.

However, a minority of cases are asymptomatic and diagnosis is only possible after surgical removal of the tube. Because of the rarity and unusual presentation of this tumor, there is no consensus as to the optimum diagnostic management.

In this case, we presented a case with primary carcinoma of the fallopian tube diagnosed incidentally at vaginal hysterectomy and bilateral salpingo-oophorectomy.

Case

A 52-year old, gravida 5, para 3 woman presented with uterine prolapse. She was menopausal

Geliş Tarihi/Received: 22.12.2004 Kabul Tarihi/Accepted: 06.06.2005

Yazışma Adresi/Correspondence: Münire ERMAN AKAR, MD
Pınarbaşı Mahallesi 704. Sok.
Palmiye Sitesi C Blok No:6, ANTALYA
mnirea@yahoo.com

Copyright © 2005 by Türkiye Klinikleri

for 3 years. She did not have a history of either vaginal discharge or vaginal bleeding or chronic salpingitis. In physical examination the patient was found to be normal. In gynecological examination the patient had a second degree uterine prolapse. The uterus and adnexa were not palpable. The transvaginal ultrasonographic evaluation revealed no pathology. The Papanicolaou smear was negative. The patient was not investigated for Ca125 levels before the operation.

Vaginal hysterectomy with elective bilateral salpingo-oophorectomy were performed. The tubes and ovaries seemed macroscopically normal. The definitive histopathological diagnosis was right tubal serous adenocarcinoma (Figure 1). After adenocarcinoma diagnosis, the patient had undergone a second operation with pelvic, paraaortic lymph node dissections, peritoneal washing, sampling, omentectomy and appendectomy.

She was staged as FIGO IIIC, because of two positive lymph nodes out of 35 lymph nodes. Six cycles of paclitaxel (175 mg/m²) plus cisplatin (75mg/ m²) combination chemotherapy were administered with 3-week intervals between cycles.

Discussion

The fallopian tube carcinomas account for 0.15-1.9% of all gynecological cancers.¹⁻⁵ Most common presenting symptoms of patients with

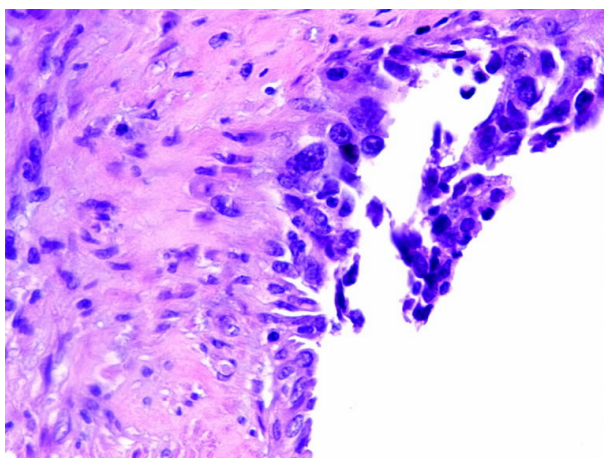


Figure 1. Microscopic findings demonstrating carcinoma in situ of the right fallopian tube.(Hematoxylin-eosin stain, original magnification X400).

fallopian tube carcinoma are abdominal pain and abnormal vaginal discharge or bleeding, and the most common finding is an adnexal mass.⁵⁻¹⁰ However a minority of patients are asymptomatic and diagnosis is only possible after operation.⁷⁻¹⁰ Low parity, late menopause and chronic salpingitis have often been found to be associated with this malignancy.⁹ Diagnosis is usually confirmed at the time of operation or by the pathologist on histopathologic examination.⁵

A few investigators have reported tubal carcinoma with micrometastasis at the ovary of the same side following vaginal hysterectomy and bilateral salpingectomy in their series.^{11,12}

Bilateral salpingo-oophorectomy is not routinely performed in vaginal hysterectomy cases unless adnexial pathology is suspected. The reason may be technical difficulties for safety removal of the tubes and ovaries. When the ovaries and tubes are removed vaginally, it is difficult to peritonize the infundibulopelvic ligament which is a distinct disadvantage.¹³ Absolute hemostasis should be maintained. In a prospective study by Davies et al, the feasibility and safety of vaginal removal of ovaries at the time of vaginal hysterectomy was assessed and no disadvantage was reported other than operation time.¹⁴ The investigators proposed that the need to perform oophorectomy should not be considered a contraindication to vaginal hysterectomy.

Stage of the disease at the time of diagnosis is the most important factor affecting prognosis and 5-year survival rate in patients with fallopian tube carcinoma.^{3,9} Therefore early diagnosis is very important.

Considering the unusual presentation and difficulty in preoperative diagnosis of primary fallopian tubal carcinoma cases, we recommend transvaginal ultrasonography and elective oophorectomy to be performed in all postmenopausal patients undergoing hysterectomy for the possible diagnosis of gynecologic malignancies .

However, for definite conclusions about the effectivity of elective oophorectomy in fallopian tube malignancies, more studies with larger number of cases are mandatory.

REFERENCES

1. Jones CV. Primary carcinoma of the uterine tube. *Obstet Gynecol* 1965;26:122.
2. Di Re E, Grosso G, Raspagliesi F, Baiocchi G. Fallopian tube cancer: incidence and role of lymphatic spread. *Gynecol Oncol* 1996;62:199-202.
3. Alvarado-Cabrero I, Young RH, Vamvakas EC, Scully RE. Carcinoma of the fallopian tube: A clinicopathologic study of 105 cases with observations on staging and prognostic factors. *Gynecol Oncol* 1999;72:367-79.
4. Erez S, Kaplan AL, Wall JA. Clinical staging of carcinoma of the uterine tube. *Obstet Gynecol* 1967;30:547-50.
5. Nordin AJ. Primary carcinoma of the fallopian tube: A 20-year literature review. *Obstet Gynecol Surv* 1994;49:349-61.
6. Gungor T, Keskin L, Zergeroğlu S, Keskin E, Yalçın H, Aydoğdu T, Küçüközkan T. Primary carcinoma of the fallopian tube: The rarest gynecologic malignancy: (Report of five cases) *GORM* 2004;10:54-6.
7. Eddy GL, Copeland LJ, Gershenson DM, Atkinson EN, Wharton JT, Rutledge FN. Fallopian tube carcinoma. *Obstet Gynecol* 1984;64:546-52.
8. Daskalkis G, Kiosses E, Katsetos C, Petrogiannis N, Michalas S. Primary carcinoma of the fallopian tube. *Eur J Gynaecol Oncol* 1998;19:384-5.
9. Jerezek B, Jassem J, Kobierska A. Primary cancer of the fallopian tube. Report of 26 patients. *Acta Obstet Gynecol Scand* 1996;75:281-6.
10. Tulunay G, Arvas M, Demir B, Demirkiran F, Boran N, Bese T, Ozgul N, Kose MF, Kosebay D. Primary fallopian tube carcinoma: a retrospective multicenter study. *Eur J Gynaecol Oncol* 2004;25:611-4.
11. Hohlweg-Majert P, Liebenstein J, Castillo M. Vaginal hysterectomy with bilateral adnexectomy. *Fortschr Med*. 1984;102:183-5.
12. Piura B, Rabinovich A. Primary carcinoma of the fallopian tube: study of 11 cases. *Eur J Obstet Gynecol Reprod Biol* 2000;91:169-75.
13. Thompson JD, Warshaw J. Hysterectomy . In : Rock JA, Thompson JD, eds. *Telinde's Operative Gynecology*, Philadelphia, New York: Lippincott-Raven 8th ed. 1997. p.817-31.
14. Davies A, O'Connor H, Magos AL. A prospective study to evaluate oophorectomy at the time of vaginal hysterectomy. *Br J Obstet Gynaecol* 1996;103:915-20.