

Synchronous Fallopian Tube Adenocarcinoma with Endometrium Adenocarcinoma, Or Distinct Primary Tumor is Adjuvant Therapy Necessary?: Case Report

Endometrium Adenokarsinomu ile Fallop Tüpü Adenokarsinomu Birlikteliği, İki Ayrı Primer Tümör, Adjuvan Tedavi Gerekli midir?

Murat ÖZ,^a
Emre ÖZGÜ,^a
Tayfun GÜNGÖR,^a
Serap AKBAY^b

Clinics of

^aGynecology Oncology,

^bPathology,

Zekai Tahir Burak Women's Health Training and Research Hospital, Ankara

Geliş Tarihi/Received: 06.08.2013

Kabul Tarihi/Accepted: 12.12.2013

Yazışma Adresi/Correspondence:

Murat ÖZ

Zekai Tahir Burak Women's Health

Training and Research Hospital,

Clinic of Gynecology Oncology, Ankara,

TÜRKİYE/TURKEY

ozmurat@gmail.com

ABSTRACT Co-occurrence of endometrial and fallopian cancer may be problematic because stage of the disease may alter if endometrium carcinoma involves fallopian tubes rather than being de novo tumor of fallopian tube. In our case, a 61 year-old woman presented with postmenopausal bleeding. Low grade endometrioid adenocarcinoma was noted in the pathological examination of the endometrial sampling. The disease was surgically staged according to FIGO guidelines. Grade 1 endometrioid tumor was noted confined to the mucosa of the distal portion of the right fallopian tube with a normal proximal tubal segment concomitant with grade 1 endometrioid type endometrium cancer. There is little information about simultaneous presentation of endometrial and fallopian tube adenocarcinoma in the literature. In conclusion, complete pathological evaluation has to be done with grossly normal appearing fallopian tubes and ovaries because there can be found occult tumoral sites in relatively significant portion of endometrium cancer patients.

Key Words: Endometrial neoplasms; fallopian tube neoplasms; chemotherapy, adjuvant

ÖZET Endometrium ve fallop tüpüne ait adeno kanser birlikteliği klinik olarak birtakım zorlukları da beraberinde getirir, çünkü endometrium kanserinin tubal invazyonu yerine tubadan kaynaklanan de novo ikincil primer kanser olarak değerlendirilmesi hastalığın evresini değiştirecektir. Olgumuz 61 yaşındaki kadın hasta postmenopozal kanama ile başvurduğunda yapılan endometrial örnekleme sonucu düşük dereceli endometrioid tip endometrium adenokanseri olarak raporlandı. Hasta FIGO önerilerine uygun şekilde cerrahi olarak evrelendi. Endometriuma sınırlı grade 1 endometrioid tip endometrium kanseri yanında sağ tubanın distal kesiminde mukozaya sınırlı, grade 1 adenokanser saptandı. Literatürde endometrium ve tubadan eş-zamanlı kaynaklanan adenokanser hakkındaki veriler sınırlıdır. Sonuç olarak tüm endometrium kanseri vakalarında normal görülen tuba ve overler bile seri histolojik kesitlerle incelenmelidir, çünkü endometrium kanseri olgularının nispeten önemli bir kısmında tuba ve overlerde okkült kanser odakları saptanabilmektedir.

Anahtar Kelimeler: Endometriyal tümörler; fallop tüpü tümörleri; kemoterapi, adjuvan

Türkiye Klinikleri J Gynecol Obst 2014;24(3):191-4

Simultaneous presentation of ovarian and endometrial endometrioid adenocancer is well known as well as simultaneous ovarian and fallopian tube serous adenocancer is. But little is known about a similar phenomenon involving the endometrium and the fallopian tube, with only a few cases mentioned in the literature thus far, and co-occurrence of endometrial and fallopian cancer may be problematic. In most cases it may be difficult to define that the cancer in the fallopian tube is whether direct in-

vasion/metastasis of endometrium cancer or another primary neoplasia.^{1,2} It is important to make the accurate diagnosis for the pathologist to plan further adjuvant therapy if needed. The stage of the cancer would be IIIA in case of tumoral involvement of the fallopian tube rather than stage I fallopian tube carcinoma in case of another primary tumor in the fallopian tube.³ Recommended adjuvant treatment option for stage III endometrium carcinoma is chemotherapy with or without radiotherapy.⁴ On the other hand, there is no need for adjuvant therapy for stage I grade 1 endometrioid endometrium concomitant with stage IA fallopian tube cancer.

CASE REPORT

In our case, a 61 year-old woman presented with postmenopausal bleeding. Her medical history was unremarkable. Transvaginal ultrasonography revealed 9 mm endometrial thickness. A probe-curettage was performed. Low grade endometrioid adenocarcinoma was detected in the pathological examination of the endometrial sampling. Additional imaging procedures were performed and no findings for extra-uterine involvement or metastasis were noted. Hysterectomy with bilateral salpingo-oophorectomy with frozen section was made. Frozen section showed endometrioid adenocarcinoma confined to the endometrium. The procedure was followed by peritoneal washing and bilateral pelvic para-aortic lymphadenectomy. Final pathology result was negative for peritoneal cytology and dissected 47 lymph nodes. Tumor was nuclear and architectural grade 1, confined to the endometrium (Figure 1, 2). Lympho-vascular space involvement was negative. Grade 1 endometrioid tumor was noted confined to the mucosa of the distal portion of the right fallopian tube (Figure 3, 4), with a normal proximal tubal segment (Figure 5). Immunohistochemistry staining of the fallopian tumor was positive for CD10, ER, PR, WT1 and Ki-67. These findings were supportive for synchronous tumors of the endometrium and fallopian tube. Even so we planned a chemo-radiotherapy combination for adjuvant therapy after primary surgery due to lack of enough data in the literature.

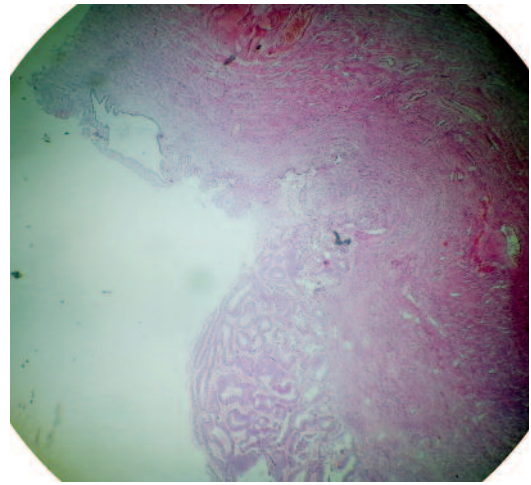


FIGURE 1: Grade 1 endometrioid type endometrium carcinoma, confined to the endometrium, low magnification. (HE,x10).

(See color figure at

<http://www.turkiyeklinikleri.com/journal/jinekoloji-obstetrik-dergisi/1300-0306/>)

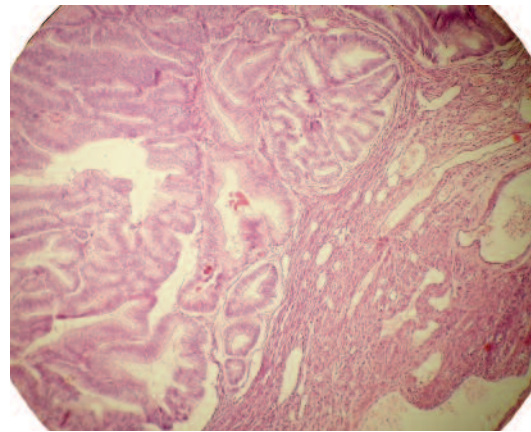


FIGURE 2: Grade 1 endometrioid type endometrium carcinoma, confined to the endometrium, high magnification. (HE, X40).

(See color figure at

<http://www.turkiyeklinikleri.com/journal/jinekoloji-obstetrik-dergisi/1300-0306/>)

DISCUSSION

The occurrence of synchronous endometrioid carcinomas in the uterus and fallopian tube is a very rare event and there is not adequate data in the literature about synchronous fallopian tube adenocarcinoma with endometrial adenocarcinoma to determine adjuvant therapy strategies.⁵ Culton et al. presented 13 cases seen over an 8 year old period.⁶ In this report most of the patients had endometrioid type tumor both in endometrium and fallopian tube like our case. Our patient was 61 years old, the mean age of the patients ranges from

55 to 59 in the reported cases and almost all patients had abnormal uterin bleeding. In our case, the tumor did not extend to the serosal surface of the uterus or fallopian tube. The possibility of metastasis was excluded using the criteria proposed by Alvarado-Cabrero et al.¹

It is known that K-ras proto-oncogene mutation in endometrial carcinoma is independent risk factor for poor prognosis, the same mutation is shown in the fallopian tube carcinomas suggestive of similar genetic basis of the two carcinomas.⁷

Malignant cells derived from endometrial carcinoma may spread through fallopian tubes to the peritoneum, and usually this is seen in high grade and high stage disease.⁸ Presence of intraluminal tumor cells in the fallopian tube is correlated strongly with positive peritoneal fluid cytology and with peritoneal metastasis in high grade tumours. In our case, tumor was grade 1 and negative for peritoneal washing cytology and lymph node metastasis, that is supportive for synchronous primary tumors of endometrium and fallopian tube.

In the series of Culton et al. all of the tumors were interpreted as independent primaries and adjuvant therapy was planned accordingly.⁶ One patient had stage 1A endometrium cancer with stage

1A1 fallopian tube adenocancer and did not receive any adjuvant treatment and unexpectedly died of disease progression 38 months after primary surgery. In this context, interpretation of tumors as independent primaries is questionable.

Patients with this tumor combination are usually postmenopausal, obese, nulliparous, and present with abnormal uterine/vaginal bleeding. Both tumors are typically low grade and stage, which

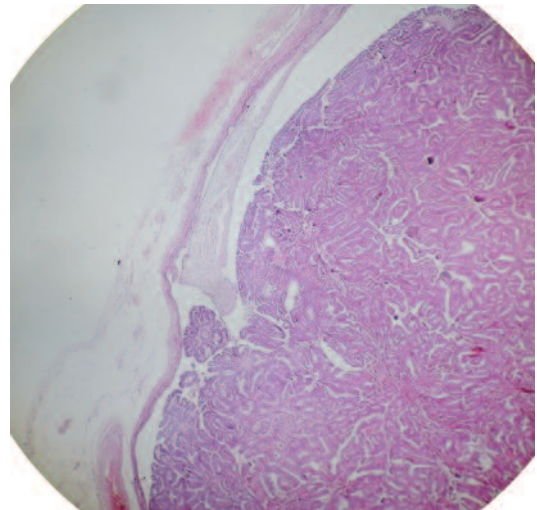


FIGURE 3: Grade 1 endometrioid type adeno carcinoma, in the fallopian tube, compressing the wall of the tube, low magnification. (HE, x10).

(See color figure at <http://www.turkiyeklinikleri.com/journal/jinekoloji-obstetrik-dergisi/1300-0306/>)

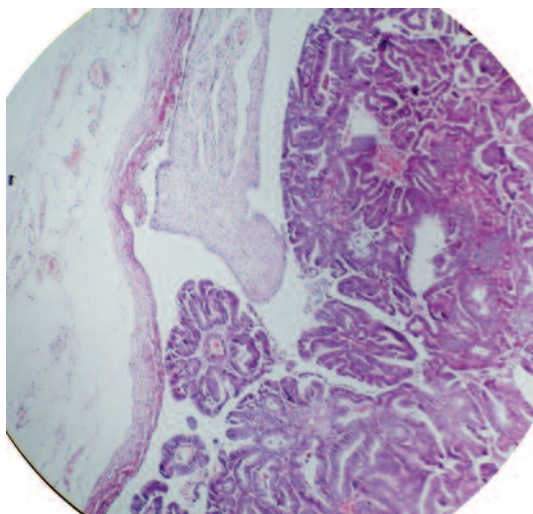


FIGURE 4: Grade 1 endometrioid type adeno carcinoma, in the fallopian tube, compressing the wall of the tube, high magnification. (HE, x 40).

(See color figure at <http://www.turkiyeklinikleri.com/journal/jinekoloji-obstetrik-dergisi/1300-0306/>)

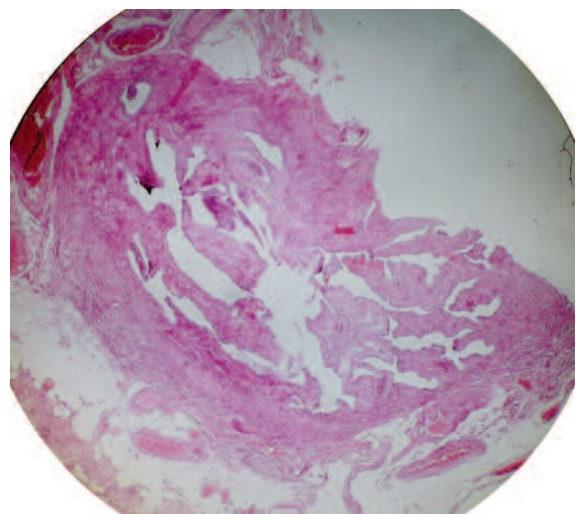


FIGURE 5: Normal proximal tubal segment, low magnification. (HE, x10).

(See color figure at <http://www.turkiyeklinikleri.com/journal/jinekoloji-obstetrik-dergisi/1300-0306/>)

may translate into a good prognosis for these patients; however, additional studies are required to confirm the biologic behavior of these cases.⁶

In conclusion, complete pathological evaluation has to be done with grossly normal appearing

fallopian tubes and ovaries because there can be found occult tumoral sites in relatively significant portion of endometrium cancer patients,⁹ but still there is not enough data in the literature about this dilemma, and further studies are needed.

REFERENCES

1. Alvarado-Cabrero I, Young RH, Vamvakas EC, Scully RE. Carcinoma of the fallopian tube: a clinicopathological study of 105 cases with observations on staging and prognostic factors. *Gynecol Oncol* 1999; 72(3):367-79.
2. Tong SY, Lee YS, Park JS, Bae SN, Lee JM, Namkoong SE. Clinical analysis of synchronous primary neoplasms of the female reproductive tract. *Eur J Obstet Gynecol Reprod Biol* 2008;136(1):78-82.
3. Lewin SN. Revised FIGO staging system for endometrial cancer. *Clin Obstet Gynecol* 2011;54(2):215-8.
4. Johnson N, Bryant A, Miles T, Hogberg T, Cornes P. Adjuvant chemotherapy for endometrial cancer after hysterectomy. *Cochrane Database Syst Rev* 2011;10: CD003175. doi: 10.1002/14651858.CD003175.pub2.
5. To N, Tsukamoto N, Maeda K, Kaku T, Toki N, Shigematsu T, et al. [Seven cases of primary adenocarcinoma of the fallopian tube]. *Nihon Gan Chiryō Gakkai Shi* 1989;24(1):16-20.
6. Culton LK, Deavers MT, Silva EG, Liu J, Malpica A. Endometrioid carcinoma simultaneously involving the uterus and the fallopian tube: a clinicopathologic study of 13 cases. *Am J Surg Pathol* 2006;30(7):844-9.
7. Mizuuchi H, Mori Y, Sato K, Kamiya H, Okamura N, Nasim S, et al. High incidence of point mutation in K-ras codon 12 in carcinoma of the fallopian tube. *Cancer* 1995;76(1):86-90.
8. Stewart CJ, Doherty DA, Havlat M, Koay MH, Leung YC, Naran A, et al. Transtubal spread of endometrial carcinoma: correlation of intraluminal tumour cells with tumour grade, peritoneal fluid cytology, and extra-uterine metastasis. *Pathology* 2013;45(4):382-7.
9. Fadare O, Khabele D. Salpingo-oophorectomy specimens for endometrial cancer staging: a comparative analysis of representative sampling versus whole tissue processing. *Hum Pathol* 2013;44(4):643-50.