

Occult Thyroid Papillary Microcarcinoma Arising from Bilateral Ovaries with Ovarian Teratoma: Case Report

Bilateral Ovaryan Teratomdan Gelişen Okkült Tiroid Papiller Mikrokarsinomu

Zeliha Esin ÇELİK,^a
Hacı Hasan ESEN,^b
Metin ÇAPAR^c

^aClinic of Pathology,
Bitlis State Hospital, Bitlis
Departments of

^bPathology,
^cObstetric and Gynecology,
Konya Necmettin Erbakan University
Meram Faculty of Medicine, Konya

Geliş Tarihi/Received: 14.09.2011
Kabul Tarihi/Accepted: 08.12.2011

*This case report was presented as a poster at
19th National Pathology Congress, 7-11
October 2009, Turkish Republic of
Northern Cyprus.*

Yazışma Adresi/Correspondence:
Zeliha Esin ÇELİK
Bitlis State Hospital,
Clinic of Pathology, Bitlis,
TÜRKİYE/TURKEY
dresincelik@hotmail.com

ABSTRACT Mature cystic teratomas, the most common type of ovarian teratomas are generally benign in their pure forms, but occasionally they may go malignant transformation in one of their elements. Struma ovarii, the most common type of monodermal teratomas is composed of purely or predominantly thyroid tissue and malignancy arises from 5-10% of struma ovarii. Here is the case detected as bilateral occult thyroid papillary microcarcinoma arising from right ovarian mature cystic teratoma and struma ovarii in left side. The case exhibited euthyroidism prior to surgery, and postoperative laboratory findings and thyroid ultrasonography revealed no thyroid abnormality. It had been 22 months since initial diagnosis, and no recurrence or distant metastasis had been detected yet.

Key Words: Ovarian neoplasms; teratoma; carcinoma, papillary

ÖZET Ovaryan teratomların en sık görülen tipi olan matür kistik teratomların pür formları genellikle benigndir. Fakat nadiren içerdiği elemanlarından biri maligniteye dönüşüm gösterebilir. Monodermal teratomların en sık tipi olan struma ovarii ise pür ya da baskın olarak tiroid dokusundan oluşur ve bunların %5-10'undan malignite gelişebilir. Olgumuzda; sağ overde tespit edilen matür kistik teratomdan ve sol overde saptanan struma ovariden gelişen bilateral okkült tiroid papiller mikrokarsinomu tespit edilmiştir. Olgumuz; cerrahi müdahaleden önce ötiroid olup, postoperatif laboratuvar bulguları ve tiroid ultrasonografisinde tiroide ait anormallik tespit edilmemiştir. Tanıdan bu yana 22 ay geçmiş, ancak olguda henüz lokal rekürrens ya da uzak metastaz saptanmamıştır.

Anahtar Kelimeler: Over tümörleri; teratom; karsinom, papiller

Türkiye Klinikleri J Gynecol Obst 2012;22(3):207-10

Mature cystic teratoma is the most common type of ovarian teratomas composed of adult type tissue derived from two or three embryonic layers.^{1,2} Struma ovarii is a monodermal teratoma composed either exclusively or predominantly of thyroid tissue.² Malignant transformation of ectopic thyroid tissue in an ovarian teratoma is rare.^{1,3} In the report it was aimed to present a case detected as bilateral occult thyroid papillary microcarcinoma arising from right ovarian mature cystic teratoma and struma ovarii in left side. To date, there have been several cases reported in the literature representing thyroid papillary microcarcinoma arising from mature cystic teratoma or struma ovarii; however, in the light of literature, bilateral presentation of this malignancy in both ovaries has not

yet to be encountered. According to our knowledge; this is the first case to constitute an example of this kind.

CASE REPORT

Fifty three-years-old female was admitted to the clinic with the complaint of constant abdominal pain. Abdominal ultrasonography revealed a hyperechoic mass with the diameter of 10 cms and regular contours localized in the right ovary. The ovarian mass was removed following preoperative diagnosis as endometrioma and sent to our clinic for pathologic interpretation. In macroscopic examination, it was measured to be 10x10x7 cm with gray-tan colored smooth or cystic surface and full of yellow sebaceous material and hair on its cut surface. Macroscopically, the cystic mass was diagnosed as 'mature cystic teratoma'. Multiple samples were resected from the material. In microscopic examination of these samples, thyroid tissue composed of follicles containing colloid was witnessed on the cyst wall (Figure 1). Focally, papillary proliferations lined by cuboidal or pseudostratified epithelium with characteristic overlapping ground glass nuclei including nuclear groove were detected (Figure 2). The samples taken from right ovarian cyst were diagnosed as 'mature cystic teratoma-occult papillary microcarcinoma of the thyroid tissue'. The tumor was named 'microcarcinoma', in

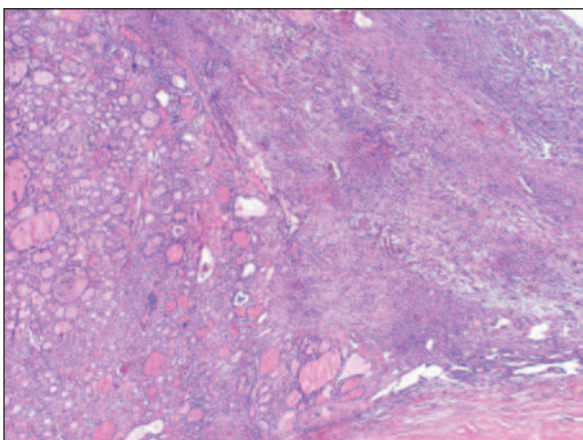


FIGURE 1: Thyroid follicles containing colloid are seen on the cyst wall of right ovary (HE, x 200).

(See for colored form <http://jinekoloji.turkiyeklinikleri.com/>)

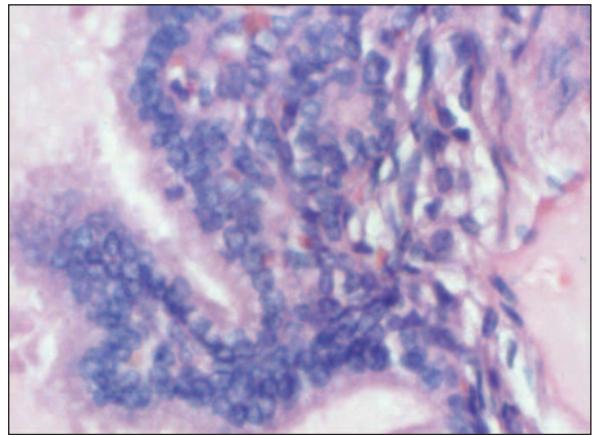


FIGURE 2: Papillary proliferations lined by cuboidal or pseudostratified epithelium with characteristic overlapping ground glass nuclei including nuclear groove are detected (Hematoxylin Eosine x 400).

(See for colored form <http://jinekoloji.turkiyeklinikleri.com/>)

that the papillary carcinoma focus was smaller than the diameter of 1 cm. Following our diagnosis, the patient underwent surgery again, and the total abdominal hysterectomy and left salpingo-oophorectomy were performed. Macroscopically, the left ovary was measured to be 3x2.5x1.7 cm. On its cut surface, brown-yellowish colored lesion presenting with cystic appearance with the diameter of 1.5 cm was detected. The samples taken from this lesion revealed the same histopathological findings with the lesion previously detected in the right ovary. But the left ovary included no other teratomatous elements of mature cystic teratoma except thyroid tissue and the size of carcinomatous focus was smaller than 1 cm (Figure 3). Hence, the diagnosis was 'malignant struma ovarii-occult papillary microcarcinoma of the thyroid tissue'. After surgical procedure, the patient was evaluated in terms of thyroid abnormalities using thyroid ultrasonography and thyroid function tests. Laboratory results including thyroid hormones were found to be within normal limits in both preoperative and postoperative periods. Thyroid ultrasonography revealed no nodules in the thyroid gland. Positron emission tomography (PET) was performed to determine whether there exists any lymph node involvement or distant metastasis. For both, the results were negative.

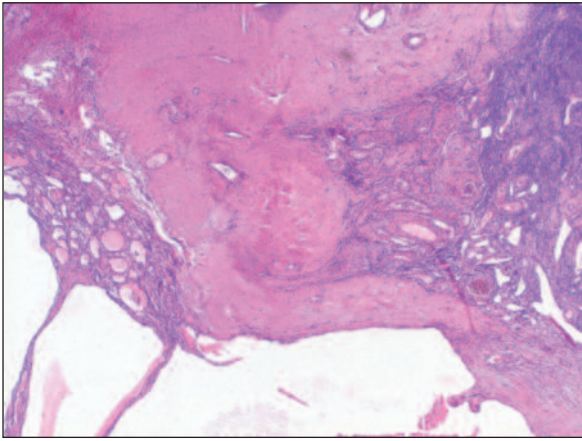


FIGURE 3: At the left side of the picture, thyroid follicles are seen on the fibrovascular stroma of left ovary (Hematoxylin Eosine x 200)
(See for colored form <http://jinekoloji.turkiyeklinikleri.com/>)

CONCLUSION

Mature cystic teratoma, the most common type of ovarian teratoma, is also the most frequent tumor originating from germ cells.^{1,4} Although most mature cystic teratomas occur during the reproductive period, 5% of them occur in postmenopausal women.^{2,4,5} Mature cystic teratomas are generally benign in their pure forms but occasionally they may go malignant transformation in one of their elements.¹ Malignancy arises from 5-10% of struma ovarii which is the most common type of monodermal teratomas.^{2,6-8} Malignant struma ovarii accounts for 0.01% of all ovarian tumors.²

The diagnostic criteria for cases of papillary carcinoma arising from mature teratoma are similar to those described in thyroid gland and based primarily on nuclear and architectural features.^{1,9} The presence of overlapping ground glass nuclei lining papillary formations is a characteristic finding.¹⁰ Vascular invasion can be detected. In the case, no vascular invasion was detected, but other typical features of thyroid papillary carcinoma were present.

Patients with malignant struma ovarii may exhibit thyroid abnormalities clinically or in laboratory findings. Clinical presentation may include hyperthyroidism or euthyroidism. Thyroid func-

tion tests may be found to be elevated, and thyroid ultrasonography may reveal a nodule in the thyroid gland.^{8,9,11} Sometimes autoimmune thyroiditis may accompany malignant struma ovarii.¹⁰ The case presented in the report was euthyroid prior to ovarian surgery, and neither abnormalities of thyroid function tests, nor nodules in the thyroid gland with ultrasonography were detected in the assessment performed after surgical removal of uterus and ovaries.

Malignant struma ovarii must be distinguished from rare instances of ovarian metastasis of papillary carcinoma originate in the thyroid gland and the less differentiated forms from other ovarian neoplasms such as clear cell adenocarcinoma and tumors with an oxyphilic appearance.⁹ In the literature, a case is reported to display metastasis from primary papillary carcinoma of the thyroid gland to bilateral ovaries. The clinical history and the absence of normal thyroid epithelium and teratomatous components could exclude a papillary thyroid carcinoma arising from struma ovarii.¹²

Malignant struma ovarii has postoperative recurrence and lymph node invasion or distant metastasis capacity. In different studies in the literature, recurrence and metastasis rates are suggested to be controversial. In a review, the recurrence with peritoneal involvement was detected in one patient out of 54 cases, but there was no distant metastasis.¹⁰ In another case report, the authors reported that the recurrence was seen 4 years after the initial diagnosis and pointed out that they had found a higher rate of metastasis than previously reported.⁸ Thus, long term, at least 10 years follow-up of patients for the detection of metastasis or tumor recurrence by serial serum thyroglobulin levels is recommended.^{7,8,11} I 131 scan, PET or computed tomography may be required in some instances.¹¹ In our case; neither distant metastasis nor lymph node involvement was detected with PET performed after the initial diagnosis. The case in our report has been disease free for 22 months now.

REFERENCES

1. Krnojelac D, Hadžić B, Curcin N, Dolai M, Bogdanović G. [Malignant transformation of thyroid tissue in an ovarian dermoid cyst: case report]. *Med Pregl* 1999;52(9-10):395-8.
2. Nogales F, Talerman A, Kubik-Huch RA, Tavassoli FA, Devouassoux-Shisheboran M. Germ cell tumors. In: Tavassoli FA, Devilee P, eds. *World Health Organization Classification of Tumors. Pathology and Genetics of Tumors of the Breast and Female Genital Organs* IARC Press: Lyon; 2003. p.168-72.
3. Onan MA, Kurdoğlu M, Güreli M, Uluoğlu Ö, Güner H. Thyroid insular carcinoma arising from ovarian dermoid cyst: case report. *Türkiye Klinikleri J Gynecol Obst* 2008;18(2): 120-5.
4. Taner Z, Barlas N, Tıraş MB, Güner H, Karabacak O, Yıldırım M. [Clinical feature and treatment modalities of mature cystic teratomas]. *Türkiye Klinikleri J Gynecol Obst* 1995;5(4):303-6.
5. Çilesiz Göksedef P, Çetin A, Tarlacı A, Ton Ö. [Immature ovarian teratoma presenting with abnormal uterine bleeding: a case report]. *Türkiye Klinikleri J Gynecol Obst* 2007;17(4): 334-6.
6. Yanık A, Üstün C, Alper T, Barış S, Altunsoy S, Çokşenim Ş. [Struma ovarii (case report)]. *Türkiye Klinikleri J Gynecol Obst* 1994;4(4): 289-90.
7. Doganay M, Gungor T, Cavkaytar S, Sirvan L, Mollamahmutoglu L. Malignant struma ovarii with a focus of papillary thyroid cancer: a case report. *Arch Gynecol Obstet* 2008;277(4):371-3.
8. Makani S, Kim W, Gaba AR. Struma Ovarii with a focus of papillary thyroid cancer: a case report and review of the literature. *Gynecol Oncol* 2004;94(3):835-9.
9. Roth LM, Miller AW 3rd, Talerman A. Typical thyroid-type carcinoma arising in struma ovarii: a report of 4 cases and review of the literature. *Int J Gynecol Pathol* 2008;27(4):496-506.
10. Devaney K, Snyder R, Norris HJ, Tavassoli FA. Proliferative and histologically malignant struma ovarii: a clinicopathologic study of 54 cases. *Int J Gynecol Pathol* 1993;12(4):333-43.
11. Hatami M, Breining D, Owers RL, Del Priore G, Goldberg GL. Malignant struma ovarii--a case report and review of the literature. *Gynecol Obstet Invest* 2008;65(2):104-7.
12. Brogioni S, Viacava P, Tomisti L, Martino E, Macchia E. A special case of bilateral ovarian metastases in a woman with papillary carcinoma of the thyroid. *Exp Clin Endocrinol Diabetes* 2007;115(6):397-400.