

Abdominal Compartment Syndrome Due to Pelvic Hematoma Which Developed After Hysterectomy: Case Report

Histerektomi Sonrası Oluşan Pelvik Hematoma Bağlı Abdominal Kompartman Sendromu

Gülşah BALIK,^a
Ahmet Fikret YÜCEL,^b
Ülkü Mete URAL,^a
Işık ÜSTÜNER,^a
Mehmet KAĞITÇI^a

Departments of
^aObstetrics and Gynecology,
^bGeneral Surgery,
Recep Tayyip Erdoğan University
Faculty of Medicine, Rize

Geliş Tarihi/Received: 26.12.2012
Kabul Tarihi/Accepted: 23.04.2013

Yazışma Adresi/Correspondence:
Gülşah BALIK
Recep Tayyip Erdoğan University
Faculty of Medicine,
Department of Obstetrics and
Gynecology, Rize,
TÜRKİYE/TURKEY
gulsahbalik@gmail.com

ABSTRACT Abdominal compartment syndrome (ACS) is defined as intraabdominal hypertension. A forty-seven-years-old patient was admitted to our outpatient clinic with complaint of vaginal bleeding. Total abdominal hysterectomy and bilateral salpingo-ooferection were performed because of myoma uteri and ovarian cyst. Low back pain, abdominal distention, wide pelvic-retroperitoneal hematoma and ileus developed and diagnosis of ACS was made on the second day after operation. Drainage of the hematoma and wide adhesiolysis were performed by laparotomy on the 3rd post-operative day. The abdomen was closed by the Bogota-bag method. The clinical and laboratory findings of the patient improved over the subsequent follow up period. The patient was discharged 15th days after the operation. As this case shows, ACS can develop after gynaecological operations and phycisians should be aware of this rare and life-threatening condition.

Key Words: Hysterectomy; intra-abdominal hypertension

ÖZET Abdominal kompartman sendromu (ACS) karın içi basıncın artması olarak tanımlanmaktadır. 47 yaşında hasta kliniğimize vajinal kanama şikayetiyle başvurdu. Myoma uteri ve over kisti sebebiyle hastaya total abdominal histerektomi ve bilateral salpingo-ooferektomi yapıldı. Operasyondan sonraki ikinci günde hastada bel ağrısı, abdominal distansiyon, yaygın pelvik-retroperitoneal hematom ve ileus gelişti ve hastaya ACS tanısı konuldu. Postoperatif 3. günde hastaya laparotomi ile geniş adezyolizis ve hematom drenajı yapıldı. Batın Bogata Bag metoduyla kapatıldı. Postoperatif takiplerinde laboratuvar ve klinik bulguları iyiye gitti. Hasta postoperatif 15. günde taburcu edildi. Bu yazıda jinekolojik operasyonlardan sonra ACS gelişebileceğini ve hekimlerin bu nadir ve hayatı tehdit edici komplikasyona karşı uyanık olmaları gerektiğini vurgulamak istiyoruz.

Anahtar Kelimeler: Histerektomi; intra-abdominal hipertansiyon

Türkiye Klinikleri J Gynecol Obst 2013;23(4):261-5

Abdominal compartment syndrome (ACS) is an impairment of blood circulation due to elevated intra abdominal pressure which results in decreased tissue perfusion and failure of organ functions.¹ The most common cause of the ACS is the accumulation of intraperitoneal fluid.²

Pelvic hematoma is a relatively common complication after abdominal hysterectomy. The use of anti coagulants before operation increases the risk of hematoma. Phycians usually consider bleeding disorders after operations, but usually neglect retroperitoneal bleeding, which is a rare complication, and can cause ACS if the treatment is delayed.^{2,3}

We present an ACS case which developed 14 hours after the diagnoses of hematoma in a patient who underwent hysterectomy and had been receiving coumadin for 3 years due to heart valve replacement surgery.

CASE REPORT

A forty-seven-year-old peri-menopausal multiparous patient was admitted to our outpatient clinic with a history of vaginal bleeding that lasted for one month. The vital signs were normal and the patient was morbidly obese (BMI: 45). Her past medical history revealed a heart valve replacement surgery 3 years previously. The patient had been put on warfarine after the surgery.

There was an incisional hernia at McBurney's point. Myoma uteri and left ovarian cysts were detected by ultrasonography. Laboratory examinations revealed elevated CA 125 level (68 U/mL), anemia (Hb 10 g/dL) and INR 2. The other laboratory findings were normal. Endometrial biopsy revealed chronic endometritis. Warfarine was replaced with heparin prior to the operation. The patient was operated on when INR fell below 1.5. Preoperative laboratory data included platelet count of 197 000, protrombin time (PT) of 95%, activated partial thromboplastin time of 35 s (normal 35-40). Renal functions were normal.

During the laparotomy, a cystic measuring about 8 cm in diameter in the left adnexa was discovered. Left salpingo-ooforectomy was performed. As frozen section-analyses of the spicemen revealed no malignancy, hysterectomy and right salpingo-ooforectomy were performed. There were common adhesions in the abdomen, therefore, an extensive adhesiolysis was performed during which the posterior rectal area (retro periton) was kept opens.

A general surgeon was invited to operation to evaluate the incisional hernia. The surgeon identified that there were large and multiple fascial defects. Additionally, there were wide adhesions between the bowels and the abdominal wall. Thus, repairing of incisional hernia was not performed and conservative measures were recommended.

The abdomen was closed after bleeding control and ensuring the hemostasis.

Post-operative vital signs were stable on the first day. Abdominal pain, vomiting, low back pain and failure of intestinal gas and gaita passage occurred on the second day. Physical examination revealed a serious abdominal distension and tympanism. The bowel sounds were hypoactive. Ecchymoses around the anus and an almost complete obstruction of the ampulla due to external compression were detected. The patient's hemoglobin was 7.5 g/dL and urine output (despite adequate fluid provision) significantly decreased. Blood pressure was 70/50 mmHg. A large amount of intra- and retro-peritoneal hematoma, dilatations in colonic segments and herniated bowel segments into the right lower quadrant were revealed by non contrast CT (Figure 1). It seemed likely that the obstructive ileus was developed due to the hematoma. The patient received 800 ml of packed red cells (PRC) and 2000 ml crystalloid solution. Intestinal passage could not be restored with a rectal tube or enema because of the compression effect of the hematoma formation. The patient was transferred to the intensive care unit. The patient was intubated and sedated since the haemodynamic and respiratory parameters worsened. Tension of the abdomen, decrease in urine output (oliguria), and abnormalities in cardiac

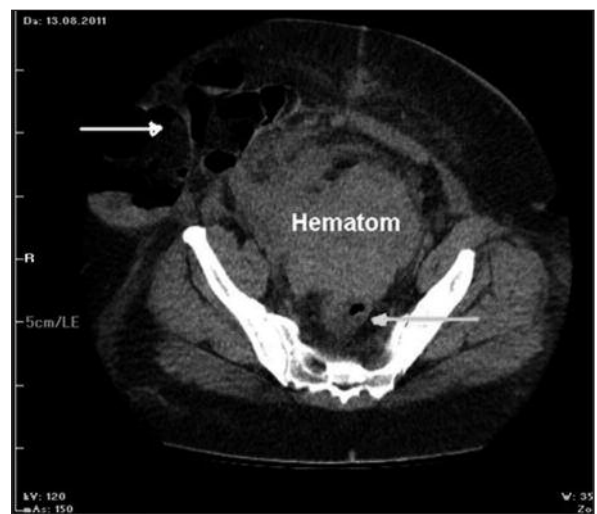


FIGURE 1: Obstruction of the sigmoid colon and rectum due to pelvic hematoma (grey arrow) and incisional hernia (white arrow). Imagine of non-contrast CT.

parameters were detected. The patient received forced positive pressure ventilation. The intra abdominal pressure measured with Foley catheter from the bladder was 25 mmHg. The patient was diagnosed as having ACS 14 hours after the diagnoses of hematoma. A second laparotomy was performed on the 3rd post-operative day. There were intra-abdominal and retro-peritoneal hematomas in the pelvic region, which were compressing the rectum and sigmoid colon, and a severe distension of intestinal loops. There was also extensive edema of the herniated bowel loops in the lower right quadrant of the abdomen. Drainage of the hematoma and wide adhesiolysis were performed during laparotomy. Despite the implementation of a rectal tube and a nasogastric tube decompression, intestinal distension failed to regress during the operation. But, there were dramatic improvements in the hemodynamic and respiratory functions as soon as the abdomen was opened. The Bogota-bag technique was applied to close the abdomen temporarily (Figure 2). The laboratory and clinical parameters significantly improved during and after operation. The progress of the abdominal compartment syndrome was prevented by this process. The hemodynamic parameters and clinical features improved by the post-operative 5th day of the re-laparotomy and the patient was operated on again to close the abdomen. Fascia reparation couldn't be performed because of the wide fascial defect. The abdomen was closed by retention sutures. The skin was sutured one by one. The patient was discharged with cure on the postoperative 15th day. No complaint was reported on the follow up. The incision was normal in the postoperative 6th month (Figure 3).

A written consent was obtained for the use of medical information of the patient to write this article.

DISCUSSION

Any patient undergoing a surgical procedure is at risk for developing complications. Abdominal distension is one of the most important postoperative complications. The physicians should consider paralytic ileus, mechanical ileus, foreign bodies, bowel

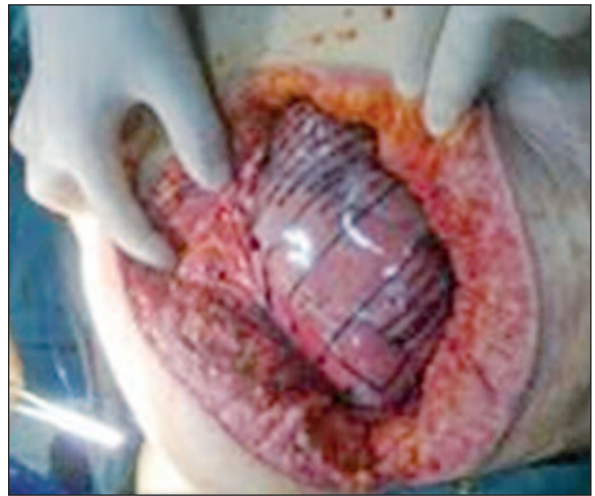

FIGURE 2: Closure of the abdomen with Bogota Bag.
(See color figure at <http://jinekoloji.turkiyeklinikleri.com/>)

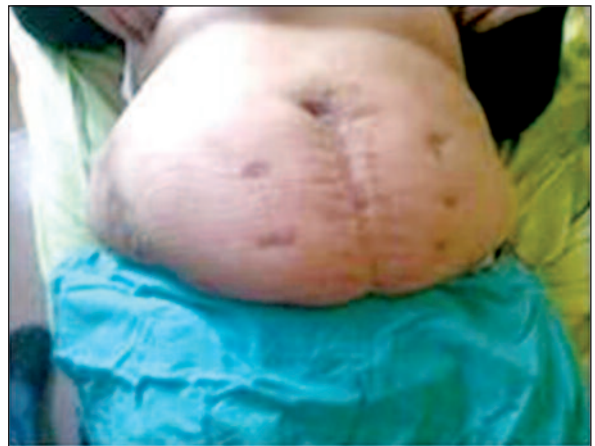

FIGURE 3: Appearance of the incision line 6 months after the operation.
(See color figure at <http://jinekoloji.turkiyeklinikleri.com/>)

perforation, hematoma, ACS and strangulation of a hernial sac for the differential diagnosis of the postoperative abdominal distension. ACS which is one of this complications is an extremely rare and highly mortal complication.

ACS is defined as intra-abdominal hypertension (IAH). The diagnosis of abdominal compartment syndrome is increasing all over the world and is often recognized in intensive care units. ACS has been defined as a continuous intra-abdominal pressure above 20 mm Hg (2.67 kPa) with coexisting organ dysfunction or failure by the World Society of the ACS.⁴ Elevation of intraabdominal pressure

results in diaphragm compression and increased intrathoracic pressure. Therefore, venous return, cardiac output and respiratory compliance decrease. The ACS mortality rate is 60% to 70%. The poor outcome relates not only to abdominal compartment syndrome itself but also to concomitant injury and hemorrhagic shock. Treatment of the shock with large-volume resuscitation may worsen abdominal compartment syndrome by causing reperfusion bowel edema.^{4,5}

There are numerous risk factors for ACS such as high body mass index, abdominal surgery, intra-abdominal bleeding, neoplasm, pancreatitis, massive ascites, and use of anti coagulants.⁴ The risk factors in our patient were morbid obesity and the use of anti-coagulant drug.

The essential first step in the management of ACS is early recognition of intra abdominal pressure (IAP). Measurement of the internal pressure of the bladder which is practical and inexpensive, is the most common technique for measuring abdominal pressure. The current gold standart technique for monitoring IAP is intra vesical technic. In this case, the internal pressure of the bladder was measured as 25 mm Hg. Nasogastric pressure transducers, inferior vena caval pressures, and direct measurement of abdominal pressure via intra-abdominal drains are the other ways of measurement of IAP.^{6,7}

Retroperitoneal hematoma is a complication with high mortality, especially in patients receiving anticoagulant therapy. Retroperitoneal hematoma is a rare complication and should be suspected in patients with hemodynamic instability, acute groin, chest, back or abdominal pain and a sudden decrease in hemoglobin levels which develop after major gynaecologic surgical interventions such as hysterectomy.⁸

Retroperitoneal hematoma is diagnosed by clinical symptoms and imaging methods such as CT. Tomography is a non-invasive, rapid and highly sensitive method for the diagnosis of hematoma.^{8,9}

Retroperitoneal hematoma may occur iatrogenically or spontaneously unrelated to surgical intervention. There are two main treatment

approaches for retroperitoneal hematoma. The first approach is to start broad-spectrum antibiotics and wait for spontaneous resolution, and the second is to provide drainage with laparotomy. Laparotomy should be done to eliminate the effect of tamponade, to control active arterial bleeding, and in the case of large hematoma.¹⁰

The treatment of spontaneous retroperitoneal hematoma involves the discontinuation of anticoagulant therapy and the provision of supportive treatment. If the general condition of the patient is not stabilized, surgical intervention may be needed. If the ACS occurs due to hematoma, the abdomen should be opened immediately and the hematoma should be evacuated.^{9,10}

The main objective in the treatment of ACS is the reduction of increased intra-abdominal pressure. There are no certain parameters to consider for surgical intervention. Therefore, clinical findings should be used to make a decision. Firstly, non-surgical approach should be preferred because a laparotomy can cause serious complications. Sedation and analgesia should be provided to decrease the intra-abdominal pressure, gastrointestinal contents should be emptied, intra-abdominal contents (blood, fluids) should be drained (paracentesis, CT-guided drainage), real positive fluid balance should be provided by diuretics and colloids. If all these methods fail, decompressive laparotomy should be done.^{11,12}

Surgical decompression in the treatment of abdominal compartment syndrome is the most effective treatment option. Intra-abdominal pressure (25 mmHg.) renal, pulmonary and hemodynamic parameters improve very quickly after decompression. But surgical decompression may lead to fluid losses, infection and ventral hernia. Decompression is a highly mortal operation because of multiorgan and acute respiratory failure, which occur in 40% of the cases.¹²

The abdomen is usually left open to ensure normal IAP after the operation. The skin closer clamps, synthetic meshes, Bogota-bag method and vacuum-assisted closure (VAC) can be used to prevent connection between the intra-abdominal or-

gans and the external environment. Although each technique has advantages and disadvantages, the VAC technique is usually recommended.^{12,13}

The Bogota-bag method is commonly used to reduce intra abdominal pressure. The abdomen is covered with a gauze pad or sterile packaging to prevent compartment syndrome. This method is cheap and easy to apply. In addition, this technique does not cause adherence, and minimizes

fluid and heat loss. The open abdomen has an associated mortality of 25%.¹⁴ No complications due to the open abdomen developed in our case.

In conclusion, surgeons should bear in mind that, when a retro-peritoneal or intra-abdominal hematoma occur due to gynaecologic surgical procedures, abdominal compartment syndrome can develop, which has high mortality and requires early diagnosis and fast intervention.

REFERENCES

1. Büyük A, Çıkman Ö, Al B, Balık A, Taysı S. Serum ceruloplasmin oxidase activity and malondialdehyde level in experimental abdominal compartment syndrome-induced rats. *Turkiye Klinikleri J Med Sci* 2010;30(2):669-73.
2. De Waele JJ, De Laet I, Kirkpatrick AW, Hoste E. Intra-abdominal Hypertension and Abdominal Compartment Syndrome. *Am J Kidney Dis* 2011;57(1):159-69.
3. von Gruenigen VE, Coleman RL, King MR, Miller DS. Abdominal compartment syndrome in gynecologic surgery. *Obstet Gynecol* 1999;94(5 Pt 2):830-2.
4. Malbrain ML, Cheatham ML, Kirkpatrick A, Sugrue M, Parr M, De Waele J, et al. Results from the International Conference of Experts on Intra-abdominal Hypertension and Abdominal Compartment Syndrome. I. Definitions. *Intensive Care Med* 2006;32(11):1722-32.
5. Buck DW 2nd, Steinberg JP, Fryer J, Dumanian GA. Operative management of massive hernias with associated distended bowel. *Am J Surg* 2010;200(2):258-64.
6. Moore AF, Hargest R, Martin M, Delicata RJ. Intra-abdominal hypertension and the abdominal compartment syndrome. *Br J Surg* 2004;91(9):1102-10.
7. Bailey J, Shapiro MJ. Abdominal compartment syndrome. *Crit Care* 2000;4(1):23-9.
8. Andrade MM, Pimenta MB, Belezia Bde F, Xavier RL, Neiva AM. Abdominal compartment syndrome due to warfarin-related retroperitoneal hematoma. *Clinics (Sao Paulo)* 2007;62(6):781-4.
9. Sagel SS, Siegel MJ, Stanley RJ, Jost RG. Detection of retroperitoneal hemorrhage by computed tomography. *AJR Am J Roentgenol* 1977;129(3):403-7.
10. Feliciano DV. Management of traumatic retroperitoneal hematoma. *Ann Surg* 1990;211(2):109-23.
11. Abu-Zidan FM, Jawas A, Boraie M, Ahmed MU. Delayed retroperitoneal bleeding causing acute abdominal compartment syndrome: case report. *Turkish Journal of Trauma & Emergency Surgery* 2011;17(2):183-5.
12. Hartshorne T, Dixon B, Woods RJ. Resolution of critical haemodynamic instability with urgent decompressive mini-laparotomy for abdominal compartment syndrome - a case report. *Crit Care* 2012;16(6):452.
13. Swan MC, Banwell PE. The open abdomen: aetiology, classification and current management strategies. *J Wound Care* 2005;14(1):7-11.
14. Gracias VH, Braslow B, Johnson J, Pryor J, Gupta R, Reilly P, et al. Abdominal compartment syndrome in the open abdomen. *Arch Surg* 2002;137(11):1298-300.