

Vesicovaginal Fistula Resulting From a Foreign Body in a Postmenopausal Woman: Case Report

Postmenopozal Bir Kadında Vajinal Yabancı Cisim Kaynaklı Vezikovajinal Fistül

Mehmet Reşit ASOĞLU,^a
İlker KAHRAMANOĞLU,^b
Selçuk SELÇUK,^a
Ateş KARATEKE^a

^aClinic of Obstetrics and Gynecology,
Zeynep Kamil Women Health and
Children's Hospital,

^bClinic of Obstetrics and Gynecology,
Suleymaniye Birth and Women Health
Training and Research Hospital, Istanbul

Geliş Tarihi/Received: 31.07.2011
Kabul Tarihi/Accepted: 02.01.2012

*This case report was presented as a poster at
29th Zeynep Kamil Gyneco-Pathology
Congress, 7-10 June 2011, Istanbul, Turkey*

Yazışma Adresi/Correspondence:
İlker KAHRAMANOĞLU
Suleymaniye Birth and Women Health
Training and Research Hospital,
Clinic of Obstetrics and Gynecology,
Istanbul,
TÜRKİYE/TURKEY
ilkerkahramanoglu@hotmail.com

ABSTRACT Vaginal foreign bodies are an extremely rare cause in vesicovaginal fistula etiology. A 56 years-old woman was admitted to our clinic complaining of chronic pelvic pain and continuous urinary leaking. Examination under anesthesia revealed a hard mass inside of the vagina. It was removed abdominally, leaving a large vesicovaginal fistula. Separate closure of the bladder and the vagina was achieved. The repair was reinforced with free omental flap between the bladder and the vagina. Vesicovaginal fistula should be considered in the evaluation of patients who experience continuous urinary leaking and/or patients who have chronic pelvic pain.

Key Words: Vesicovaginal fistula; foreign bodies; pelvic pain; surgical flaps

ÖZET Vezikovajinal fistül etiolojisinde vajinal yabancı cisimler nadir de olsa yer almaktadırlar. Kli-niğimize 56 yaşındaki hasta, kronik pelvik ağrı ve sürekli idrar sızıntısı şikayeti ile başvurdu. Anes-tezi altında yapılan muayenede vajina içerisinde sert bir kitle görüldü. Açık ameliyatla kitle çıkarılırken geniş bir vezikovajinal fistül kaldı. Mesane ve vajina sepere sütürlü kapatıldıktan sonra iki organın arasına serbest omental flep yerleştirildi. Vezikovajinal fistülün idrar sızıntısının yanı sıra kronik pelvik ağrı semptomlarına yol açabileceği dikkate alınmalı, bu tip şikayeti olan has-talarda ayırıcı tanıda vezikovajinal fistül göz önünde bulundurulmalıdır.

Anahtar Kelimeler: Vezikovajinal fistül; yabancı cisimler; pelvik ağrı; cerrahi flepler

Türkiye Klinikleri J Gynecol Obst 2012;22(4):250-3

The most common cause of all vesicovaginal fistulas (VVF) is total abdominal hysterectomy.¹ In addition; there are some rare causes such as pelvic trauma, radiation necrosis, illegal abortion, radical pelvic surgery.^{2,3} Also vaginal foreign body is an extremely rare cause in VVF etiology because vaginal foreign bodies can cause ischemic tissue necrosis due to direct pressure to the urinary tract tissue. Treatment of VVF associated with foreign bodies is difficult due to chronic inflammatory process. We report a case of VVF due to a vaginal foreign body which an abdominal approach was performed.

CASE REPORT

A 56 year-old woman with gravida 6, parity 6, was admitted to our clinic complaining of chronic pelvic pain and urinary incontinence. She had

pelvic pain for two years and urinary incontinence for eight months. The urinary leakage was continuous. A hard obstructing vaginal mass was felt in the pelvic examination and disclosed by the speculum examination (Figure 1). The mass was attached to the cervix and moving with the uterus. During the examination, continuous urine leakage from the vagina was observed. An operation was planned under general anesthesia in the lithotomy position and written informed consent was obtained. Vaginal douching with povidone-iodine was done 1 night before the surgery. The patient received intraoperative antibiotic prophylaxis with third generation cephalosporins and aminoglycosides. The mass was not able to be removed through the vagina and a laparotomy was performed with a Maylard incision. The bladder was opened after vesico-uterine peritoneum dissection, and the hard mass was seen inside of the bladder (Figure 2). Based on the patient's request, total abdominal hysterectomy and bilateral salpingo-oophorectomy were performed. Because the body was close to the ureteral orifices, a double J stent was inserted into the ureters following the mass removal (Figure 3). At the end of these procedures, a very large defect extended from the trigone to the bladder neck. The anterior and the posterior urethra were intact. The mass which was taken off, was suggested to be an aerosol cap. The fistula tract was excised circumscensibly from the living tissue margin. Closure of

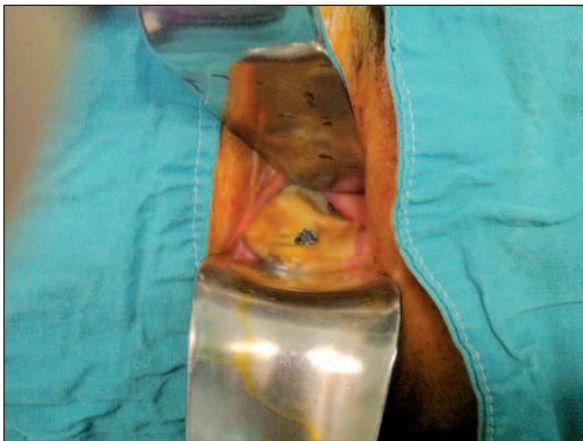

FIGURE 1: Speculum examination revealed a hard obstructing mass, the presence of which made us suspect a myositis ossificans or an advanced cancer.

(See for colored form <http://jinekoloji.turkiyeklinikleri.com/>)

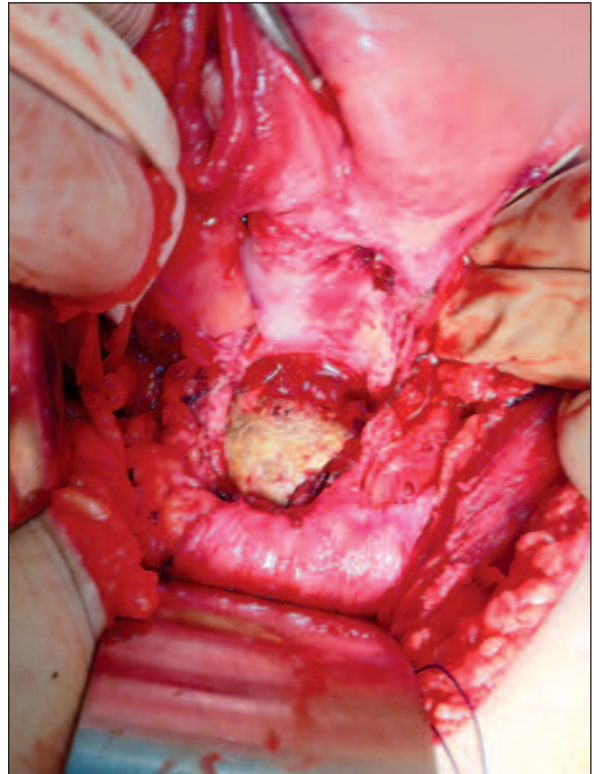


FIGURE 2: After the vesico-uterine peritoneum dissection, the bladder was opened and the hard mass was seen.

(See for colored form <http://jinekoloji.turkiyeklinikleri.com/>)

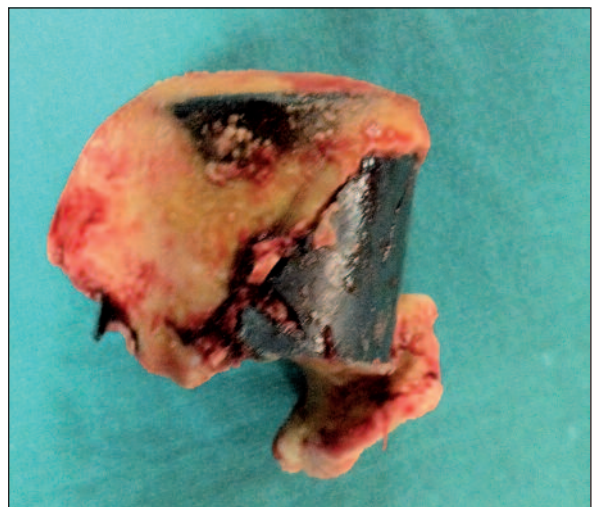

FIGURE 3: The object was approximately 3 cm in length and 4 cm in width. It is suggested that object was an aerosol cap.

(See for colored form <http://jinekoloji.turkiyeklinikleri.com/>)

the bladder mucosa and muscle layers was carried out by separate suturing with interrupted 3-0 polyglactin sutures without tension in a non-over-

lapping manner to achieve a watertight closure. The vaginal mucosa was then sutured separately with interrupted 3-0 polyglactin sutures. Separate closure of the bladder and the vagina was achieved. The repair was reinforced with free omental flap between the bladder and the vagina. Both a percutaneous suprapubic catheter (Cistofix) and a Foley's catheter were placed, so that if one became blocked the free drainage would be maintained. After fistula repair the abdomen was closed and the operation was completed. The bladder remained catheterized for 3 weeks after surgery. We used antibiotics postoperatively against gram negative bacteria and anaerobic microorganisms. After Cistofix and Foley's catheter were removed; the fistula healed, but the vagina was completely sealed. The patient was examined postoperatively after 2 months and recurrence of fistula was not observed.

DISCUSSION

There are several cases in the literature about vesico-vaginal fistula formations in relation to a vaginal foreign body. In a recent review, a series of VVFs secondary to neglected vaginal foreign bodies were presented. The most common vaginal foreign bodies found in these cases were aerosol caps. However, other objects, including hair spray caps and child's toys have been reported⁴. These patients rarely provide the true reason for the insertion of a foreign object and many times, the true history is obtained after the diagnosis of fistula. A recent report stated that in rural areas, the caps are used as a type of diaphragm for contraception purposes by some women. However it is common practice for girls to masturbate using aerosol canisters in some foreign communities.⁵ Binstock et al. also reported an aerosol cap as a cause of vesicovaginal and ureterovaginal fistula.⁶ Their patient denied any knowledge of a vaginal foreign body and also the aforementioned patient refused to give any information about how and why the foreign body was there and how long the foreign body had been there. When it was reflected upon that the patient had been single and sexually active for the last 25

years and that she hadn't remembered how long the object had been in the vagina, it was suggested, as a possibility, that she had been using the aerosol cap as a form of contraception for 25 years. When it considered, there was no finding the patient has a psychiatric or neurological disorder.

Depending on etiology, the location of fistula and the surgical expertise, VVF may be treated by different approaches.^{7,8} It is suggested that, trans-vesical approach with well vascularised tissue interposition between the vagina and bladder ought to be preferred for growing surgical successful repair rate particularly in the large fistula (>3 centimeters).⁹ The advantages of the vaginal approach are less morbidity, less blood loss and less postoperative bladder irritability. However the abdominal approach has also had reproducible and lasting success. While a limited anterior cystotomy has been applied, more morbid O'Connor procedure, in which the bladder is halved up to the level of the fistula, has been improved. In addition, a new surgical flap technique using the umbilical ligament with around fatty tissue has been described.¹⁰ Also a laparoscopic repair of a vesicovaginal fistula was presented.¹¹ In the present case, we initially tried to take the foreign body off the vagina. After the failure of this procedure, patient underwent a laparotomy.

It was believed that the vaginal foreign bodies could cause major complications that require an invasive surgical procedure if they followed a belated diagnosis.⁴ However, it is surprising in this case, although the foreign body had been in the vagina for approximately 25 years, only a diagnosis of a vesicovaginal fistula could be made, which is surprising.

In conclusion, in some communities some foreign bodies are used for contraception or to masturbate. Therefore, clinicians must be aware of these practices and on the pelvic exam, vesicovaginal fistula must be investigated. VVF may be treated by a vaginal approach, by laparoscopy or as in the aforesaid case, by an abdominal approach.

REFERENCES

1. Haferkamp A, Wagener N, Buse S, Reitz A, Pfitzenmaier J, Hallscheidt P, et al. [Vesicovaginal fistulas]. *Urologe A* 2005;44(3):270-6.
2. Vakili B, Chesson RR, Kyle BL, Shobeiri SA, Echols KT, Gist R, et al. The incidence of urinary tract injury during hysterectomy: a prospective analysis based on universal cystoscopy. *Am J Obstet Gynecol* 2005; 192(5):1599-604.
3. Lee RA, Symmonds RE, Williams TJ. Current status of genitourinary fistula. *Obstet Gynecol* 1988;72(3 Pt 1):313-9.
4. Puppo A, Naselli A, Centurioni MG. Vesicovaginal fistula caused by a vaginal foreign body in a 72-year-old woman: case report and literature review. *Int Urogynecol J Pelvic Floor Dysfunct* 2009;20(11):1387-9.
5. Fourie T, Ramphal S. Aerosol caps and vesicovaginal fistulas. *Int J Gynaecol Obstet* 2001;73(3):275-6.
6. Binstock MA, Semrad N, Dubow L, Watring W. Combined vesicovaginal-ureterovaginal fistulas associated with a vaginal foreign body. *Obstet Gynecol* 1990;76(5 Pt 2):918-21.
7. Miller EA, Webster GD. Current management of vesicovaginal fistulae. *Curr Opin Urol* 2001;11(4):417-21.
8. Karateke A, Asoğlu MR, Selçuk S, Çam C, Tuğ N, Özdemir A. Experience of our surgery in iatrogenic vesicovaginal fistulas. *J Turkish German Gynecol Assoc* 2010;11(3):137-40.
9. Çiftçi H, Savaş M, Altunkol A, Yeni E, Verit A, Verit FF, et al. [Iatrogenic vesicovaginal fistula: factors predicting success and therapy]. *J Turk Soc Obstet Gynecol* 2010;7(4):294-8.
10. Odabaş Ö, Ceylan C, Doğan S. [A new flap technique for vesicovaginal fistula repair: case report]. *Türkiye Klinikleri J Urology* 2010; 1(3):75-8.
11. Nezhat CH, Nezhat F, Nezhat C, Rottenberg H. Laparoscopic repair of a vesicovaginal fistula: a case report. *Obstet Gynecol* 1994;83(5 Pt 2):899-901.