

Incidental Diagnosed Primary Fallopian Tube Carcinoma: A Case Report

BİR OLGUDA TESADÜFEN TEŞHİS EDİLEN PRİMER FALLOP TÜPÜ KANSERİ

Hakan KARALÖK, MD,^a Ebru A. KARALÖK, MD,^a Kadir SAVAN, MD,^a Mehmet UHRİ, MD^b

Department of ^aGynecology, ^bPathology, Bakırköy Dr. Sadi Konuk Research Hospital, İSTANBUL

Abstract

Primary fallopian tube carcinoma is a rare gynecologic malignancy which is seen generally women in the fifth and sixth decades. In histologic features and behavior, it is similar to the ovarian cancer. Primary fallopian tube carcinoma was a surprise diagnosis in our patient who presented with lower abdominal pain for two months and underwent an exploratory laparotomy with a diagnosis of leiomyoma uteri. Histopathological examination revealed a papillary serous adenocarcinoma of the right fallopian tube. After surgery, an adjuvant chemotherapy was performed. The patient is alive without evidence of the disease 3 years after total abdominal hysterectomy+ bilateral salpingo-oophorectomy and adjuvant chemotherapy treatment.

Key Words: Vaginal discharge; menopause; fallopian tube neoplasms

Türkiye Klinikleri J Gynecol Obst 2007, 17:217-220

Özet

Primer fallop tüpü kanseri genellikle kadın hayatının 5-6. dekadında görülen nadir bir jinekolojik malignitedir. Histolojik yapı ve özellikleri over kanserine benzemektedir. Primer fallop tüpü kanseri tanısı; 2 aydır devam eden alt abdominal ağrı şikayeti ile kliniğimize başvurup myoma uteri tanısıyla eksploratif laparotomi yapılan olguda önceden beklemediğimiz bir tanı olarak karşımıza çıkmıştır. Histopatolojik inceleme sonucunda, sağ tubal papiller seröz adenokarsinom tanısı konulmuştur. Olguya, cerrahi tedavi sonrası adjuvan kemoterapi uygulanmıştır. Olgumuz, total abdominal histerektomi- bilateral salpingooferektomi ve adjuvan kemoterapi tedavileri sonrası kontrollerininin 3. yılında herhangi bir hastalık bulgusu olmaksızın sağlıklıdır.

Anahtar Kelimeler: Vajinal akıntı; menopoz; fallop tüpü neoplazileri

Carcinoma of the fallopian tube accounts for 0.3% of all cancers of the female genital tract.¹ It has an average annual incidence rate of 3.6 per million women per year in the United States.² The fallopian tubes are frequently involved secondarily from other primary sites, most often the ovaries, endometrium, gastrointestinal tract or breast. Primary fallopian tube carcinomas are seen most frequently in the fifth and sixth decades, with a mean age of 55 to 60 years.³ Although the etiology of this cancer is unknown, it is reported to be associated with chronic tubal

inflammation, infertility, tuberculous salpingitis and tubal endometriosis.⁴ High parity is considered to be protective.⁵ Because of its rarity and nonpresenting symptoms, primary fallopian tube carcinoma is seldom diagnosed before laparotomy. This case report describes a case of primary fallopian tube carcinoma for its rarity and presents a review of the literature.

Case Report

A 47-year-old multiparous patient, menopausal since 5 years, was admitted to our clinic with complaints of lower abdominal pain since last two months. Patient didn't have a history of postmenopausal or postcoital bleeding. Medical history was not contributory. On general physical examination, her parameters were normal. On per vaginal examination uterus was mobile and about 5 cm leiomyoma like solid mass was felt. Ultrasono-

Geliş Tarihi/Received: 20.01.2006 **Kabul Tarihi/Accepted:** 15.01.2007

Yazışma Adresi/Correspondence: Hakan KARALÖK, MD
Bakırköy Dr. Sadi Konuk Research Hospital,
Department of Gynecology, İSTANBUL
hakankaralok@yahoo.com

Copyright © 2007 by Türkiye Klinikleri

graphy showed a right sided complex, 2*3cm tubo-ovarian mass with solid and cystic components, 5*5*3 cm intramural leiomyoma of the uteri and minimal ascites in douglas (Figure 1). Ovaries could visualised normal separately. Patient was admitted to our clinic and investigated. All routine investigations including liver and renal function tests and tumor markers including CA-125 were within normal limits. Cytology detected normal cervical smear and fractional curettage showed normal endometrium. After complete pre-operative work up an exploratory laparotomy was performed. Intraoperative findings revealed leiomyoma of the uteri and dilated right fallopian tube with minimal ascites. However, both ovaries and left tube appeared to be normal. Total abdominal hysterectomy with bilateral salpingo-oophorectomy and peritoneal washing was performed. Peritoneum was visualised, to look for suspicious areas. Specimen was sent for histopathological examination. Histopathology report showed papillary adenocarcinoma of the right fallopian tube extending into the submucosa and muscularis without a penetration of the serosal surface (Figure 2). Peritoneal washing was positive (Figure 3). Thus the patient was diagnosed to be a case of primary fallopian tube carcinoma Stage IC and discharged on day 7 of surgery without any complication. Four cycles of adjuvant chemotherapy (carboplatin and paclitaxel) was performed after surgery.

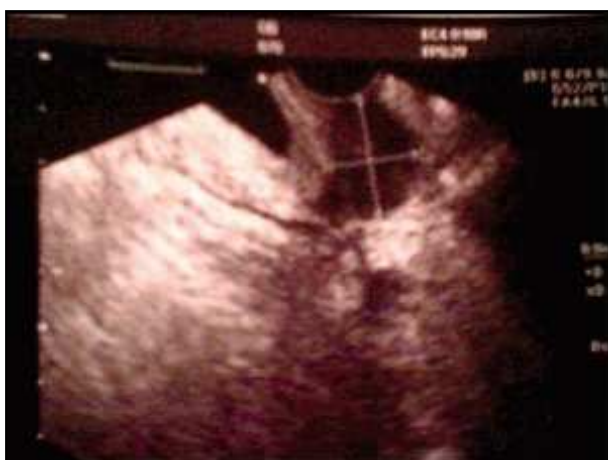

Figure 1. Right adnexial mass.

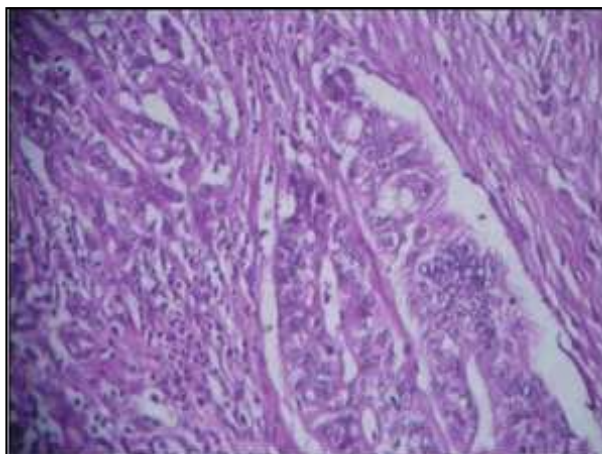


Figure 2. İnvasive stromal tubal adenocarcinoma (HE x 100).

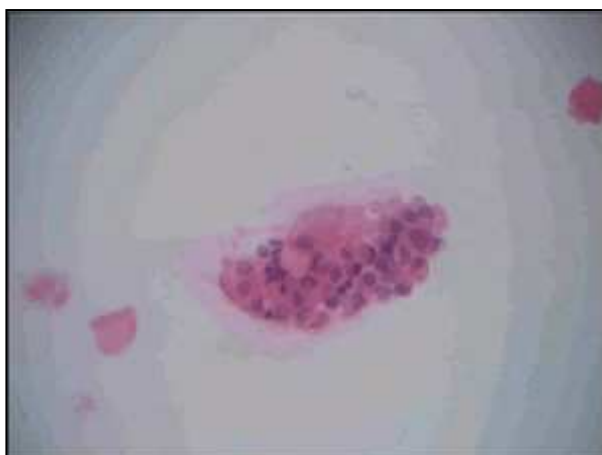

Figure 3. Atypic cells in peritoneal fluid (HE x 400).

Discussion

Approximately 80% of the malignancies of fallopian tube are from other sites, most commonly from ovary, endometrium, gastrointestinal tract or breast. Frequency of primary adenocarcinoma of fallopian tube is 0.3-0.5% according to various series and its etiology remains unknown. Fallopian tube carcinoma is asymptomatic for prolonged periods of time and found incidentally in asymptomatic women at the time of abdominal hysterectomy and bilateral salpingo-oophorectomy. A definite preoperative diagnosis of fallopian tube cancer is made only in 3% to 15% of patients and the usual clinical diagnosis is that of an ovarian tumor or pelvic inflammatory disease.⁶ The most com-

mon presentation is vaginal bleeding or discharge and is documented in more than 50% of patients followed by abdominal pain %30-49 and abdominal mass %12-61.⁷ Latzko's classic triad of symptoms and signs, consisting of a prominent watery vaginal discharge (*Hydrops tubae profluens*), pelvic pain and abdominal or pelvic mass. However, this triad is noted in fewer than 15% of patients. The sonographic appearance of fallopian tube carcinoma can be nonspecific, mimicking other pelvic diseases such as tubaovarian abscess, ovarian tumor or ectopic pregnancy.^{8,9} Serum CA-125 is used routinely as a tumor marker for diagnosis, assessing response to treatment and follow up of likely epithelial ovarian cancer. More than 90% of fallopian tube carcinoma is papillary serous adenocarcinoma, and the histologic appearance and behavior similar to ovarian serous carcinoma; thus the evaluation and treatment are also essentially the same. Tubal cancers spread in much the same manner as epithelial ovarian malignancies, principally by the transcoelomic exfoliation of cells that implant throughout the peritoneal cavity.^{10,11} Surgical principles are the same as that of ovarian cancer, surgery is also the first approach to diagnosis and involves total abdominal hysterectomy with bilateral salpingo-oophorectomy.¹² Controversy exists regarding the role of routine lymphadenectomy. Among patients with disease limited to their fallopian tubes. Peters et al.¹³ found no statistically significant improvement in survival with the addition of either pelvic irradiation or single-agent chemotherapy. The prognostic factor that directly correlates with survival is stage of the disease at the time of surgery, patient age and among patients with advanced disease, residual tumor after initial surgery.¹⁴ In a large population-based tumor registry study of 416 women with fallopian tube carcinoma, the reported 5-year relative survival rate by FIGO stage as follows: Stage I: 95%; stage II: 75%; stage III: 69% and stage IV: 45%. Almost half of those diagnosed with stage I/II disease did not undergo surgical evaluation of lymph nodes. Most women with stage I/II disease were treated with surgery alone, whereas most women with stage III/IV disease were treated with surgery and

chemotherapy. Compared with 9032 women treated for epithelial ovarian cancer during the same study period, women with fallopian tube cancer showed better survival.¹⁵

Primary fallopian tube carcinoma incidence is the rarest of all gynaecological malignancies and most patients have a delay in diagnosis and early suspicion helps to the clinicians for early diagnosis. The symptom complex of "*hydrops tubae profluens*" said to be pathognomonic for this tumour but it is rarely encountered. Similar with the literature, our case only presented with lower abdominal pain for two months without vaginal discharge. We diagnosed right fallopian tube carcinoma after an abdominal hysterectomy and bilateral salpingo-oophorectomy for leiomyoma of the uteri. On the contrary of ethiological factors which were defined before; our patient is multiparous, didn't have a history of chronic tubal inflammation, infertility or tuberculous salphingitis and her CA-125 level was in normal limits before operation. At the conclusion, primary fallopian tube carcinoma should be suspected by the clinician, even if the presenting symptoms are atypical and primary treatment must be a total surgical resection followed by an adjuvant chemotherapy.

REFERENCES

1. Panek G, Kaminska G, Zielinski J, et al. Carcinoma of the fallopian tube. Clinical analysis of 40 cases. *Ginekol Pol* 1999;70:172-8.
2. Rosenblatt KA, Weiss NS, Schwartz SM. Incidence of malignant fallopian tube tumors. *Gynecol Oncol* 1989;35:236-9.
3. Pecorelli S, Odicino F, Maisonneuve P, et al. Carcinoma of the fallopian tube. FIGO annual report on the results of treatment in gynaecological cancer. *J Epidemiol Biostat* 1998;3:363-74.
4. Demopoulos RI, Aronov R, Mesai A. Clues to the pathogenesis of fallopian tube carcinoma: a morphological and immunohistochemical case control study. *Int J Gynecol Pathol* 2001;20:128-32.
5. Riska A, Leminen A, Pukkala E. Sociodemographic determinants of incidence of primary fallopian tube carcinoma, Finland 1953-97. *Int J Cancer* 2003;104:643-5.
6. Ajithkumar TV, Minimole AL, Manju MJ, et al. Primary fallopian tube carcinoma. *Obstet Gynecol Survey* 2005;60:247-52.
7. Nordin AJ. Primary carcinoma of the fallopian tube: a 20-year literature review. *Obstet Gynecol Surv* 1994;49:349-61.

8. Ajjimakorn S, Bhamarapavati Y, Israngura N. Ultrasound appearance of fallopian tube carcinoma. *J Clin Ultrasound* 1988;16:516-8.
9. Kol S, Gal D, Friedman M, et al. Preoperative diagnosis of fallopian tube carcinoma by transvaginal sonography and CA-125. *Gynecol Oncol* 1990;37:129-31.
10. McMurray EH, Jacobs AJ, Perez CA, et al. Carcinoma of the fallopian tube. Management and sites of failure. *Cancer* 1986;58:2070-5.
11. Wolfson AH, Tralins KS, Greven KM, et al. Adenocarcinoma of the fallopian tube: results of a multi-institutional retrospective analysis of 72 patients. *Int J Radiat Oncol Biol Phys* 1998;40:71-6.
12. Takeshima N, Hasumi K. Treatment of fallopian tube cancer. Review of the literature. *Arch Gynecol Obstet* 2000;264:13-9.
13. Peters WA, Andersen WA, Hopkins MP, et al. Prognostic features of carcinoma of the fallopian tube. *Obstet Gynecol* 1988;71:757-62.
14. Gadducci A, Landoni F, Sartori E, et al. Analysis of treatment failures and survival of patients with fallopian tube carcinoma: a cooperation task force study. *Gynecol Oncol* 2001;81:150-9.
15. Kosary C, Trimble EL. Treatment and survival for women with fallopian tube carcinoma: a population-based study. *Gynecol Oncol* 2002;86:190-1.