

Early Stage Endometrial Carcinoma Arising in One Cavity of Septate Uterus: An Unusual Case

Uterin Septumun Bir Kavitesinde Ortaya Çıkan Erken Evre Endometrial Karsinom: Nadir Bir Olgu

Çağdaş TÜRKYILMAZ, MD,^a
Mehmet DOLANBAY, MD,^a
İ. Serdar SERİN, MD,^a
Cem BATUKAN, MD,^a
Mahmut Tuncay ÖZGÜN, MD^a

^aDepartment of Obstetrics and
Gynecology,
Erciyes University School of Medicine,
KAYSERİ

Geliş Tarihi/Received: 24.01.2007
Kabul Tarihi/Accepted: 19.03.2007

*It was accepted as a poster presentation
at 5th TJOD National Obstetrics and
Gynecology Congress.*

Yazışma Adresi/Correspondence:
Çağdaş TÜRKYILMAZ, MD,
Erciyes University School of Medicine,
Department of Obstetrics and
Gynecology, KAYSERİ
murselcagdas@yahoo.com

ABSTRACT Uterus septumla endometrial kanser birlikteliği çok nadir görülmektedir. Bu iki patoloji arasında herhangi bir ilişki bulunmamaktadır. Uterin anomaliler endometrium kanser tanısında gecikmeye neden olabilir. Uterin septumlu hastalarda gelişen endometrial kanserle ilişkili olarak literatürde yalnızca birkaç olgu sunumu mevcuttur. Burada, uterin septumun bir kavitesinde ortaya çıkan erken evre endometrium kanserli ilginç bir olgu sunulmuştur. Hasta postmenopozal kanama nedeniyle kliniğimize başvurdu. Transvajinal sonografi sonrası hastada uterin anomali düşünüldü. Daha sonra her iki uterin kavite dilatasyon ve küretaj ile ayrı ayrı örneklendi. Bir uterin kavite içinde endometrial karsinom tespit edilerek hastanın kesin tedavisi zamanında yapılmış oldu. Böylelikle, postmenopozal kanaması ve infertilite hikayesi olan bir hastada, uterin anomaliler tanıma göz önünde bulundurulmalı ve uterin anomali mevcut ise, tanıma gecikme olmaması için iki taraflı endometrial biopsi yapılmalıdır.

Key Words: Uterus, anormallikler, endometrial neoplazmlar

ÖZET Endometrial carcinoma together with septate uterus is seen very rarely. There is no correlation between these pathologies. Uterine anomalies can cause delayed diagnosis of endometrial carcinoma. There are only few case reports of endometrial cancer arising in patients with septate uterus in the literature. Here, we presented an interesting case of early stage endometrial carcinoma developing in one uterine cavity of septate uterus. In this case, the patient has applied to our clinic for postmenopausal bleeding. Uterine anomaly was concerned after trans-vaginal sonography. Then, two uterine cavities were sampled separately with dilatation and curettage. Endometrial carcinoma was detected in one uterine cavity and definitive treatment of this patient was performed in appropriate time. In this way, a patient who has infertility history and postmenopausal bleeding, uterine anomalies should be considered in diagnosis and if an uterine anomaly was present, bilateral endometrial biopsy would be performed in order to prevent delay in diagnosis.

Anahtar Kelimeler: Uterus, abnormalities, endometrial neoplasms

Türkiye Klinikleri J Gynecol Obst 2008, 18:61-64

Endometrial cancer is the most frequent malignancy of the female genital tract in developed countries that most occurs especially in postmenopausal women. The American Cancer Society estimated that 40.800 new cases of endometrial cancer was diagnosed in 2005.¹ At least 75% of cases present with early stage (I-II) and the majority of these patients are cured by surgery. Although the true incidence of Mullerian anomalies is unknown, the incidence of these abnormalities is 4-5% in the general population.² Other than DES exposure, the etiology of most of uterine anomalies of the female genital tract is not known. In fact, some patients may be asymp-

omatic and the diagnosis is often delayed until examination for infertility, recurrent miscarriages and preterm labor. These anomalies are detected rarely at postmenopausal period. There is no correlation between the presence of an uterine malformation and endometrial cancer risk. Incidence of endometrial cancer with uterine malformation has been never reported in the literature. In the literature, few cases reports of an endometrial carcinoma with mullerian ducts anomalies are present.³⁻⁵

In this report, we presented a rare case of early stage endometrial carcinoma developed in one uterine cavity of a septate uterus in postmenopausal women.

CASE REPORT

Fifty three year-old, nulliparous, postmenopausal woman, no taking hormone replacement therapy, who had her last menstrual period two years ago, was admitted to our clinic because of vaginal bleeding for two weeks. Infertility, diabetes mellitus, hypertension and chronic renal failure were present at the past medical history of the patient. In gynecologic examination, any suspicious mass or another pathologic sign was not detected. Whole blood counts, renal and liver functional tests and tumor markers were within normal limits. Cervical smear was also within normal limits. Transvaginal sonography identified two different uterine cavities (Figure 1). Endometrial thickness was measured as 7 and 12 mm at each one uterine cavity. Because of these findings, Mullerian anomalies including septate uterus or bicornus were concerned. Then, each uterine cavity was sampled separately with dilatation and curettage. As a result of histopathological examination well differentiated endometrioid adenocarcinoma was detected in one uterine cavity and complex endometrial hyperplasia without atypia in the other. Therefore, a median laparotomy was performed. After obtaining a peritoneal washing cytology, she underwent total abdominal hysterectomy and bilateral salpingo-oophorectomy. Examination of the removed uterus confirmed the presence of two cavities. As a result of frozen examination, nuclear grade 1, histological grade 2, well differentiated endometrioid adenocarcinoma with

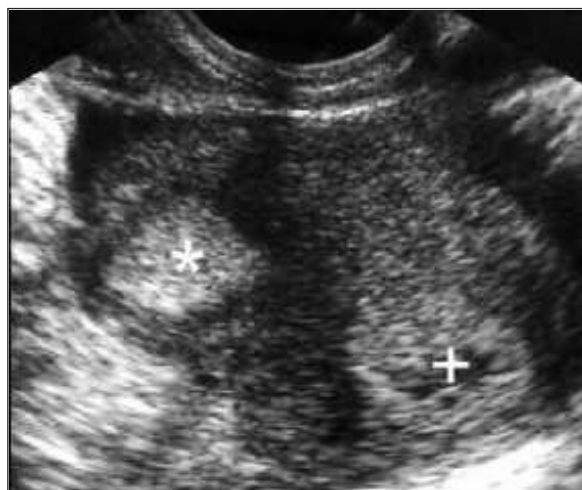


FIGURE 1: Preoperative axial sonographic scan of the uterine corpus showing two distinct endometrial linings of endometrial cancer (cross) and hyperplasia (asterisk).

limited inner half of the myometrium and without extra-uterine disease and cervical involvement was detected in the one uterine cavity (Figure 2A). Complex endometrial hyperplasia without atypia was detected in the other uterine cavity (Figure 2B). Depending on the intraoperative assessment by frozen section examination, a surgical staging which included pelvic/para-aortic lymphadenectomy was omitted. Final histological diagnosis confirmed the frozen section examination (Figure 1). Therefore, according to International Federation of Gynecologist and Obstetricians (FIGO) staging system, stage of disease was assessed as 1b. The postoperative recovery was uneventful. The patient received no adjuvant therapy and discharged on the sixth post-operative day.

DISCUSSION

Patients with endometrial cancer that is confined to uterus have a 5 year survival rate after primary surgical treatment of over 90%. Endometrial cancer commonly occurs in postmenopausal women. The predisposing factors for developing endometrial cancer consist obesity, diabetes mellitus, late menopause, infertility, anovulation, hypertension, nulliparity, PCOS, functional ovarian tumors, unopposed estrogen therapy, a family history of breast, colon and endometrial cancer, use of tamoxifen. Standard surgical management for en-

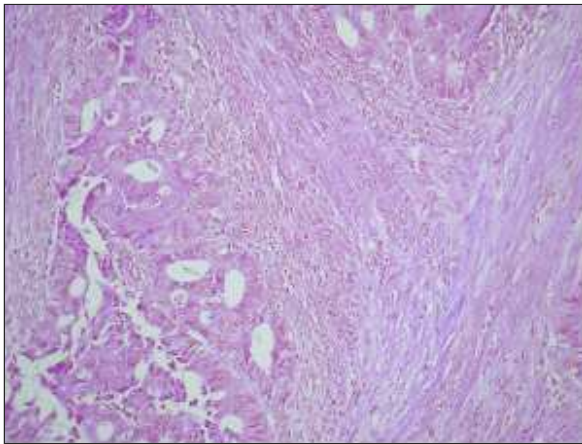


FIGURE 2A: The microscopic view of endometrioid adenocarcinoma on osinophilic layer (H.E x200).

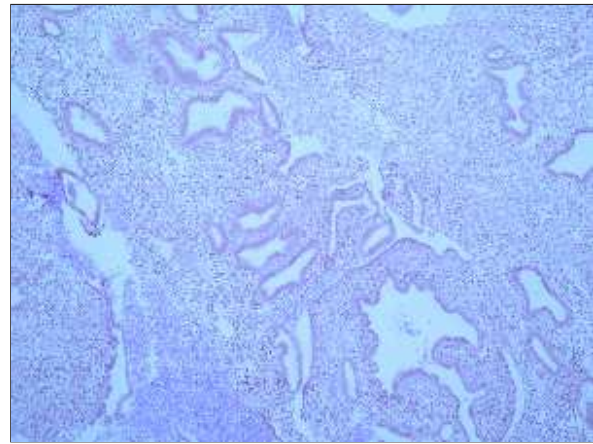


FIGURE 2B: The microscopic view of non-atypical endometrial hyperplasia on osinophilic layer (H.E x200).

endometrial adenocarcinoma is extensive staging laparotomy including a total abdominal hysterectomy and bilateral salpingo-oophorectomy with or without pelvic and para-aortic lymph node dissection.⁶ Surgical staging is important for treatment of endometrial cancer.

The incidence of uterine anomalies is 4-5% in the general population. The number of all congenital anomalies of the uterus may be higher, because some of the anomalies are asymptomatic. There are several types of anomalies which are based on the degree of Mullerian duct development and fusion. The American Society for Reproductive Medicine described a classification system of Mullerian system anomalies based on seven groups including agenesis, unicornuate uterus, uterus didelphys, bicornuate uterus, septate uterus, arcuate uterus, T-shaped uterus resulting from diethylstilbestrol exposure.⁷ Septate uterus is caused by partial lack of resorption midline septum between two Mullerian ducts that consist of two uterine cavities with a single fundus, and one cervix and vagina.

It is important to distinguish endometrial cancer from benign endometrial lesions in peri and postmenopausal women with abnormal uterine bleeding. Dilatation and curettage is gold standard method to detect endometrial pathologies. Therefore, a patient who has high risk to develop endometrial cancer in especially postmenopausal period, a detail and meticulous

assessment including transvaginal sonography and endometrial sampling should be performed. Despite there is no significant association between uterine anomaly and endometrial cancer, uterine anomalies may cause delay endometrial cancer diagnosis at early stage. Both uterine horns or cavities are needed to be sampled to determine endometrial cancer.

If a gynecologist is not aware of uterine anomaly at the time of initial examination, there is a 50% chance of obtaining a negative biopsy. In this case, uterine anomaly was suspected with transvaginal sonography, two uterine cavities were sampled separately with dilatation and curettage and then endometrial cancer was diagnosed easily in one uterine cavity by histopathologic examination of specimen. Appropriate treatment of this patient was performed timely.

The important message from this case; a patient who has abnormal uterine bleeding and high risk for endometrial cancer like infertility history, postmenopausal bleeding should be investigated carefully. Especially, a patient resistant to medical treatment with negative endometrial biopsy should be re-examined with vaginal ultrasonography and hysteroscopy for uterine anomaly because of positive endometrial cancer risk of the other horn or cavity. If an uterine anomaly is detected before endometrial sampling, each uterine cavity or horn have to sample separately for correct diagnosis of endometrial pathologies.

REFERENCES

1. Sanders R. Structural Fetal Abnormalities: The Total Picture. St Louis: Mosby; 2002.
2. Cullinan J, Nyberg D. Fetal abdominal wall defects; In: Rumack C, Wilson S, Charboneau J eds. Diagnostic ultrasound. St Louis: Mosby-Year Book; 1998. p.1161-75.
3. Angtuaco T. Fetal Anterior Abdominal Wall Defects; In: Callen P, ed. Ultrasonography in Obstetrics and Gynecology. Philadelphia: Saunders; 2000. p.507-12.
4. Craven CM, Carey JC, Ward K. Umbilical cord agenesis in limb body wall defect. Am J Med Genet 1997;71:97-105.
5. Lockwood CJ, Scioscia AL, Hobbins JC. Congenital absence of the umbilical cord resulting from maldevelopment of embryonic body folding. Am J Obstet Gynecol 1986;155:1049-51.
6. Van Allen MI, Curry C, Walden CE, Gallagher L, Patten RM. Limb-body wall complex: II. Limb and spine defects. Am J Med Genet 1987;28: 549-65.
7. Van Allen MI, Curry C, Gallagher L. Limb body wall complex: I. Pathogenesis. Am J Med Genet 1987;28:529-48.