

# The First Trimester Ultrasonographic Diagnosis of Conjoined Twins: Case Report

## Yapışık İkizlerin Birinci Trimesterde Ultrasonografik Tanısı

Selçuk SELÇUK,<sup>a</sup>  
Mehmet Reşit ASOĞLU,<sup>a</sup>  
Bilge AKSOY,<sup>a</sup>  
Semih TUĞRUL,<sup>a</sup>  
Kenan SOFUOĞLU<sup>a</sup>

<sup>a</sup>Clinic of Obstetrics and Gynecology,  
Zeynep Kamil Women and Child Health  
Training and Research Hospital, İstanbul

Geliş Tarihi/Received: 29.01.2011  
Kabul Tarihi/Accepted: 01.06.2011

Yazışma Adresi/Correspondence:  
Mehmet Reşit ASOĞLU  
Zeynep Kamil Women and Child Health  
Training and Research Hospital,  
Clinic of Obstetrics and Gynecology,  
İstanbul,  
TÜRKİYE/TURKEY  
mresitasoglu@hotmail.com

**ABSTRACT** Conjoined twins are seen extremely rare and most cases are thoracophagus. A 26-years-old woman was admitted to our prenatal diagnosis centre for first trimester screening. We detected a twin fetus with thoraco-omphalopagus that was diagnosed in the first trimester at 11 weeks gestation according to the last menstrual period and 11 weeks and 1 day of gestation according to crown-rump length via ultrasonography. The twins were fused to each other at the thoracic and abdominal regions (thoraco-omphalopagus). In conclusion, detection of the conjoined twins can be achieved by ultrasonography during first trimester screening.

**Key Words:** Pregnancy trimester, first; ultrasonography; twins, conjoined

**ÖZET** Yapışık ikizler çok nadiren görülür ve olguların çoğu torakofagustur. 26 yaşında bir hasta prenatal tanı merkezimize birinci trimester taraması için başvurdu. Son adet tarihine göre 11 hafta, ultrasonografide baş-popo uzunluğuna göre 11 hafta 1 gün torakoomfalofagus ikiz fetüsler tespit edildi. Fetüsler birbirine torasik ve abdominal bölgeden yapışık (torako-omfalofagus). Sonuç olarak, yapışık ikizlerin erken tanısı ultrasonografiyle birinci trimester taraması sırasında tespit edilebilir.

**Anahtar Kelimeler:** Gebelik trimestri, birinci; ultrasonografi; ikizler, bitişik

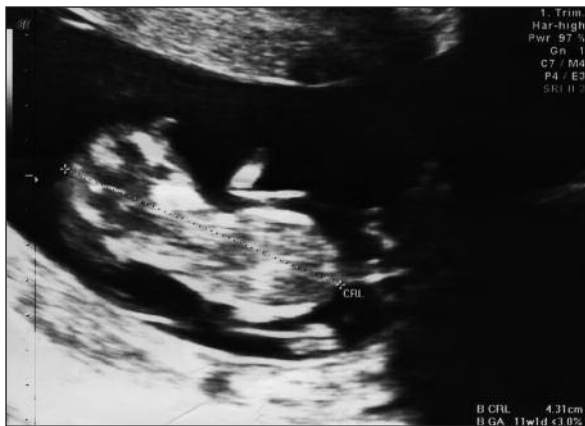**Türkiye Klinikleri J Gynecol Obst 2012;22(3):175-7**

Conjoined twins are mono chorionic and mono amniotic twins fused at any portion of the body and it results from incomplete division of the embryonic disc about 13 to 15 days after conception. The exact frequency of conjoined twins is not established but occurrence is estimated approximately 1 in 250.000 live births.<sup>1</sup> Thoraco-omphalopagus is one of the most common type of conjoined twins shared an anterior (face-to-face) connection of the upper half of the trunk and abdominal wall.<sup>2</sup> Diagnosis of conjoined twins is difficult in first trimester however the use of high-resolution ultrasound transducers has a significant role in diagnosis of conjoined twin the first-trimester.

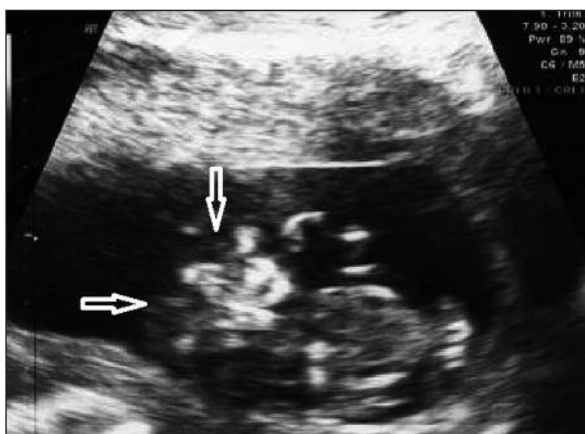
We report a case of thoraco-omphalopagus twins diagnosed in first trimester by ultrasound and confirmed postnatally.

## CASE REPORT

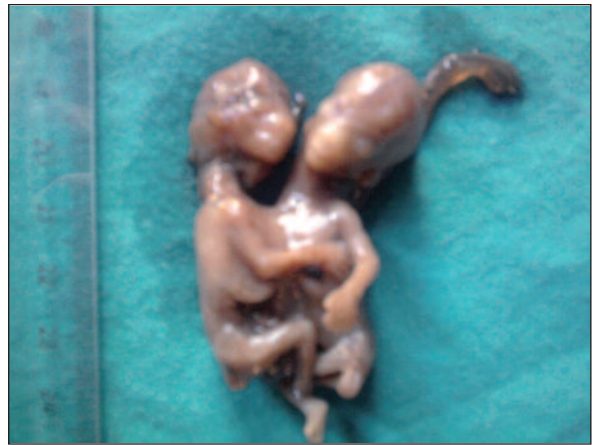A 26-years-old woman with gravida 2, parity 1, abortus 1 was admitted to our prenatal screening centre. Her pregnancy was 11 weeks according to her last menstrual period. Ultrasound was revealed an 11 weeks and 1 day old fetus according to CRL (crown rump length: 43.1 mm) (Figure 1A, B). The embryos were fused to each other at the thoracic and abdominal regions. There was two fetal heads facing each other with one trunk, abdomen, four arms and legs; the pelvises were not conjoined. Single conjoined heart was detected with color doppler ultrasonographic examination. The parents wanted to medical termination that was done by



**FIGURE 1A:** Ultrasound image of an 11 weeks and 1 day old fetus according to CRL (crown rump length: 43.1 mm).



**FIGURE 1B:** Ultrasound image of thoraco-omphalopagus twins detected at 11 gestation weeks reveals two fetal heads (arrows) with one trunk and abdomen.



**FIGURE 2:** Postnatal image of thoraco-omphalopagus twins. (See for colored form <http://jinekoloji.turkiyeklinikleri.com/>)

400 mg intravaginal misoprostol. The weight of aborted twins was 15 g and twins were joined from thorax to umbilicus (Figure 2). In postnatal examination, two fetal heads, hyperextension spines, single heart, shared liver, separated stomach and bladder, four arms and legs, single umbilical vein, three umbilical arteries were detected.

## DISCUSSION

The sonographic diagnosis of conjoined twins was first reported in 1976.<sup>3</sup> Increasing use and participation of ultrasound in the prenatal screening has resulted in an increased detection of conjoined twins in first trimester.<sup>4,5</sup> But there are some difficulties in detailed prenatal assessment of fetal anatomy such as maternal obesity, the position of the fetuses in utero and the presence of oligohydroamnios. However, ultrasound still maintains its importance and furthermore increases its place to be an important tool in prenatal diagnosis of conjoined twins through recent advances in ultrasound technology, the usage of color Doppler flow studies.

Two fetuses facing each other, hyperextension of the cervical spine, skin and mirror image body parts with limbs close together are the diagnostic ultrasound criteria for thoraco-omphalopagus conjoined twins. The presence of a single heart, liver and umbilical cord and increased size of those confirms the diagnosis.<sup>6,7</sup> In our case two fetuses fac-

ing each, fused thorax and abdominal wall with a single heart, separated pelvis were the sonographic diagnostic criteria for thoraco-omphalopagus and confirmed postnatally.

The degree of shared organs between fetuses has a major role in the prognosis of conjoined twins.<sup>8</sup> Other imaging modalities such as MRI (Magnetic resonance imaging) may provide complementary information to ultrasound and those are useful in the predicting prognosis through detection of shared organs, vascular anomalies and

other abnormalities. In our case, other imaging modalities were not used, because single heart was detected via color Doppler examination at 11 weeks gestation and parents requested medical termination after diagnosis.

In conclusion, an early diagnosis of the conjoined twins can be detected within first trimester by ultrasound scanning. As well as early diagnosing of conjoined twins, prognostic information is crucial in the management of pregnancy and appropriate counseling of the parents.

## REFERENCES

1. Kohli N. Ethical issues surrounding separation of conjoined twins. *J La State Med Soc* 2001;153(11):559-64.
2. Kaufman MH. The embryology of conjoined twins. *Childs Nerv Syst. Childs Nerv Syst* 2004;20(8-9):508-25.
3. Wilson RL, Cetrulo CL, Shaub MS. The prepartum diagnosis of conjoined twins by the use of diagnostic ultrasound. *Am J Obstet Gynecol* 1976;126(6):737.
4. Boulot P, Deschamps F, Hedon B, Laffargue F, Viala JL. Conjoined twins associated with a normal singleton: very early diagnosis and successful selective termination. *J Perinat Med* 1992;20(2):135-7.
5. Taner MZ, Kurdoglu M, Taskiran C, Kurdoglu Z, Himmetoglu O, Balci S. Early prenatal diagnosis of conjoined twins at 7 weeks and 6 days' gestation with two-dimensional Doppler ultrasound: a case report. *Cases J* 2009;2:8330.
6. Grutter F, Marguerat P, Maillard-Brignon C, De Grandi P, Pescia G. [Thoracopagus fetus. Ultrasonic diagnosis at 16 weeks]. *J Gynecol Obstet Biol Reprod (Paris)* 1989;18(3):355-9.
7. Öner G, Tayyar A, Açmaz G, Açmaz B, Tayyar M. [Cephalothoracopagus janiceps dissymmetricus with gastroschisis, a very rare form of conjoined twins: case report]. *Turkiye Klinikleri J Gynecol Obst* 2008;18(2):142-4.
8. Kingston CA, McHugh K, Kumaradevan J, Kiely EM, Spitz L. Imaging in the preoperative assessment of conjoined twins. *Radiographics* 2001;21(5):1187-208.