

Case Report (Video Article- Supplement)

Inframesenteric Retrocaval Bulky Lymph Node Excision

İlker SELÇUK^{a,b}, Zeliha FIRAT CÜYLAN^b, Caner KÖSE^b, Bülent ÖZDAL^b, Hakan YALÇIN^b

^aHacettepe University Faculty of Medicine, Department of Anatomy, Ankara, TURKEY

^bZekai Tahir Burak Women's Health Education and Research Hospital, Department of Gynecologic Oncology, Ankara, TURKEY

ABSTRACT Paraaortic lymph node zone is one of the frequent metastatic sites of endometrial cancer. During paraaortic lymphadenectomy, retrocaval (postcaval) and retroaortic (postaortic) lymph nodes are not routinely dissected. However, in case of a bulky disease, all the macroscopically pathologic nodes need to be harvested. During resection of the bulky lymph nodes; obtaining a clear cleavage between the vessel and the tumor node, and a careful dissection are extremely important for an uncomplicated surgery. At the retrocaval area care should be taken to the lumbar arteries and veins.

Keywords: Lymphadenectomy; endometrial cancer; paraaortic; surgery; anatomy

Paraaortic lymph node zone is one of the frequent metastatic sites of endometrial cancer. Paraaortic lymph node metastasis will be detected either isolated or with pelvic lymph node metastasis. Overall in 7-8% of endometrial cancer patients paraaortic lymph node metastasis is encountered and in patients with positive pelvic lymph nodes this ratio increases up to 47%. However, in patients with negative pelvic lymph nodes the risk of isolated positive paraaortic lymph nodes is 2%.^{1,2}

Inferior vena cava starts from the level of 4th lumbar vertebra and lies on the right side of abdominal aorta.³ Paraaortic lymph nodes are composed of left lumbar (lateral aortic, preaortic and postaortic), intermediate lumbar and right lumbar (lateral caval, precaval and postcaval) nodes which are located on the lateral, anterior and posterior surface of aorta and inferior vena cava between the mid-level of common iliac arteries and left renal vein.⁴ Inferior mesenteric artery originates from the abdominal aorta at the level of 3rd lumbar vertebra and the lymph nodes below the inferior mesenteric artery are clinically called inframesenteric.

During paraaortic lymphadenectomy, retrocaval (postcaval) and retroaortic (postaortic) lymph nodes are not routinely dissected. However, in case of a bulky disease, all the macroscopically pathologic nodes need to be harvested. This case report/video article demonstrates the technique, how to isolate the inferior vena cava and resect a bulky retrocaval lymph node.

Correspondence: İlker SELÇUK

Hacettepe University Faculty of Medicine, Department of Anatomy, Ankara, TURKEY

E-mail: ilkerselcukmd@hotmail.com



Peer review under responsibility of Journal of Clinical Obstetrics & Gynecology.

Received: 19 Aug 2019

Received in revised form: 22 Oct 2019

Accepted: 31 Oct 2019

Available online: 20 Nov 2019

2619-9467 / Copyright © 2020 by Türkiye Klinikleri. This is an open access article under the CC BY-NC-ND license (<http://creativecommons.org/licenses/by-nc-nd/4.0/>).

CASE REPORT

A 59 years-old woman with a preoperative endometrial biopsy result of Grade 3 endometrioid endometrial cancer admitted to the Gynecologic Oncology Clinic with the abdominal computed tomography result which indicates bulky lymph nodes at the paraaortic region.

During the laparotomy, abdominal exposure revealed tumor implants on the omentum, and bulky lymph nodes at the external iliac and obturator area bilaterally, at the inframesenteric retrocaval area and anterior surface of aorta. The patient underwent debulking surgery; total abdominal hysterectomy, bilateral salpingo-oophorectomy, total omentectomy, and bilateral pelvic and paraaortic lymphadenectomy were successfully performed.

An informed consent was taken from the patient.

INFRA-ENTERIC RETROCAVAL BULKY LYMPH NODE EXCISION: SURGICAL TECHNIQUE

1. Small bowels are kept outside the surgical field with a right cranio-lateral retraction and the mesentery of sigmoid colon is retracted caudo-laterally to the left side.

2. Entering the retroperitoneal paraaortic area by cutting the posterior parietal peritoneum with an incision beginning below the cecum and extending along the base of small bowel mesentery up to the level of ligament of Treitz (suspensory muscle of duodenum).

3. Paracaval space (lateral to inferior vena cava; between the psoas major muscle, inferior vena cava and ascending colon) is developed; ascending colon and right ureter is retracted laterally and duodenum is retracted superiorly.

4. At the level of L3-L4 vertebra; inferior vena cava is dissected from the retrocaval bulky lymph node, isolated and retracted over the bulky lymph node.

5. A cleavage is developed at the right border of inferior vena cava and the bulky lymph node is excised from the retrocaval and interaortocaval space (Figure 1).

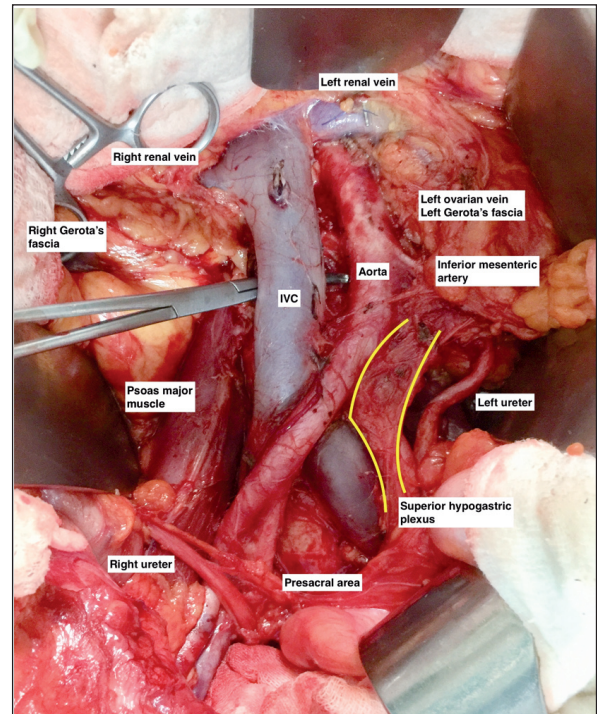


FIGURE 1: Anatomy of the paraaortic area after paraaortic lymph node dissection (IVC: Inferior vena cava).

DISCUSSION

During bulky lymph node resection, there is an increased risk of operative vessel injury. Careful dissection and isolation of the vessel will decrease the risk of an injury. In case of a laceration or bleeding, firstly compression with a hot gauze will decrease the amount of bleeding. However, especially for retrocaval and retroaortic bulky lymph nodes, control of an injury at the posterior part of the vessel is tough to manage. Hemostatic tapes located at the superior and inferior part of the lesion will enroll the vessel circumferentially and provide a control mechanism in case of a laceration on the vessel.⁵ Afterwards, the torn surface of the vessel will be sutured with monofilament and non-absorbable 4-0 sutures.

Tributaries of the inferior vena cava will easily be damaged during paraaortic lymph node excision. Possover et al. analysed the number and percentage of tributaries in 112 patients.⁶ Tributaries of the inferior vena cava are mainly found on the ventral surface and when the inferior vena cava is divided into

3 parts; level 1 from the level of right common iliac vein where it disappears under the right common iliac artery to the level of aortic bifurcation, level 2 from the aortic bifurcation to the level of inferior mesenteric artery and level 3 from the level of inferior mesenteric artery to the level of left renal vein, most of the tributaries were found at level 1. Tributaries of the anterior surface of inferior vena cava were found in 58% (65/112), 19% (22/112) and 0.9% (1/112) of patients for level 1, 2 and 3, respectively; in 21.5% (24/112) of patients no tributaries were found. Totally 237 vein tributaries were found in 112 patients; 82.3%, 17.3% and 0.4% for level 1, 2 and 3, respectively. The major tributary of inferior vena cava on the anterior surface is ‘fellow’s vein’, it supplies the dominant lymphatic pack and found at level 2.⁷

Nevertheless, lumbar vessels are the major anatomic structures found on the posterior surface of inferior vena cava and interaortocaval space. Care should be taken to the right lumbar arteries which are passing through the posterior part of inferior vena cava and also the left lumbar veins which passes posterior to the aorta through the interaortocaval area and drains into the inferior vena cava. There are totally four lumbar arteries, and all the lumbar arteries except the suprarenal one (lumbar 1) can be sacrificed during surgery.⁸

As a conclusion, during resection of the bulky lymph nodes obtaining a clear cleavage between the vessel and the tumor node, and a careful dissection are extremely important for an uncomplicated surgery.

Source of Finance

During this study, no financial or spiritual support was received neither from any pharmaceutical company that has a direct connection with the research subject, nor from a company that provides or produces medical instruments and materials which may negatively affect the evaluation process of this study.

Conflict of Interest

No conflicts of interest between the authors and / or family members of the scientific and medical committee members or members of the potential conflicts of interest, counseling, expertise, working conditions, share holding and similar situations in any firm.

Authorship Contributions

Idea/Concept: İlker Selçuk; **Design:** İlker Selçuk, Hakan Yalçın; **Control/Supervision:** Hakan Yalçın, Bülent Özdal; **Data Collection and/or Processing:** Selçuk İlker, Zeliha Fırat Cüylan; **Caner Köse;** **Analysis and/or Interpretation:** İlker Selçuk, Zeliha Fırat Cüylan, Caner Köse; **Literature Review:** İlker Selçuk, Zeliha Fırat Cüylan, Caner Köse; **Writing the Article:** İlker Selçuk; **Critical Review:** Hakan Yalçın.

REFERENCES

- AlHilli MM, Mariani A. The role of para-aortic lymphadenectomy in endometrial cancer. *Int J Clin Oncol.* 2013;18(2):193-9. [[Crossref](#)] [[PubMed](#)]
- Mariani A, Keeney GL, Aletti G, Webb MJ, Haddock MG, Podratz KC. Endometrial carcinoma: paraaortic dissemination. *Gynecol Oncol.* 2004;92(3):833-8. [[Crossref](#)] [[PubMed](#)]
- Selçuk İ, Ersak B, Tatar İ, Güngör T, Huri E. Basic clinical retroperitoneal anatomy for pelvic surgeons. *Turk J Obstet Gynecol.* 2018;15(4):259-69. [[Crossref](#)] [[PubMed](#)] [[PMC](#)]
- Federative Committee on Anatomical Terminology. *Terminologia Anatomica: International Anatomical Terminology.* 1st ed. Stuttgart: Thieme; 1998. p.292.
- Ozgul N, Basaran D, Boyraz G, Salman MC. Hemostatic control of inferior vena cava with tape traction maneuver in the presence of bulky metastatic paraaortic lymph nodes. *Gynecol Oncol.* 2015;138(2):492-3. [[Crossref](#)] [[PubMed](#)]
- Possover M, Plaul K, Krause N, Schneider A. Left-sided laparoscopic para-aortic lymphadenectomy: anatomy of the ventral tributaries of the infrarenal vena cava. *Am J Obstet Gynecol.* 1998;179(5):1295-7. [[Crossref](#)] [[PubMed](#)]
- Brand E. Fellow's vein. *Gynecol Oncol.* 1993;51(3):424. [[PubMed](#)]
- Morrow PC. *Surgical anatomy. Morrow's Gynecologic Cancer Surgery.* 2nd ed. South Coast Medical Publishing; 2012. p.105.