

# Hypoplastic Right Ventricle With Intact Ventricular Septum: A Case Report

## İNTAKT VENTRİKÜLER SEPTUMLU HİPOPLASTİK SAĞ VENTRİKÜL: OLGU SUNUMU

Sefa KELEKÇİ, MD,<sup>a</sup> Ömer KILAVUZ, MD,<sup>a</sup> Bülent YILMAZ, MD,<sup>a</sup> Atilla ÇANKAYA, MD<sup>a</sup>

<sup>a</sup>Neukolln Hospital, Department of Perinatal Diagnosis and Therapy, Berlin, GERMANY

### Abstract

Hypoplastic right ventricle that frequently occurs is a severe congenital anomaly and a neonatal emergency when ductal closure stops pulmonary flow. Its prenatal diagnosis may be impossible at early stage because of anomaly evolving in utero. The underdevelopment of the right ventricle is a consequence of the obstruction of the pulmonary outflow. Here we present a hypoplastic right ventricle with intact ventricular septum case in which its prenatal diagnosis has been done at 25 weeks of gestation of a 34 year-old and gravida two parity one pregnant woman referred to our prenatal diagnosis unit for second opinion because of abnormal four chamber view.

**Key Words:** Fetal echocardiography, hypoplastic right ventricle, prenatal diagnosis

### Özet

Hipoplastik sağ ventrikül sık meydana gelen bir ağır konjenital anomalidir ve duktal kapanıklık pulmoner kan akımını bozduğunda neonatal acil bir durumdur. Anomaliyi erken prenatal dönemde tanımlamak zordur. Sağ ventrikülün az gelişimi pulmoner akının azalmasına bağlıdır. Biz burada, anormal dört kadran görüntü saptanan G2 P1 ve 25 hf gebe bir kadının fetusunda intakt interventriküler septumu olan hipoplastik sağ kalp olgusu sunuyoruz.

**Anahtar Kelimeler:** Fetal ekokardiografi, hipoplastik sağ ventrikül, prenatal tanı

Türkiye Klinikleri J Gynecol Obst 2005, 15:325-327

**H**ypoplastic right heart syndrome is a condition characterized by underdevelopment or absence of right side of the heart resulting from varying degrees of right ventricular development. This is usually accompanied by atresia of the pulmonary or the tricuspid valve.<sup>1</sup> This condition is a severe congenital anomaly that frequently occur a neonatal emergency when ductal closure stops pulmonary flow.

Pulmonary atresia with intact ventricular septum was described over two centuries ago<sup>2</sup> and is characterized by atresia of the pulmonary valve with an intact ventricular septum. Two types of pulmonary atresia with intact ventricular septum have

been described. In type I disease, a combination of pulmonary valvular atresia, competence of the tricuspid valve, and an intact ventricular septum result in massive right ventricular hypertrophy and chamber obliteration with suprasystemic pressures. In type II disease, proximal pulmonary arterial atresia and an intact ventricular septum are present, but tricuspid incompetence allows retrograde flow of blood into the right atrium and across an atrial septal defect. Thus, in type II disease, the right ventricle is either normal or dilated.<sup>1,2</sup>

Here we present a hypoplastic right ventricle with intact ventricular septum case in which its prenatal diagnosis has been done at 25 weeks of gestation.

### Case Report

A 34 year-old, G<sub>2</sub>P<sub>1</sub> pregnant woman was referred to our prenatal diagnosis unit for second opinion because of abnormal four chamber view.

Geliş Tarihi/Received: 18.05.2005 Kabul Tarihi/Accepted: 27.10.2005

**Yazışma Adresi/Correspondence:** Sefa KELEKÇİ, MD  
Zekai Tahir Burak Women Health  
and Research Hospital, ANKARA  
sefamed@hotmail.com

Copyright © 2005 by Türkiye Klinikleri

Obstetric history was unremarkable. Biometry was consistent with 25 weeks of gestation. The targeted ultrasound demonstrated a hypoplastic right ventricle (Figure 1), intact ventricular septum, enlarged aorta (Figure 2), and non-visualization of the pulmonary outflow tract. Aside from the above mentioned cardiac findings there were no other system had anomalies. Genetic counselling with all of these findings was given to the family who decided the placental biopsy to be taken. Karyotyping was normal. They opted to terminate of pregnancy. Fetocide and second trimester abortion were performed by the way of intracardiac KCl injection. A female fetus with the Apgar scores of 0 / 0 was

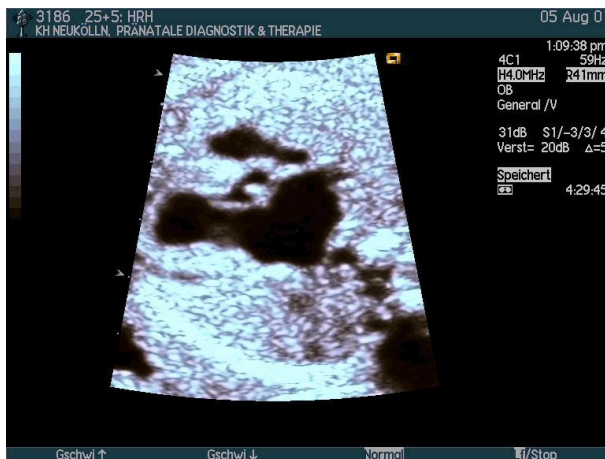

Figure 1. Hypoplastic right ventricle.

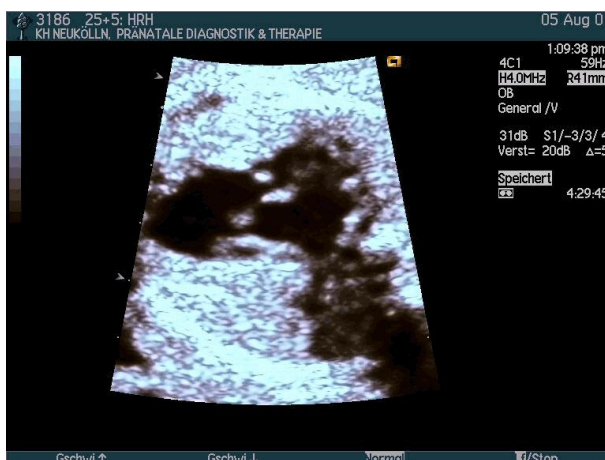

Figure 2. Enlarged aortic root.

aborted by applying misoprostol vaginally. The findings in the autopsy were compatible with pre-natal findings.

## Discussion

Atresia of the proximal pulmonary arterial circulation in the presence of an intact ventricular septum results in right ventricular pathology that is dependent upon competency of the tricuspid valve. In most cases, the tricuspid valve remains competent, which renders the right ventricle hypertrophic with an extremely small chamber volume (Type 1). Our case was type one hypoplastic right ventricle with intact ventricle septum. There was retrograde flow in ductus arteriosus in color flow mapping (Figure 3). In this type of disease pulmonary artery atresia leads to massive right ventricular hypertrophy and obliteration of the chamber.

The differential diagnosis for pulmonary atresia with intact septum is tricuspid atresia with ventricular septal defect. The distinction is quite important as extracardiac manifestations are more frequently seen with this disease. Tricuspid atresia with ventricular septal defect comprises 1-3% of congenital heart disease. Extracardiac anomalies are present in 20% of case, and there is an association with Down syndrome, asplenia, Christian's disease, and cats eye syndrome.<sup>2</sup> Occasionally hypoplastic right ventricle is associated with other congenital defects like ventricular septal defect,

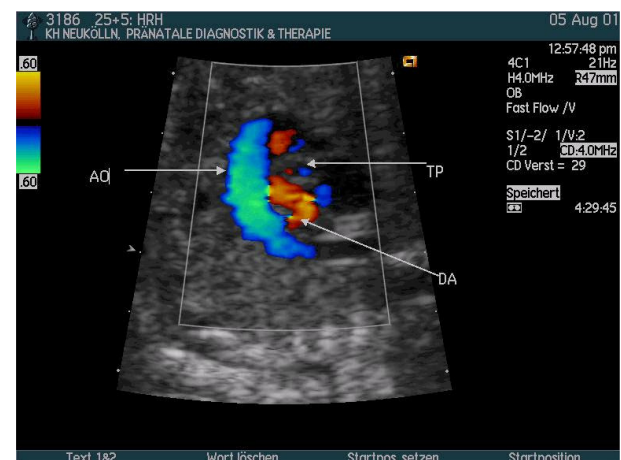


Figure 3. Retrograde flow in ductus arteriosus.

transposition of the great arteries, truncus arteriosus, and Ebstein's disease.<sup>3,4</sup> However as a rule the right ventricle in these anomalies is of normal size.

Prognosis is lethal if uncorrected. Palliative shunting between systemic and pulmonary circulation distal to point of pulmonary artery atresia is successful in some series. Prognosis has improved significantly since introduction of prostaglandin E<sub>1</sub>, for maintenance of ductal patency and sophistication of surgical repair.<sup>5</sup>

With advance of ultrasound technology, the present case demonstrates that the antenatal diagnosis of pulmonary atresia with intact septum is quite easily achieved with fetal echocardiography. The sonographic findings include absence of flow through the pulmonary valve, right ventricular hypertrophy (Type I) or dilatation (Type II), tricuspid atresia, atrial septal defect, and with retrograde flow into the ductus arteriosus.<sup>6</sup> In utero diagnosis with fetal echocardiography demands search for extracardiac malformations and chromosomal analysis as for any complex cardiac lesion. After counselling with parents, if they select to continue of pregnancy, a scheduled induction of labor, after documentation of pulmonary maturity, should be made with close consultation with neo-

natologist, pediatric cardiologist, and cardiac surgeon.

In conclusion antenatal diagnosis allows complete counselling of the patient in conjunction with the neonatologist, pediatric cardiologist, and cardiac surgeon in order to establish prognosis and plan for intensive peripartum and postpartum management of the neonate.

## REFERENCES

1. Greenwald WEI. Congenital pulmonary atresia with intact ventricular septum: Two anatomic types. *Circulation* 1956;14:945-6.
2. Marvin W, Mahoney LT. Pulmonary atresia with intact ventricular septum. *Heart Disease in Infants, Children, and Adolescents*, 4<sup>th</sup> ed. Baltimore: Williams and Wilkins, 1989. p.338.
3. de Leval M, Bull C, Stark J, Anderson RH, Taylor JF, Macartney FJ. Pulmonary atresia and intact ventricular septum: Surgical management based on a revised classification. *Circulation*. 1982;66:272-80.
4. Bull C, De Leval M, Mercanti C, Macartney FJ, Anderson RH. Pulmonary atresia and intact ventricular septum: A revised classification. *Circulation* 1982;66:266-72.
5. Freedom RM, Harrington DP. Contributions of intramyocardial sinusoids in pulmonary atresia and intact ventricular septum to a right-sided circular shunt. *Br Heart J* 1974;6:1061-5.
6. Rosenthal A, Dick M. Tricuspid atresia. *Heart Disease in Infants, Children and Adolescents*. 4<sup>th</sup> ed. Baltimore: Williams and Wilkins; 1989. p.348.