

Adnexal Torsion in a Perimenopausal Woman After Laparoscopic Hysterectomy: Case Report

Laparoskopik Histerektomi Sonrası Perimenopozal Bir Kadında İzlenen Adneksiyal Torsiyon

İlker SELÇUK,^a
Gökhan BOYRAZ,^a
İbrahim ESİNLER^a

^aDepartment of Obstetrics and Gynecology,
Hacettepe University
Faculty of Medicine, Ankara

Geliş Tarihi/Received: 07.09.2012
Kabul Tarihi/Accepted: 17.12.2012

Yazışma Adresi/Correspondence:
İlker SELÇUK
Hacettepe University
Faculty of Medicine,
Department of Obstetrics and Gynecology, Ankara,
TÜRKİYE/TURKEY.
ilkerselcukmd@gmail.com

ABSTRACT Adnexal torsion results in arterial, venous and lymphatic obstruction. Ultrasound is generally the first method to evaluate the acute pelvic and lower abdominal pain, but the findings are usually not specific. Color Doppler is an important parameter to detect the pathology. Adnexal torsion constitutes 2.7% of all gynecological emergencies and it is mostly seen in reproductive age. The risk of torsion may be lower in postmenopausal women but adnexal masses in menopausal patients are more likely to be malignant. Laparoscopy is an easy and appropriate way of exploring the adnexa with reduced morbidity rates. Patients with hysterectomy may have benefits from the ovariopexy to prevent subsequent adnexal torsion risk that usually follows such a procedure. Here we present a perimenopausal woman with chronic pelvic pain after hysterectomy.

Key Words: Hysterectomy; perimenopause; torsion abnormality

ÖZET Adneksiyal torsiyon arteriyel, venöz ve lenfatik obstrüksiyon ile sonuçlanır. Ultrason akut pelvik ve alt kadranda abdominal ağrıyı değerlendirmede başvurulan ilk yöntem olmakla birlikte, bulgular genellikle spesifik değildir. Renkli doppler ultrason patolojiyi değerlendirmede önemli bir araçtır. Adneksiyal torsiyon tüm jinekolojik acillerin %2,7'sini oluşturur ve sıklıkla reproduktif dönemde izlenir. Torsiyon riski postmenopozal kadınlarda daha düşüktür ancak postmenopozal kadınlarda izlenen adneksiyal kitleler malignite açısından daha risklidir. Laparoskopik, adneksleri değerlendirmede düşük morbidite oranları ile daha ucuz ve uygun bir metottür. Histerektomi yapılan bir hastada ovariopeksi hastanın gelecekte karşılaşılabileceği operasyonları önlemede faydalı olabilir. Biz bu yazıda perimenopozal dönemde olan bir olguda histerektomi sonrası kronik alt kadranda abdominal ağrının etyolojisini incelemek istedik.

Anahtar Kelimeler: Histerektomi; perimenopoz; torsiyon anormalliği

Türkiye Klinikleri J Gynecol Obst 2013;23(2):127-30

Adnexal torsion is partial or complete rotation of the adnexa on its axis with the vascular pedicle. That pathology may result in arterial, venous and lymphatic obstruction. The congestion of the ovary causes parenchymal haemorrhagic infarction and followed by gangrene of the ovary which leads to hemorrhagic necrosis if not diagnosed and operated on time. Ultrasound (US) is generally the first method to evaluate the acute pelvic and lower abdominal pain, but the findings are usually not specific. Color/power Doppler US is an important parameter and detects the presence or absence of the arterial and venous blood flows within the twisted pedicle.¹ But color/power Doppler findings vary and the findings may

change with the chronicity and duration of the torsion, and have limited value because of the inability to evaluate the overall tissue vascularization.²

Adnexal torsion (AT) constitutes 2.7% of all gynecological emergencies and it is mostly seen in reproductive age women.³ The risk of torsion may be lower in postmenopausal women because of the decreased incidence of benign ovarian cysts and benign teratomas. However adnexal masses in menopausal patients are more likely to be malignant and that will cause a diagnostic dilemma for the surgeon.⁴ Here we present an adnexal torsion case that occurred after laparoscopic hysterectomy in a perimenopausal woman.

CASE REPORT

A 46 year old woman who had laparoscopic hysterectomy a year ago because of myomatous uterus and menorrhagia admitted to the emergency unit with a history of chronic left pelvic pain. The symptoms had started 1 week ago and the intensity of pain had been increasing within prior 2 days. She had no nausea, vomiting, dysuria, no chest pain, no gastric pain and no dyspnea. She gave a negative past history of nephrolithiasis, bowel regulation disorder, rectal bleeding, or gastric burn. The history of the patient revealed she was in regular control for a 4 cm anechoic cyst of the left ovary. Physical examination demonstrated no fever (36,6° C) and no tachycardia (88/minute) with left lower abdominal quadrant tenderness. Her blood analysis revealed a normal white blood count (6.600/mm³) and no anemia (12.1 g/dL). Her liver function tests, creatinine level and electrolyte values were within normal limits. Pelvic ultrasonography showed a left sided pelvic mass which consisted of cystic and solid parts, the size of the mass was 81x69x 57 mm and it has only peripheral vascularization. CA 125 level was 19 IU/mL. Her urine culture was also found to be negative.

The woman was hospitalized to the gynecology department and pelvic magnetic resonance imaging was performed. The findings showed a 90x64 mm solid cystic mass with a contrast uptake to the peripheral space of the mass but there was no contrast uptake at the solid parts of the mass, so ovar-

ian torsion could not be excluded and also the suspicion of malignancy was a possibility for the woman within these findings. So we planned a diagnostic laparotomy with a preparation for possible staging procedure in case of malignancy. Intraoperative findings showed a 7 cm mass originated from the left adnexa with hemorrhagic appearance, the adnexa was turned over its pedicle and had no vasculature (Figure 1). We performed bilateral salpingoophorectomy with adhesiolysis; intraoperative frozen section pathology consulta-

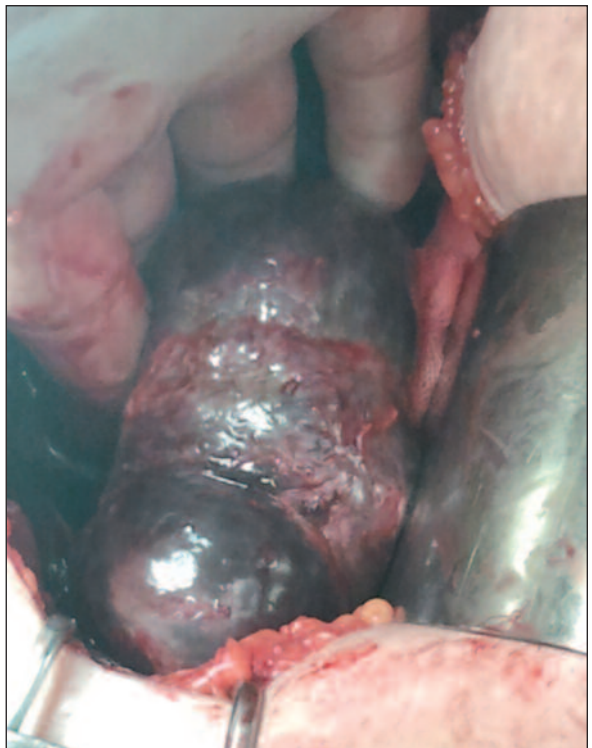
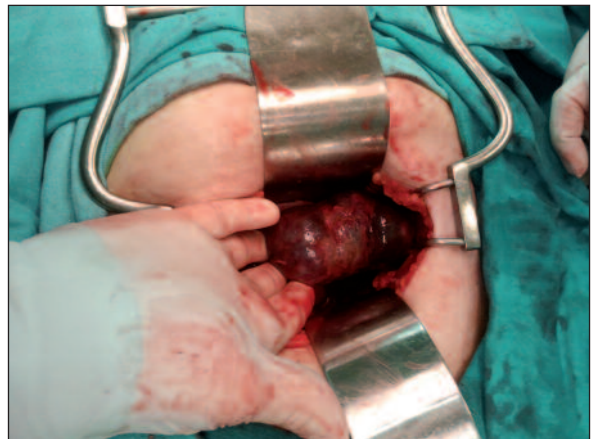

FIGURE 1: Figures show the torsed adnexa via laparotomy.
(See for colored form <http://jinekoloji.turkiyeklinikleri.com/>)

tion showed no malignancy, only blood fibrine accumulation in the left ovary with an inflammatory process was found, the right ovary was normal. The woman was discharged on the 2nd postoperative day, in good condition.

DISCUSSION

Symptoms of ovarian torsion are often nonspecific, which makes it difficult to distinguish from other causes of acute abdominal and pelvic pain. The usual presentation is sharp, localized right or left lower abdomino-pelvic pain and tenderness with a palpable pelvic mass (sometimes depends on the obesity of the patient) as well as peritoneal signs.⁵ Nausea and vomiting as well as fever could also be present. In some cases, patients experience intermittent pain, making the diagnosis even more challenging.⁵ For our patient, in this case report, there was no nausea, vomiting or fever and also the abdominal pain was not an acute finding and not affected the patient for a week and that made the diagnosis difficult.

Cystic ovarian neoplasms, such as benign mature cystic teratomas, hemorrhagic cysts, and cystadenomas commonly predispose the ovary to twist on its vascular pedicle.⁶ It is rare to see ovarian torsion from cysts smaller than 5 cm.⁷ Our patient's having a history of an anechoic cyst with a 4 cm diameter as a predisposing factor shows her exceptional situation.

Ultrasonographic findings and Doppler flow are reported to be helpful in accurate diagnosis of adnexal torsion.⁸ Absence of blood flow in the twisted pedicle and visualization of the artery alone are reported to be important issues for the diagnosis of nonviable ovary.⁹ The incidence of normal arterial and venous flow in surgically confirmed cases of adnexal torsion is high (62-75%) so the diagnosis can be difficult.¹⁰ We found only the peripheral vascularization of the ovary in our patient and noticed the change in the character of the mass.

The presentation of the patient with an adnexal mass is somehow a considering issue for the surgeon. Adnexal mass is a term of condition refers the abnormalities of either ovaries, fallopian tube, bowel, urinary system or retroperitoneum. The de-

tection rate of adnexal mass has a relation with the clinical situation of patient; in asymptomatic and symptomatic patients with a ratio of 0.17% to 5.9% and 7.1% to 12% respectively.¹¹ The risk of malignancy increases with age and especially in the post menopausal period. In reproductive years, most of the adnexal masses are benign, with a malignancy incidence 7% to 13%¹² whereas 30% of the adnexal masses in post menopausal period are malignant.¹³

It is controversial whether to perform a laparoscopy or a laparotomy for an adnexal mass. Laparoscopy is an easy and appropriate way of exploring the adnexa for these patients; with fewer thromboembolic complications, lesser post-operative pain, reduced hospitalization time and cost with reduced morbidity rates.¹⁴ The incidence and risk of malignancy for an adnexal mass must be kept in mind in postmenopausal and perimenopausal women. In a study by Eitan et al. they reviewed 19 premenopausal patients and 27 postmenopausal patients with adnexal torsion and they found no malignancy in premenopausal patients whereas 22% of postmenopausal patients had malignancy. If there is a suspicion of malignancy, a diagnostic laparotomy should be held by the choice of the surgeon.¹⁵ When ovarian cancer is suspected, frozen section analysis should be performed, and if malignancy is confirmed, staging surgery should be performed. It is still comparable whether to perform surgery by laparoscopy or laparotomy; neither of each approach has an advantage on survival rates to the other and for early stage ovarian cancer minimally invasive surgical staging has great survival rates and recurrence is not much different from laparotomy.¹⁶ But laparoscopic surgical staging has also some difficulties like the risk of intraoperative tumor rupture, port-site metastasis, dissemination of tumor and technical disability to perform the operation.¹⁷ Also there is a risk of intraoperative tumor rupture for laparotomy, the risk increases for patients operated via laparoscopy.¹⁸ Our patient was perimenopausal and had a suspicious adnexal mass for malignancy and also the technical disabilities like the risk of more adhesion formation because of the previous surgery directed us to perform an explorative laparotomy with frozen section and we found no malignancy.

Detorsion of the adnexa is an acceptable step of the treatment and should be applied to the patients without necrosis on the adnexa.¹⁹

Some authors advice ovariopexy in order to prevent recurrence of adnexal torsion in a younger patient who is not a candidate for oophorectomy. Oophoropexy is generally and importantly performed in young females given radiation therapy for Hodgkin Lenfoma to protect ovarian function for future fertility desire.²⁰ And also some other indications for ovariopexy are malformation or excessive length of the utero-ovarian ligament, torsion of a solitary adnexa or stabilization of adnexa after pelvic surgery.²¹ There are not systemic indications for ovariopexy but limiting the recurrence risk is an important etiologic reality especially in young females with an adnexal torsion or patients who had adnexectomy before. For a patient who had hysterectomy may have useful effects from the ovariopexy and in related to that procedure the pa-

tient should avoid from unnecessary interventions in the future.

CONCLUSION

The symptoms of adnexal torsion usually start suddenly but can mimic any other pathology sometimes be presenting as chronic discomfort or minimal pain. The duration of ischemia can cause irreversible damage. It may be difficult to differentiate the diagnosis of adnexal torsion from other conditions involving the lower abdomen and pelvis. Awareness and high level of suspicion in the differential diagnosis are the two diagnostic tools to prevent ovarian damage. Laparoscopic surgery is preferred for young patients who want to preserve their fertility, but postmenopausal ovarian masses presenting with symptoms of torsion should be analyzed with frozen section in case of malignancy risk. Ovariopexy for the patients with hysterectomy is a useful method and may protect the ovary against recurrent or single torsion.

REFERENCES

1. Fleischer AC, Stein SM, Cullinan JA, Warner MA. Color Doppler sonography of adnexal torsion. *J Ultrasound Med* 1995;14(7):523-8.
2. Yaman C, Ebner T, Jesacher K. Three-dimensional power Doppler in the diagnosis of ovarian torsion. *Ultrasound Obstet Gynecol* 2002; 20(5):513-5.
3. Houry D, Abbott JT. Ovarian torsion: a fifteen-year review. *Ann Emerg Med* 2001; 38(2):156-9.
4. Descargues G, Tinlot-Mauger F, Gravier A, Lemoine JP, Marpeau L. Adnexal torsion: a report on forty-five cases. *Eur J Obstet Gynecol Reprod Biol* 2001;98(1):91-6.
5. Warner MA, Fleischer AC, Edell SL, Thieme GA, Bundy AL, Kurtz AB, et al. Uterine adnexal torsion: sonographic findings. *Radiology* 1985;154(3):773-5.
6. Albayram F, Hamper UM. Ovarian and adnexal torsion: spectrum of sonographic findings with pathologic correlation. *J Ultrasound Med* 2001;20(10):1083-9.
7. Warner BW, Kuhn JC, Barr LL. Conservative management of large ovarian cysts in children: the value of serial pelvic ultrasonography. *Surgery* 1992;112(4):749-55.
8. Mazouni C, Bretelle F, Ménard JP, Blanc B, Gamerre M. [Diagnosis of adnexal torsion and predictive factors of adnexal necrosis]. *Gynecol Obstet Fertil* 2005;33(3):102-6.
9. Vijayaraghavan SB. Sonographic whirlpool sign in ovarian torsion. *J Ultrasound Med* 2004;23(12):1643-9; quiz 1650-1.
10. Peña JE, Utberg D, Cooney N, Denis AL. Usefulness of Doppler sonography in the diagnosis of ovarian torsion. *Fertil Steril* 2000;73(5):1047-50.
11. Padilla LA, Radosevich DM, Milad MP. Accuracy of the pelvic examination in detecting adnexal masses. *Obstet Gynecol* 2000;96(4):593-8.
12. Disaia PJ, Creasman WT. The adnexal mass and early ovarian cancer. *Clinical Gynecologic Oncology*. 5th ed. St. Louis: Mosby; 1997. p.253-81.
13. Kinkel K, Lu Y, Mehdizade A, Pelte MF, Hricak H. Indeterminate ovarian mass at US: incremental value of second imaging test for characterization--meta-analysis and Bayesian analysis. *Radiology* 2005;236(1):85-94.
14. Chapron C, Capella-Allouc S, Dubuisson JB. Treatment of adnexal torsion using operative laparoscopy. *Hum Reprod* 1996;11(5):998-1003.
15. Eitan R, Galoyan N, Zuckerman B, Shaya M, Shen O, Beller U. The risk of malignancy in post-menopausal women presenting with adnexal torsion. *Gynecol Oncol* 2007;106(1):211-4.
16. Iglesias DA, Ramirez PT. Role of minimally invasive surgery in staging of ovarian cancer. *Curr Treat Options Oncol* 2011;12(3):217-29.
17. Park JY, Bae J, Lim MC, Lim SY, Seo SS, Kang S, et al. Laparoscopic and laparotomic staging in stage I epithelial ovarian cancer: a comparison of feasibility and safety. *Int J Gynecol Cancer* 2008;18(6):1202-9.
18. Lécuru F, Desfeux P, Camatte S, Bissery A, Blanc B, Querleu D. Impact of initial surgical access on staging and survival of patients with stage I ovarian cancer. *Int J Gynecol Cancer* 2006;16(1):87-94.
19. Alanbay İ, Çoksüer H, Ercan M, Keskin U, Kardeşahin E, Güler AE, et al. [Laparoscopic ovariopexy in an ovarian torsion case: case report and literature review]. *Türkiye Klinikleri J Gynecol Obst* 2012;22(1):57-62.
20. Husseinzadeh N, Nahhas WA, Velkley DE, Whitney CW, Mortel R. The preservation of ovarian function in young women undergoing pelvic radiation therapy. *Gynecol Oncol* 1984; 18(3):373-9.
21. Jardon K, Bothschorisvili R, Rabischong B, Rivoire C, Nohuz E, Houille C, et al. [How I perform... an ovariopexy after adnexal torsion]. *Gynecol Obstet Fertil* 2006;34(6):529-30.