

Vulvar Papillary Hidradenoma Imitating Bartholin's Cyst: Case Report

Bartolin Kist Kliniğini Taklit Eden Vulvar Papiller Hidradenom Olgusu

Rahime BEDİR FINDIK, MD,^a
Nurcihan K. HAŞÇELİK, MD,^a
Servet GÜREŞÇİ, MD,^b
Eda AYARCAN, MD^a

Departments of
^aObstetrics and Gynecology,
^bPathology,
Keçiören Education and
Research Hospital, Ankara

Geliş Tarihi/Received: 28.02.2010
Kabul Tarihi/Accepted: 06.07.2010

Yazışma Adresi/Correspondence:
Rahime BEDİR FINDIK, MD
Keçiören Education and
Research Hospital,
Department of
Obstetrics and Gynecology,
Ankara,
TÜRKİYE/TURKEY
drbedir75@yahoo.com

ABSTRACT Papillary hidradenoma is a rare, benign, cystic, papillary tumor, generally occurring by the differentiation of eccrine, apocrine but more frequently apocrine glands within the female genital region. On the other hand, Bartholin's cyst occurs by the partial or complete obstruction of the Bartholin's channels. Occasionally, those conditions can be clinically mixed with each other. We reported a 43-years-old female patient with a vulvar lesion that seems to be a Bartholin's cyst. We realized papillary like processes on this lesion during cystectomy operation and histopathological exam revealed a papillary hidradenoma. Our aim is to point out that a tumoral lesion like papillary cystadenoma can be found within a vulvar lesion being as a similar clinic and appearance of Bartholin's cyst. This situation is important for the approach to vulvar lesions in clinical practice.

Key Words: Vulva; adenoma, sweat gland; cysts

ÖZET Papiller hidradenom, genellikle kadın genital bölgedeki ekrin, apokrin ve daha çok apokrin glandların differansiasyonuyla oluşan, yaygın olmayan, benign, kistik, papiller bir tümördür. Bartolin kist ise, bartolin kanallarının tamamen veya kısmen obstrüksiyonu sonucu gelişir. Nadir de olsa bu iki durum klinik görüntü olarak karıştırılabilir. Olgumuz 43 yaşında bartolin kist görünümünde vulvar lezyonu olan bir kadındı. Lezyona uygulanan kistektomi operasyonu sırasında papiller oluşumlar tespit ettik ve histopatolojik incelemesi papiller hidradenom şeklinde geldi. Amacımız bartolin kist kliniği ve görüntüsünde olan vulvar lezyonun altından papiller hidradenom gibi tümöral bir lezyon çıkabileceğini vurgulamaktır. Bu durum klinik pratikte vulvar lezyonlara yaklaşım açısından önemlidir.

Anahtar Kelimeler: Vulva; adenom, ter bezi; kistler

Türkiye Klinikleri J Gynecol Obst 2010;20(6):415-7

Papillary hidradenoma is rare, benign cystic and papillary tumor, It develops through the differentiation of eccrine, and mostly apocrine glands. Bartholin's cyst develops by complete of partial obstruction of bartholin's glands. Our case had the apperance of a bartholin's cyst in examination before surgical intervention. During cystectomy, papillary structures were present in the cyst and pathology result was papillary hidradenoma. Our aim is to emphasize the fact that under a vulvar lesion which looks like bartholin's cyst, a tumoral lesion such as papillary hidradenoma.

CASE REPORT

A patient at the age of 43 referred with the complaint of painless swelling in right labia minora. In physical examination, a 2 cm mass consistent with a Bartholin's cyst was seen in the lower region of right labia minora. During cystectomy, yellow-tan formations were seen in the cyst. Cystectomy was carried out and material was sent to pathological examination. Specimen's pathological examination revealed a well circumscribed nodular lesion composed of papillary and adenomatous structures under low magnification. On high magnification the double layered epithelium did not contain any of the malignancy criteria. By these findings papillary hidradenoma was diagnosed (Figure 1).

DISCUSSION

Papillary hidradenoma is a tumoral formation, which is usually derived from the apocrine gland between labia majora and labia minora in vulvar anogenital region and grows slowly, is small (2 mm-3 cm) and may be cystic as well. In the study of Woodworth et al it was established that 38% of papillary hidradenomas originate from labia majora and 26% from labia minora.¹ As papillary hidradenoma includes mixed characteristics of both eccrine and apocrine glands, it may have cystic or abscess appearance in relation to drainage problem. It may even be confused with the recurrent cyst and abscess of anogenital region Bartholin's abscess may be in cystic, abscess, or epidermal inclusion cyst form. As seen in the study of Salvatore Docimo Jr et al papillary hidradenoma may gain the appearance of Bartholin's cyst or abscess by obstructing Bartholin's ductus.² Papillary hy-

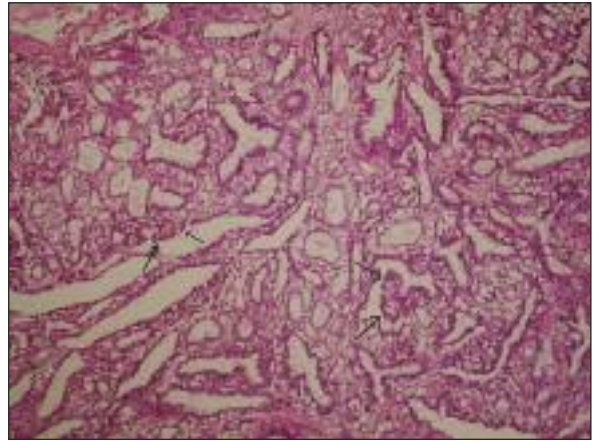


FIGURE 1: Well circumscribed nodular tumor composed of arborizing trabecular papillae. Glandular structures vary in size and are lined by double layer of cuboidal cells, the outer layer representing myoepithelial cells (HE, x200).

draadenoma tends to occur between the ages of 30-70 and is especially frequent in fourth decade. It is benign tumor but its malignant transformation into adenocarcinoma or adenosquamous cancer is reported even if rarely.³⁻⁷ Since the probability of the transformation of Bartholin's cyst into Bartholin's gland cancer is low, it may be thought that surgical total excision is not necessary.^{8,9} However, if papillary hidradenoma appearing like Bartholin's or the concurrence of Bartholin's cyst and papillary hidradenoma is considered, the necessity of surgical total excision in the presence of these lesions is seen. In conclusion, in the patient group over 40 with benign lesions such as Bartholin's cyst or abscess, the possibility of Bartholin's cyst or abscess, papillary hidradenoma even adenocarcinoma should be borne in mind and if possible, total excision should be preferred in this patient group.¹⁰

REFERENCES

1. Eckert LO, Lentz GM. Infections of Bartholin's glands section of infections of the lower genital tract. In: Katz VL, Lentz GM, eds. *Comprehensive Gynecology*. 5th ed. Philadelphia: Mosby Elsevier; 2007. p.571-3.
2. Docimo S Jr, Shon W, Elkowitz DE. Bartholin's abscess arising within hidradenoma papilliferum of the vulva: a case report. *Cases J* 2008;1(1):282.
3. Veraldi S, Schianchi-Veraldi R, Marini D. Hidradenoma papilliferum of the vulva: report of a case characterized by unusual clinical behavior. *J Dermatol Surg Oncol* 1990;16(7): 674-6.
4. Hashimoto K, Lever WF. Tumors of skin appendages. In: Freedberg IM, Eisen AZ, Wolff K, eds *Fitzpatrick's Dermatology in General Medicine*. 5th ed. New York: McGraw-Hill; 1999. p.900-2.
5. Elder D, Elenitsas R, Ragsdale BD. Tumors of the epidermal appendages. In: Elder D, Elenitsas R, Jaworsky C, eds. *Lever's Histopathology of the Skin*. 8th ed. Philadelphia: Lippincott-Raven; 1997. p.770-1.
6. Goette DK. Hidradenoma papilliferum. *J Am Acad Dermatol* 1988;19(6):133-5.
7. Stefanato CM, Finn R, Bhawan J. Extramammary Paget disease with underlying hidradenoma papilliferum: guilt by association? *Am J Dermatopathol* 2000;22(5):439-42.
8. Visco AG, Del Priore G. Postmenopausal Bartholin gland enlargement: a hospital-based cancer risk assessment. *Obstet Gynecol* 1996;87(2):286-90.
9. Kutlar İ, Erkaya S, Koşan İ. [The treatment of Bartholin's cyst and abscess with silver nitrat]. *Türkiye Klinikleri J Gynecol Obst* 1999;9(4): 263-5.
10. Omole F, Simmons BJ, Hacker Y. Management of Bartholin's duct cyst and gland abscess. *Am Fam Physician* 2003;68(1):135-40.