






## Comparison of the Immunohistochemical Staining of Lumican in Endometrioid-Type Endometrial Cancer and Endometrial Intraepithelial Neoplasias

 Hülya AYIK AYDIN<sup>a</sup>,  
 Zeynep BAYRAMOĞLU<sup>b</sup>,  
 Gülgün ERDOĞAN<sup>b</sup>,  
 Elif PEŞTERELİ<sup>b</sup>,  
 Tayup ŞİMŞEK<sup>a</sup>

Departments of

<sup>a</sup>Gynecologic Oncology,

<sup>b</sup>Pathology,

Akdeniz University Faculty of Medicine,  
Antalya, TURKEY

*Received:* 21.01.2019

*Received in revised form:* 20.03.2019

*Accepted:* 09.04.2019

*Available online:* 29.04.2019

*Correspondence:*

Hülya AYIK AYDIN

Akdeniz University Faculty of Medicine,

Department of Gynecologic Oncology,

Antalya, TURKEY

hulya\_ayik@hotmail.com

**ABSTRACT Objective:** This study aimed to evaluate the significance and correlation of immunohistochemical staining of lumican, an extracellular matrix proteoglycan, with the clinicopathological parameters in endometrial intraepithelial neoplasia (EIN) and endometrioid-type endometrial cancer (ETEC). **Material and Methods:** This cross-sectional study was carried out together in the obstetrics & gynecology and pathology departments of a tertiary care center. A total of 46 patients with EIN (n=19; 41.3%) and ETEC (n=27; 58.7%) were recruited for the study. Sections prepared from hysterectomy specimens of the patients were immunohistochemically processed and examined for immunohistochemical staining of lumican. The positive association between immunohistochemical staining of lumican and its relationship with clinicopathological variables were then investigated. **Results:** Lumican staining was more prominent in specimens obtained from ETEC patients as compared to that obtained from patients with EIN. The patients in the ETEC group were significantly elder than those in the EIN group. No statistically significant association was found between the lumican positivity and the histopathological parameters including grade; stage; squamous differentiation; lymph node metastases; myometrial, cervical, adnexial or omental invasion; and pelvic or paraaortic lymph node involvement. **Conclusion:** The study concluded that elucidation of the molecular basis underlying endometrial cancer may allow the recognition of novel molecular targets for diagnostic and therapeutic strategies of cancers of the endometrium. However, the importance of immunohistochemical staining and clinicopathological significance of lumican in endometrial cancer needs to be further studied by multicentric studies in larger numbers.

**Keywords:** Endometrial intraepithelial neoplasia; endometrioid-type endometrial cancer; lumican

Endometrial cancer (EC) is the most frequent type of gynecologic malignant tumors, and almost 40,000 new cases are diagnosed every year.<sup>1</sup> While the majority of EC's are sporadic, about 10% of these cases are hereditary.<sup>2</sup> The elucidation of the molecular events that trigger the development of EC has guided the development of novel treatment modalities for cancer. The possible new therapeutics involves medications that influence processes like apoptosis, signal transduction, degradation and folding of proteins, cell cycle progression, hormone receptors, and neovascularization. The research on these novel therapeutic agents, as single entities as well as in the form of adjunctive measures for the management of EC, is in progress.<sup>3</sup>

The components of extracellular matrix play critical roles in tumor formation and progression since these molecules participate in tumor-stroma interactions. Lumican is a small leucine-rich repeat proteoglycan which is composed of keratocan, mimecan, decorin, fibromodulin, biglycan, and pro-

line arginine-rich end leucine-rich protein (PRELP).<sup>3</sup> During carcinogenesis, the expansion of the extracellular matrix occurs together with the stimulation of stromal cells in neoplasm, which is subsequently followed by the proliferation of fibroblasts, lymphocytes, macrophages, and vessels. The interaction between tumor cells and tumor stroma produces growth signals, which in turn elicits remodeling of extracellular matrix, while also necessitates sustainable oxygen and nutrient flow.

In recent years, a new pathological nomenclature of the Endometrial Intraepithelial Neoplasia (EIN) has emerged as an alternative for the World Health Organization (WHO) 1994 classification of endometrial hyperplasia.<sup>4</sup> There is growing evidence that the diagnosis of EIN, as compared to endometrial hyperplasia, is a better predictor of progression to endometrial carcinoma.

In this context, the transition from EIN to endometrioid-type endometrial cancer (ETEC) is a key step. An understanding of the underlying molecular pathogenesis may unlock new horizons for the prevention, diagnosis, and treatment of ECs. Thus, an investigation of novel biomarkers, to detect early molecular changes leading to ETEC would prove to be useful in this perspective. The objective of this study was to assess the significance and correlation of immunohistochemical staining of lumican with the clinicopathological parameters in EIN and ETEC.

## MATERIAL AND METHODS

### STUDY DESIGN

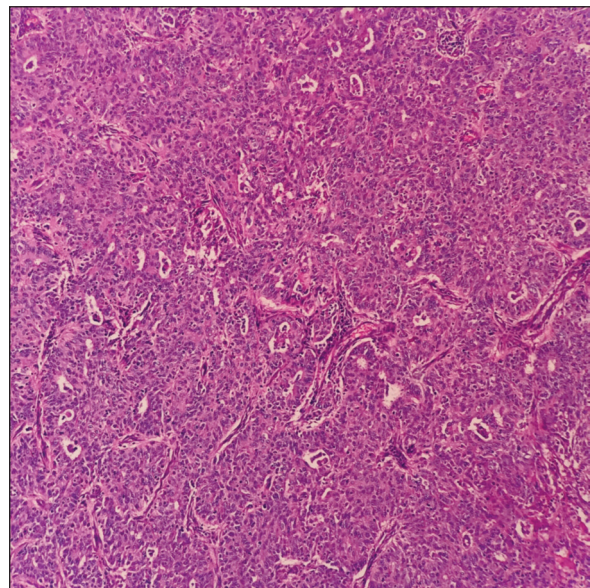
This cross-sectional study was carried out together in the obstetrics & gynecology and, pathology departments of a tertiary care center. A total of 46 patients with EIN (n=19; 41.3%) and ETEC (n=27; 58.7%) were included in this study. Histopathological sections were prepared from the specimens obtained after hysterectomy. These sections were then subjected to immunohistochemical staining and staining of lumican was then examined. Approval from the local institutional review board was obtained prior to the study (269/11.04.2018). The study was performed in accordance with the principles of the Helsinki Declaration, 2008. The

level of immunohistochemical staining of lumican and its association with clinicopathological variables in ETEC were investigated.

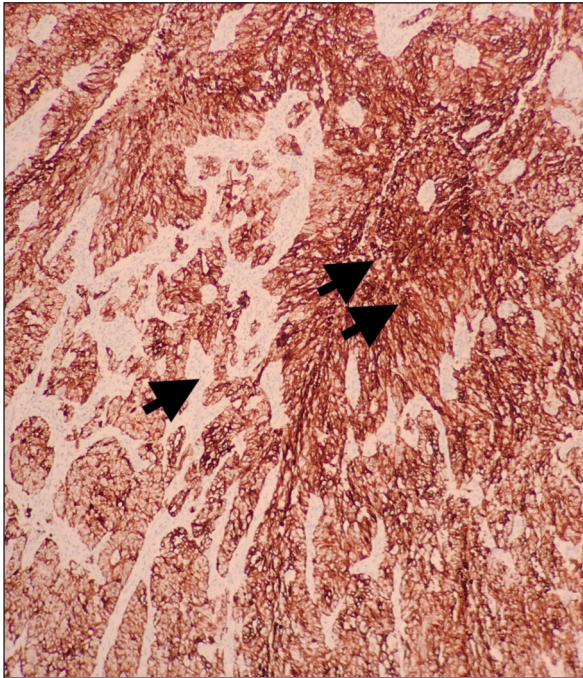
### IMMUNOHISTOCHEMISTRY

The sections were fixed in formalin before immunohistochemical analysis. The prepared sections were 4-5 µm-thick and were embedded in paraffin. Automatic staining was performed (*BondmaX, Menarini, Florence, Italy*), as described in the most relevant literature.<sup>5-7</sup> The Bond Polymer Refine Detection kit (*Leica Microsystem, Wetzlar, Germany*), with the anti-lumican antibody (*polyclonal; Novus Biologicals, Littleton, USA; working dilution 1:100, 25 min, citrate buffer*) was utilized for this purpose. The sections were lightly counter-stained using hematoxylin. Immunohistochemical staining of lumican was assessed by a pathologist who was blinded to the clinical information. Initially, the immunohistochemical staining of lumican was evaluated in normal endometrial tissues, in order to determine its routine localization and intensity. The immunohistochemical staining of lumican was classified either as positive or negative.

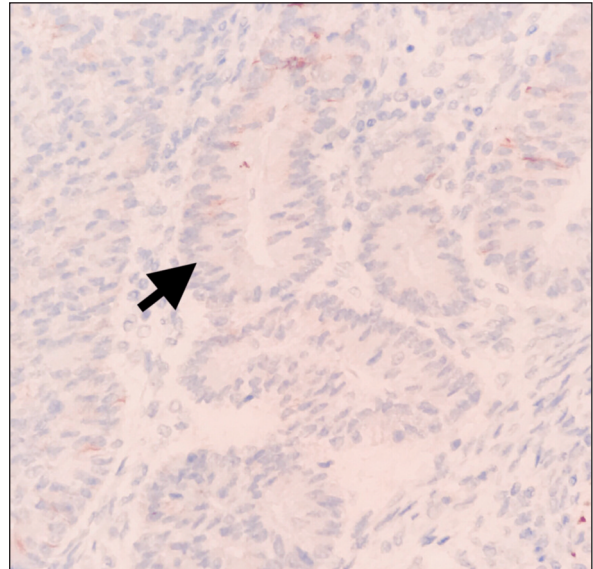
Figures given below, demonstrate a high grade and a well-differentiated ETEC, respectively ([Figure 1](#), [Figure 2](#)). Immunohistochemical



**FIGURE 1:** High grade endometrioid type of endometrial carcinoma (stained by hematoxylin & eosin at a magnification of 100X).



**FIGURE 2:** High-grade endometrioid type of endometrial carcinoma showing an immunohistochemically positive reaction with lumican (at 40X magnification). The single arrow indicates a negative reaction of stromal cells, the two arrows indicate a positive reaction of tumor cells.



**FIGURE 3:** Negative reaction with lumican at the focus of endometrial intraepithelial neoplasia as indicated by arrow (400X).

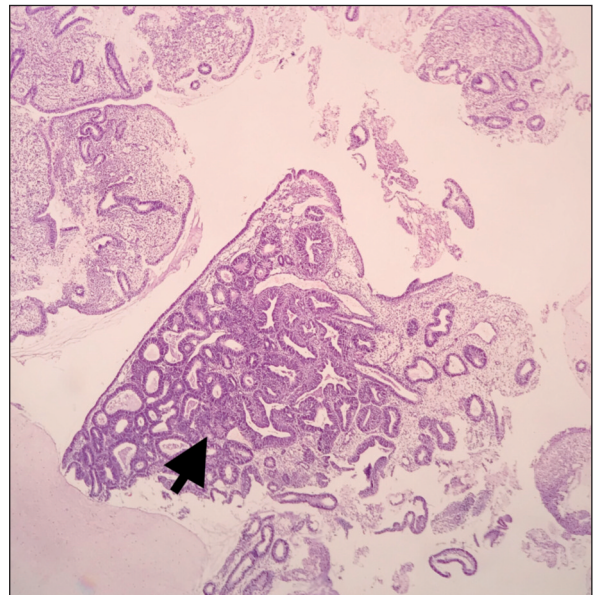
staining of lumican in high-grade ETEC is shown in [Figure 3](#). An immunohistochemically negative reaction with lumican in EC is depicted in [Figure 4](#).

#### OUTCOME PARAMETERS

The examined histopathological variables comprised grade; stage; squamous differentiation; lymphovascular, muscular, cervical, adnexal, omental involvement; metastases to paraaortic and pelvic lymph nodes; and the presence of any extrauterine diseases were recorded. The relationship between positive immunohistochemical staining of lumican and demographic, clinical and histopathological variables was sought.

#### STATISTICAL ANALYSIS

The analysis of data was performed via Statistical Package for Social Sciences (SPSS) software, version 21 (SPSS Inc., *Chicago, USA*). Descriptive variables were expressed as mean±standard deviation or median-interquartile range and minimum-max-



**FIGURE 4:** Endometrial biopsy. The endometrial intraepithelial neoplasia focus is shown by the arrow (stained by hematoxylin & eosin at a magnification of 40X).

imum values. Categorical variables were shown as number and percentage. Pearson's chi-square, Fisher's exact and the Mann-Whitney U tests were employed to compare the incidence of variables in different groups. A p-value less than 0.05 was considered to be statistically significant.

**TABLE 1:** Comparison of lumican positivity in tissue specimen from patients with endometrial intraepithelial neoplasia (EIN) and endometrial cancer (ETEC).

Variable	Lumican staining		X <sup>2</sup>	p*
	Positive n (%)	Negative n (%)		
Pathology				
EIN	10 (37)	17 (63)	12.7	<0.01**
ETEC	17 (89.5)	2 (10.5)		

Hint: \*Pearson chi square test; \*\* statistically significant.

**TABLE 2:** The relationship between lumican positivity in tissue specimen and histopathological features of endometrium cancer patients.

Variable	Lumican staining		X <sup>2</sup>	p*
	Positive n (%)	Negative n (%)		
Grade				
Grade 1 and 2	8 (100)	-	2.0	0.47
Grade 3	7 (77.8)	2 (22.2)		
Stage				
Stage 1	10 (100)	-	2.8	0.09
Stage 2 and higher	6 (75)	2 (25)		
Squamous differentiation				
No	7 (100)	-	1.6	0.49
Yes	8 (80)	2 (20)		
Lymph node metastasis				
No	12 (85.7)	2 (14.3)	0.5	1.0
Yes	3 (100)	-		
Myometrial involvement				
<1/2	6 (100)	-	1.1	0.53
>1/2	10 (83.3)	2 (16.7)		
Lymphovascular invasion				
No	8 (80)	2 (20)	1.8	0.48
Yes	8 (100)	-		
Cervical invasion				
No	13 (100)	-	5.9	0.07
Yes	3 (60)	2 (40)		
Adnexial invasion				
No	15 (93.7)	1 (6.3)	3.5	0.22
Yes	1 (50)	1 (50)		
Omental invasion				
No	15 (88.2)	2 (11.8)	0.13	1.0
Yes	1 (100)	-		
Pelvic lymph node invasion				
No	11 (84.6)	2 (15.4)	0.36	1.0
Yes	2 (100)	-		
Paralymphatic lymph node invasion				
No	6 (75)	2 (25)	0.92	1.0
Yes	3 (100)	-		

Hint: \*: Fisher's exact test.

## RESULTS

The comparison of the average age (expressed as median-interquartile range) of patients in EIN (48-34) and ETEC groups (59-42) showed that ETEC patients were older than EIN patients (p=0.01; Mann-Whitney U test).

Table 1 demonstrates a comparative overview of lumican positivity in EIN and ETEC patients. The positivity for lumican was more evident in specimens of ETEC patients compared to that of EIN patients (Pearson's chi-square test; p<0.01).

Table 2 demonstrates the relationship between lumican positivity and histopathological parameters in ETEC patients. No significant relationship between lumican positivity and grade, stage, squamous differentiation, lymph node metastases, myometrial involvement, invasion of lymphovascular, cervical, adnexial, omental tissues or involvement of pelvic and paraaortic lymph nodes was observed (p>0.05; Fisher's exact test).

The association between clinical variables and lumican positivity in ETEC group is depicted in Table 3. No remarkable link could be established between the lumican positivity and the presence of extrauterine disease, employment of adjuvant treatment and recurrence (p>0.05; Fisher's exact test).

**TABLE 3:** The relationship between lumican positivity in tissue specimen and clinicopathological features in endometrial cancer patients.

Variable	Lumican staining		X <sup>2</sup>	p*
	Positive n (%)	Negative n (%)		
Extrauterine disease				
No	10 (100)	-	2.8	0.09
Yes	6 (75)	2 (25)		
Adjuvant therapy				
No	5 (100)	-	0.9	1.0
Yes	11 (84.6)	2 (15.4)		
Recurrence				
No	13 (100)	-	5.9	0.07
Yes	3 (60)	2 (40)		

Hint: \* Fisher's exact test.

**TABLE 4:** The relationship between lumican positivity in endometrial cancer tissue specimen and clinicopathological parameters.

Variable	Lumican staining		Z*	p*	
	Positive (median-interquartile range)	Negative (median-interquartile range)			
Age	57-42	68.5-68.5	-1.5	0.13	
Tumor diameter	3.5-9.7	7.45-7.1	-1.4	0.18	
No. of pelvic lymph nodes dissected	22-49	26.5-7	-0.8	0.44	
No. of paraaortic lymph nodes dissected	14-29	15.5-9	-0.2	0.81	
No. of total lymph nodes dissected	27-81	42-2	-1.0	0.30	

Hint: \*Mann-Whitney U test.

The relationship between lumican positivity and clinicopathological features in ETEC patients is presented in Table 4. The results of this study indicate that lumican positivity was not significantly associated with age, tumor diameter and the number of pelvic, paraaortic and total number of dissected lymph nodes ( $p > 0.05$ ; Mann-Whitney U test).

## DISCUSSION

This study was performed to investigate the clinicopathological significance of the immunohistochemical staining of lumican in EIN and ETEC. The results of this study imply that lumican positivity was more obvious in ETEC patients as compared to that in EIN patients. Further, the ETEC patients were older in age than the EIN patients. On the other hand, the results of this study failed to confirm a remarkable relationship between lumican positivity and histopathological or clinical characteristics of ETEC patients.

Previous studies carried on proteomics offer an opportunity for the exploration of underlying pathophysiological processes and new therapeutic targets, along with new disease biomarkers.<sup>8,9</sup> These approaches are typically carried out on a small series to reach conclusions which must further be validated in larger cohorts.<sup>9</sup> Therefore, this study can be considered as a preliminary work that would pioneer other trials for the elucidation of the role of lumican in ECs.

Lumican is primarily a keratin sulfate molecule, which is a member of small leucine-rich pro-

teoglycan family. It is one of the extracellular matrix proteins and is expressed in various tissues like cornea, bone, cartilage, vessels, and skin.<sup>10-13</sup> The most prominent staining of lumican was previously reported in tumor cells infiltrating the lymph nodes at the invasive boundary of cancer cells.<sup>10</sup> Lumican is involved in the assembly of collagen fibrils and regulation of critical biological processes.<sup>14-16</sup> These processes may have crucial roles in the initiation and progression of cancer.<sup>17</sup> Hence, the changes in the expression of lumican may be associated with the spread of cancer. Relevant literature quotes that lumican regulated the migration of cells in cancers of prostate and colon. In these circumstances, lumican expression was associated with a less favorable prognosis and an advancement of the tumor.<sup>11,12</sup> Notably, high level of stromal lumican expression is linked with a higher grade of tumor and lower level of estrogen receptor levels.<sup>11,12</sup> Matsuda et al. investigated the expression of lumican in adenocarcinomas and squamous cell carcinomas of the lung.<sup>18</sup>

Lumican, being a component of the extracellular matrix, exerts various matricellular actions. It acts as a regulator of cell proliferation, gene expression, and wound healing.<sup>19</sup> The cytoplasmic expression of lumican in advanced colorectal cancer has been found to be associated with a less favorable prognosis.<sup>10</sup> Although the expression of lumican in pancreatic cancer has been reported previously, its exact role in the mechanism is still unclear.<sup>20</sup> The quantity of lumican expression in tumor tissues may be associated with both, ad-

vanced grade of the tumor as well as low estrogen receptor levels.<sup>20</sup> It has been reported that lumican, especially in the stromal tissues, and adjacent to tumor cells may have an important role in tumor formation and progression.<sup>20</sup>

To the best knowledge of the authors, this is the first study investigating the immunohistochemical staining of lumican in ECs. Previously, it was reported that lumican protein accumulates mainly at the periphery of the cancer cell foci in uterine cervical cancer.<sup>21</sup> This study, however, did not detect any findings supporting a correlation between the clinicopathological factors and immunohistochemical staining of lumican in EC. It can be speculated that a single factor cannot be responsible for tumor formation in EIN or ETEC, rather a combined expression of different factors and molecules may account for the pathogenesis of these clinical entities.

The main limitation of the present study was the relatively small size of the series. The results did not demonstrate any significant correlation between immunohistochemical staining of lumican and histopathological parameters under investigation, which may have occurred due to the constraints of the study such as small sample size, ethnic, genetic, environmental factors, as well as technical facilities. Further studies focusing on the role of lumican in gynecological malignancies must be encouraged in order to unveil the possible implications of lumican in tumor formation, progression, and prognosis. The functions performed by lumican in stromal tissues may have a significant application in tumor growth and invasion of EC. In order to discover the relationship between lumican and estrogen or progesterone, special attention must be paid to the female-hormone-related cancer cells, including EC cells. Although it is clear that lumican possesses a unique structure and demonstrates special functions which may influence tumor formation and progression, the precise mechanisms associated with these processes need to be elucidated further.

## CONCLUSION

It can be concluded that a better understanding of the molecular mechanisms that lead to the formation of EC may allow exploration of novel molecular targets and new therapeutic strategies in the treatment of ECs. The immunohistochemical staining and clinicopathological significance of lumican in EC need to be explored further by carrying out multicentric studies on larger series. Molecularly targeted therapies seem to be beneficial for EC patients and the sustained investigation into the molecular pathways of EC development and progression will help improve the knowledge of this pathology. Thereby, the discovery of novel and more effective options in diagnosis, prevention, treatment and follow-up of endometrial tumors is quite possible and must be further studied upon.

### Source of Finance

*During this study, no financial or spiritual support was received neither from any pharmaceutical company that has a direct connection with the research subject, nor from a company that provides or produces medical instruments and materials which may negatively affect the evaluation process of this study.*

### Conflict of Interest

*No conflicts of interest between the authors and / or family members of the scientific and medical committee members or members of the potential conflicts of interest, counseling, expertise, working conditions, share holding and similar situations in any firm.*

### Authorship Contributions

**Idea/Concept:** Hülya Ayık Aydın, Tayup Şimşek, **Design:** Hülya Ayık Aydın, Gülgün Erdoğan, **Control/Supervision:** Hülya Ayık Aydın, Zeynep Bayramoğlu, **Data Collection and/or Processing:** Hülya Ayık Aydın, Elif Peştereli, **Analysis and/or Interpretation:** Gülgün Erdoğan, Elif Peştereli, Zeynep Bayramoğlu, **Literature Review:** Hülya Ayık Aydın, **Writing the Article:** Hülya Ayık Aydın, **Critical Review:** Tayup Şimşek, Elif Peştereli, **References and Fundings:** Zeynep Bayramoğlu, **Materials:** Hülya Ayık Aydın.

## REFERENCES

- Doll A, Abal M, Rigau M, Monge M, Gonzalez M, Demajo S, et al. Novel molecular profiles of endometrial cancer-new light through old windows. *J Steroid Biochem Mol Biol.* 2008;108(3-5):221-9. [[Crossref](#)] [[PubMed](#)]
- Bokhman JV. Two pathogenetic types of endometrial carcinoma. *Gynecol Oncol.* 1983;15(1):10-7. [[Crossref](#)]
- Bansal N, Yendluri V, Wenham RM. The molecular biology of endometrial cancers and the implications for pathogenesis, classification, and targeted therapies. *Cancer Control.* 2009;16(1):8-13. [[Crossref](#)] [[PubMed](#)]
- Semere LG, Ko E, Johnson NR, Vitonis AF, Phang LJ, Cramer DW, et al. Endometrial intraepithelial neoplasia: clinical correlates and outcomes. *Obstet Gynecol.* 2011;118(1):21-8. [[Crossref](#)] [[PubMed](#)] [[PMC](#)]
- Rosato A, Menin C, Boldrin D, Dalla Santa S, Bonaldi L, Scaini MC, et al. Survivin expression impacts prognostically on NSCLC but not SCLC. *Lung Cancer.* 2013;79(2):180-6. [[Crossref](#)] [[PubMed](#)]
- Cappellesso R, Tinazzi A, Giurici T, Simonato F, Guzzardo V, Ventura L, et al. Programmed cell death 4 and micro RNA 21 inverse expression is maintained in cells and exosomes from ovarian serous carcinoma effusions. *Cancer Cytopathol.* 2014;122(9):685-93. [[Crossref](#)] [[PubMed](#)]
- Cappellesso R, Millionsi R, Arrigoni G, Simonato F, Carocchia B, Iori E, et al. Lumican is overexpressed in lung adenocarcinoma pleural effusions. *PLoS One.* 2015;10(5):e0126458. [[Crossref](#)] [[PubMed](#)] [[PMC](#)]
- Weston AD, Hood L. Systems biology, proteomics, and the future of health care: toward predictive, preventative, and personalized medicine. *J Proteome Res.* 2004;3(2):179-96. [[Crossref](#)]
- Rifai N, Gillette MA, Carr SA. Protein biomarker discovery and validation: the long and uncertain path to clinical utility. *Nat Biotechnol.* 2006;24(8):971-83. [[Crossref](#)] [[PubMed](#)]
- Seya T, Tanaka N, Shinji S, Yokoi K, Koizumi M, Teranishi N, et al. Lumican expression in advanced colorectal cancer with nodal metastasis correlates with poor prognosis. *Oncol Rep.* 2006;16(6):1225-30. [[Crossref](#)] [[PubMed](#)]
- Iozzo RV, Sanderson RD. Proteoglycans in cancer biology, tumour microenvironment and angiogenesis. *J Cell Mol Med.* 2011;15(5):1013-31. [[Crossref](#)] [[PubMed](#)] [[PMC](#)]
- Nikitovic D, Papoutsidakis A, Karamanos NK, Tzanakakis GN. Lumican affects tumor cell functions, tumor-ECM interactions, angiogenesis and inflammatory response. *Matrix Biol.* 2014;35:206-14. [[Crossref](#)] [[PubMed](#)]
- Dolhnikoff M, Morin J, Roughley PJ, Ludwig MS. Expression of lumican in human lungs. *Am J Respir Cell Mol Biol.* 1998;19(4):582-7. [[Crossref](#)] [[PubMed](#)]
- Schaefer L, Iozzo RV. Biological functions of the small leucine-rich proteoglycans: from genetics to signal transduction. *J Biol Chem.* 2008;283(31):21305-9. [[Crossref](#)] [[PubMed](#)] [[PMC](#)]
- Stamov DR, Müller A, Wegrowski Y, Brezillon S, Franz CM. Quantitative analysis of type I collagen fibril regulation by lumican and decorin using AFM. *J Struct Biol.* 2013;183(3):394-403. [[Crossref](#)] [[PubMed](#)]
- Vuillermoz B, Khoruzhenko A, D'Onofrio MF, Ramont L, Venteo L, Perreau C, et al. The small leucine rich proteoglycan lumican inhibits melanoma progression. *Exp Cell Res.* 2004;296(2):294-306. [[Crossref](#)] [[PubMed](#)]
- Lu P, Weaver VM, Werb Z. The extracellular matrix: a dynamic niche in cancer progression. *J Cell Biol.* 2012;196(4):395-406. [[Crossref](#)] [[PubMed](#)] [[PMC](#)]
- Matsuda Y, Yamamoto T, Kudo M, Kawahara K, Kawamoto M, Nakajima Y, et al. Expression and roles of lumican in lung adenocarcinoma and squamous cell carcinoma. *Int J Oncol.* 2008;33(6):1177-85.
- Yamanaka O, Yuan Y, Coulson-Thomas VJ, Gesteira TF, Call MK, Zhang Y, et al. Lumican binds ALK5 to promote epithelium wound healing. *PLoS One.* 2013;8(12):e82730. [[Crossref](#)] [[PubMed](#)] [[PMC](#)]
- Ishiwata T, Cho K, Kawahara K, Yamamoto T, Fujiwara Y, Uchida E, et al. Role of lumican in cancer cells and adjacent stromal tissues in human pancreatic cancer. *Oncol Rep.* 2007;18(3):537-43. [[Crossref](#)] [[PubMed](#)]
- Naito Z, Ishiwata T, Kurban G, Teduka K, Kawamoto Y, Kawahara K, et al. Expression and accumulation of lumican protein in uterine cervical cancer cells at the periphery of cancer nests. *Int J Oncol.* 2002;20(5):943-8. [[Crossref](#)] [[PubMed](#)]