

Acute Urinary Retention Due to a Giant Ovarian Tumor in Reproductive Ages: Case Report

Reprodüktif Dönemde Büyük Bir Over Tümörüne Bağlı Gelişen Akut Üriner Retansiyon

İlker SELÇUK,^a
Gökhan BOYRAZ,^a
Zafer Selçuk TUNCER^{a,b}

^aDepartment of Obstetrics and Gynecology,
^bGynecologic Oncology Unit,
Hacettepe University Faculty of Medicine,
Ankara

Geliş Tarihi/Received: 20.03.2013
Kabul Tarihi/Accepted: 04.06.2013

Yazışma Adresi/Correspondence:
İlker SELÇUK

Hacettepe University Faculty of Medicine,
Department of Obstetrics and Gynecology,
Ankara,
TÜRKİYE/TURKEY
ilkerselcukmd@hotmail.com

ABSTRACT Acute urinary retention (AUR) is called as the inability to urinate. Real incidence of AUR is unknown. Obstructive, infectious, pharmacologic and neurogenic pathologies can cause urinary retention. Patients with acute urinary retention usually come to the emergency units. Severe voiding symptoms but inability to urinate, increased post-voiding residual volume and needing catheterization might be taken into consideration for diagnosis. Obstruction of the lower urinary tract at the level of bladder neck or distal urethra causes obstructive urinary retention, bladder outlet obstruction. Although catheterization plays an important role as the initial management of acute urinary retention, identifying the underlying pathology is essential for the definitive treatment. Ovarian tumors and adnexal masses can cause acute urinary retention with bladder outlet obstruction. Additionally peritoneal cysts, bladder tumors, intraabdominal infections, abscess, hematomatopos and benign ovarian cysts could also cause AUR. Ultrasonography may be helpful for the diagnosis.

Key Words: Urinary retention; cystadenoma, mucinous; ovary

ÖZET Akut üriner retansiyon (AÜR) bir nedene bağlı olarak idrarı yapamama durumudur. AÜR'nin gerçek insidansı bilinmemektedir. Obstrüktif, infeksiyöz, farmakolojik ve nörojenik patolojiler üriner retansiyona neden olabilir. AÜR gelişen hastalar genellikle acil servislere gelirler. Ciddi işeme semptomlarına rağmen işeyememek, artmış işeme sonrası rezidüel hacim ve kateterizasyon ihtiyacı tanı için dikkate alınmalıdır. Alt üriner sistemin mesane boynu veya distal üretra seviyesinde tıkanması obstrüktif üriner retansiyonu, mesane çıkım darlığını oluşturur. Kateterizasyon akut üriner retansiyonun ilk müdahalesinde önemli bir yer olsa da altta yatan patolojinin tanımlanması kesin tedavi için elzemdir. Over tümörleri ve adneksiyal kitleler mesane çıkımı obstrüksiyonu yaparak akut üriner retansiyona neden olabilirler. Ek olarak peritoneal kistler, mesane tümörleri, intraabdominal enfeksiyonlar, abse, hematokolpos ve benign over kistleri AÜR'ye neden olabilirler. Ultrasonografi ise tanıda yardımcı olabilecek bir görüntüleme yöntemidir.

Anahtar Kelimeler: İdrar retansiyonu; kistadenoma, müsinöz; over

Türkiye Klinikleri J Gynecol Obst 2013;23(3):207-10

The term acute urinary retention (AUR) is called as the inability to urinate although the bladder is full with urine and you feel it.¹ While the real incidence of AUR is unknown, it varies between men and women and is less commonly seen in women.² Obstructive, infectious, pharmacologic, neurogenic and functional pathologies can cause urinary retention.³

Ovarian cyst is an important but rare etiologic database of acute urinary retention by obstructive ways. Although the exact incidence of ovarian cysts is unknown; a few case reports have been described in the literature. It would be seen not only in adolescents and elderly women but also in infantile population.⁴⁻⁶ Matsuo et al. in 1998 had reported the 5th urinary retention case due to a large mucinous ovarian cyst in Japanese literature.⁵

Here, we describe a patient of acute urinary retention due to a large ovarian cyst in reproductive age with the hope of improving women's health.

CASE REPORT

A 28-years old gravida 0 woman came to our hospital with an indwelling foley catheter which was placed at another hospital due to the symptoms of acute urinary retention and inability to void. She had repeated symptoms of voiding difficulty and intermittant progressively worsening pelvic pain with abdominal distention during the last 2 months. The abdominal sonography had revealed a retrovesical, retrouterine, 13 cm, complex, cystic mass within the pelvis at the right ovary compressing the uterus anterosuperiorly. The history of the patient did not reveal any significance. Tumor markers (Ca 125, beta-hcg, AFP, LDH, Ca19-9, CEA, Ca15-3), hemogram, liver enzymes, creatinin and electrolytes were in normal limits. The physical examination showed a firm, palpable abdominal mass.

We performed a laparoscopy. There was a huge, semi-solid appearing right ovarian cyst, deeply lying at the posterior of the uterus towards the douglas and compressing the bladder and the uterine cervix anterosuperiorly (Figure 1). There was not any other pathology, but the mass was extremely heavy and not movable so, we quitted laparoscopy and conversed to the laparotomy due to the risk of cyst perforation (Figure 2) in case of malignancy. We performed cystectomy with maximal ovarian tissue preservation and the frozen section analysis revealed a benign mucinous cystadenoma. The tumor measured in 14x10x7 cm diameter and

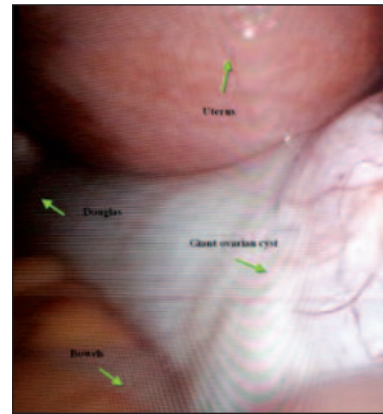


FIGURE 1: Semi-solid appearing right ovarian cyst at laparoscopy, deeply lying at the posterior of the uterus towards the douglas and compressing the bladder and the uterine cervix anterosuperiorly (appearing between bowels, uterus and douglas).

(See color figure at <http://jinekoloji.turkiyeklinikleri.com/>)

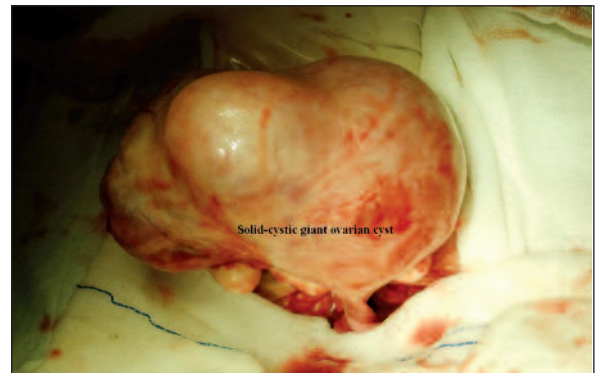


FIGURE 2: Solid-cystic giant ovarian cyst while performing laparotomy.

(See color figure at <http://jinekoloji.turkiyeklinikleri.com/>)

the histopathologic examination showed a multi-loculated cystic structure with mucinous epithelium. The patient was discharged on the postoperative 2nd day and the urinary symptoms disappeared after the operation.

DISCUSSION

Patients with acute urinary retention usually come to the emergency units and mostly general practitioners or family medicine physicians make the initial management of these patients. The etiologic causes and the differential diagnosis of acute urinary retention range widely and it is particularly important for the physician to take an accurate history, examine the patient carefully and plan the diagnostic laboratory or radiologic tests.³

Acute urinary retention is not common for women and it is generally reported as isolated case reports or case series. One study stated the incidence of AUR as 7 per 100.000 women.⁷ Pelvic pressure, pelvic pain and lower abdominal discomfort could all be the symptoms of an acute urinary retention depending on the capacity and enlargement of the bladder.³ Despite many etiologic causes of acute urinary retention, Swinn et al. reported gynecologic pelvic surgery under general anesthesia as the most common cause of acute urinary retention with the mean age of 27.⁸

Pregnancy is also an etiologic factor for younger women of acute urinary retention with the impacted retroverted uterus, by obstructive reasons.⁹

Obstruction of the lower urinary tract at the level of bladder neck or distal urethra causes obstructive urinary retention; bladder outlet obstruction (BOO). The prevalence of the bladder outlet obstruction differs between 2.7% to 29% in urinary retention group since there are no known standard diagnostic criteria for the definition.¹⁰ Severe voiding symptoms but inability to urinate, increased post-voiding residual volume and needing catheterization might be taken into consideration for diagnosis. Our patient had all of these findings when she admitted to the outside hospital.

The etiologic database of urinary retention and bladder outlet obstruction could be categorized as the functional and anatomical causes.¹¹ Anatomical causes can be divided into three categories. Pelvic organ prolapse, adnexal tumors, uterine fibroids, anti-incontinence procedures and pessery problems form extrinsic part; stenosis, stricture, caruncle, skene's gland pathologies form urethral part and pathologies like stone and bladder tumor may form luminal part. Whereas functional pathologies may result from impaired coordination, peri-operative conditions, infections or pharmacological effects of drugs.¹¹

Although catheterization plays an important role at the initial management of acute urinary retention, identifying the underlying pathology is essential for the definitive treatment.¹² Non-uro-

dynamic testing like postvoiding residual volume; cystoscopy, voiding cystourethrogram, urodynamic evaluation and ultrasonography could all take place in the evaluation of bladder outlet obstruction.¹³ Our patient was 28-years old and having symptoms defined above like pelvic pressure and abdominal distention. Sonography could be helpful for the diagnosis of many etiologies, however anatomical reasons as pelvic masses importantly could be kept on mind, like our patient.

Ovarian cysts, tumors and adnexal masses can cause acute urinary retention with bladder outlet obstruction.¹⁴ Impacted pelvic masses, huge ovarian cysts can cause an anterosuperior displacement of the cervix and so far the lower bladder is compressed with an obstruction.¹²

Giant ovarian cysts especially quickly growing cysts like mucinous typed could be a reason for AUR.⁵ Additionally dermoid cysts and hematocolpos should not be underestimated in adolescents.^{4,15} In older population bladder neck tumors and serous epithelial ovarian tumors could be an etiology for acute urinary retention.¹⁶ Tuberculous pyometra has also been reported as a cause of acute urinary retention in older population.¹⁷ Meanwhile large peritoneal cysts could also cause acute urinary retention.¹⁸

Adali et al. reported a case of hematocolpos in an adolescent as the cause of acute urinary retention by the obstructive effect of accumulated menstrual blood in the vagina and uterus.¹⁵ Although sonography is the preferred method for diagnosis, magnetic resonance imaging (MRI) should also be needed if complicated obstructive pathologies and abnormalities is suspected.¹⁵ Moreover magnetic resonance urography could also be helpful in obstructive urinary retention.¹⁹

Mucinous cystadenomas (MCA) originate from the coelomic epithelium of the ovary. 12-15% of all ovarian tumors are mucinous tumors and they are generally benign (75%); 10% borderline and 15% carcinomas.²⁰ MCAs are generally unilateral and benign, only 5% are bilateral; moreover they are multilocular in 76% and may grow in high dimensions until the diagnosis.²¹ Our patient had also

a big, unilateral, benign and multiloculated cyst. MCAs may show non-specific symptoms but the characterization of the tumor such as reaching to very high dimensions can cause intraabdominal pressure, pain, constipation, pressure on the bladder or vessels and abdominal distention. Additionally a rapidly growing mass may cause respiratory symptoms and/or edema of the lower extremity.²²

Ultrasound is helpful for the diagnosis of ovarian cysts but sometimes it would be difficult to determine the origin of the cyst and its relationship to the peripheral tissue; in that situation magnetic resonance could be an additional imaging modality.

Laparoscopy or laparotomy regarding to the the malignant potential of the cyst, clinical skills of the surgeon and equipment assistance could be pre-

ferred. Especially for young patients ovarian tissue preservation is very important for the future fertility desire and ovarian cystectomy with a conservative surgery could be performed if the frozen section analysis shows benign conditions. Despite it is rarely reported in the literature, recurrence of mucinous cysts could also be seen and patients may go recurrent operations.²³

In conclusion, abdominal distention, pelvic pressure, acute urinary retention, painful voiding should not be underestimated in reproductive ages; and sonography may be just simple but an effective method especially for pelvic anatomical pathologies like masses. Especially mucinous ovarian tumors must be kept on mind while they can grow rapidly in high dimensions.

REFERENCES

- Rosenstein D, McAninch JW. Urologic emergencies. *Med Clin North Am* 2004;88(2):495-518.
- Özyurt C. [Urinary retention in women]. *Turkiye Klinikleri J Surg Med Sci* 2005;1(5):56-60.
- Selius BA, Subedi R. Urinary retention in adults: diagnosis and initial management. *Am Fam Physician* 2008;77(5):643-50.
- Bosio M, Ballerini G, Cattaneo A. Acute urinary retention: a rare onset sign of ovarian cystic teratoma. *Int J Pediatr Nephrol* 1983;4(4):263-5.
- Matsuo E, Suzu H, Tagawa H. [A case of ovarian cyst presenting as urinary retention]. *Hinyokika Kiyo* 1998;44(4):293-5.
- Matsumoto M, Watanabe T, Uekado Y, Ohkawa T. [A case of urinary retention due to ovarian dermoid cyst in a female infant]. *Hinyokika Kiyo* 1993;39(1):85-7.
- Klarskov P, Andersen JT, Asmussen CF, Brenøe J, Jensen SK, Jensen IL, et al. Acute urinary retention in women: a prospective study of 18 consecutive cases. *Scand J Urol Nephrol* 1987;21(1):29-31.
- Swinn MJ, Wiseman OJ, Lowe E, Fowler CJ. The cause and natural history of isolated urinary retention in young women. *J Urol* 2002;167(1):151-6.
- Cardozo L, Cutner A. Lower urinary tract symptoms in pregnancy. *Br J Urol* 1997;80 (Suppl 1):14-23.
- Patel R, Nitti V. Bladder outlet obstruction in women: prevalence, recognition, and management. *Curr Urol Rep* 2001;2(5):379-87.
- Mevcha A, Drake MJ. Etiology and management of urinary retention in women. *Indian J Urol* 2010;26(2):230-5.
- Yang JM, Huang WC. Sonographic findings of acute urinary retention secondary to an impacted pelvic mass. *J Ultrasound Med* 2002;21 (10):1165-9.
- Dmochowski RR. Bladder outlet obstruction: etiology and evaluation. *Rev Urol* 2005;7 (Suppl 6):S3-S13.
- Doran J, Roberts M. Acute urinary retention in the female. *Br J Urol* 1975;47(7):793-6.
- Adali E, Kurdoglu M, Yildizhan R, Kolusari A. An overlooked cause of acute urinary retention in an adolescent girl: a case report. *Arch Gynecol Obstet* 2009;279(5):701-3.
- Stamatiou K. Urinary retention due to benign tumor of the bladder neck in a woman; a rare case of papillary cystitis. *Urologia* 2013;80(1):83-5.
- Yanagizawa R, Inoue S, Itakura H, Kishi H, Fujimaru J, Wada Y. [A case of urinary retention due to tuberculous pyometra]. *Nihon Hinyokika Gakkai Zasshi* 1992;83(5): 690-3.
- Advincula AP, Hernandez JC. Acute urinary retention caused by a large peritoneal inclusion cyst: a case report. *J Reprod Med* 2006;51(3):202-4.
- Boyunağa ÖL. [Magnetic resonance imaging in uro radiology]. *Turkiye Klinikleri J Radiol-Special Topics* 2011;4(2):128-35.
- Rodríguez IM, Prat J. Mucinous tumors of the ovary: a clinicopathologic analysis of 75 borderline tumors (of intestinal type) and carcinomas. *Am J Surg Pathol* 2002;26(2):139-52.
- Hart WR. Mucinous tumors of the ovary: a review. *Int J Gynecol Pathol* 2005;24(1):4-25.
- Cevik M, Guldur ME. An extra-large ovarian mucinous cystadenoma in a premenarchal girl and a review of the literature. *J Pediatr Adolesc Gynecol* 2013;26(1):22-6.
- Baksu B, Akyol A, Davas I, Yazgan A, Ozgul J, Tanik C. Recurrent mucinous cystadenoma in a 20-year-old woman: was hysterectomy inevitable? *J Obstet Gynaecol Res* 2006;32(6): 615-8.