

# The Correlation of Hysteroscopic Diagnosis with Histopathologic Findings in Patients with Post-Menopausal Bleeding: A Retrospective Cross-Sectional Study

Özge Senem YÜCEL ÇİÇEK<sup>a</sup>, Simay FİDAN<sup>b</sup>, Mert Doğan FİLİNDE<sup>a</sup>, Mehriban ZEYNALLI<sup>a</sup>, Hayal UZELLİ ŞİMŞEK<sup>a</sup>

<sup>a</sup>Department of Obstetrics and Gynecology, Kocaeli University Faculty of Medicine, İzmit, Türkiye

<sup>b</sup>Department of Obstetrics and Gynecology, Ankara University Faculty of Medicine, Ankara, Türkiye

**ABSTRACT Objective:** Abnormal uterine bleeding, namely post-menopausal bleeding (PMB), is the most common symptom of intrauterine pathologies in post-menopausal women. This study aimed to investigate the complementary role of hysteroscopy in the management of PMB and the sensitivity of hysteroscopy compared to histopathologic examination in PMB. **Material and Methods:** This was a retrospective cross-sectional study including patients undergoing hysteroscopy and endometrial curettage. If a local lesion like polyp or myoma uteri was detected, hysteroscopic resection was performed and the tissue was sent for histopathologic examination. If no local lesion was detected, the endometrial cavity was classified as normal, hyperplastic (thickened, irregular cavity), or atrophic (thin and pale cavity). The sensitivity, specificity, positive predictive value (PPV), negative predictive value (NPV), and diagnostic accuracy of hysteroscopy were calculated for every histopathologic finding. **Results:** The main hysteroscopic findings were endometrial polyp in 54 (47%) cases, normal cavity in 26 (22.6%), atrophy in 14 (12.1%) cases, hyperplastic endometrium in 11 (9.6%) cases and myoma uteri in 10 (8.7%) cases. The sensitivity, specificity, PPV, NPV and diagnostic accuracy of hysteroscopy for endometrial polyps were 70.0%, 72.0%, 76.0%, 65.0% and 71.0% respectively. In 3 cases, histopathological examination showed endometrial hyperplasia within polyps. The sensitivity, specificity, PPV, NPV and diagnostic accuracy of hysteroscopy for myoma uteri were 87.5%, 96.9%, 70.0%, 99.0% and 97.2% respectively. **Conclusion:** Hysteroscopy showed lower diagnostic accuracy for endometrial pathologies, especially endometrial cancer, validating the need for histopathologic examination. The diagnosis cannot depend on hysteroscopic assessment alone and histopathologic examination should be performed in all PMB cases.

**Keywords:** Endometrial neoplasms; histopathology; hysteroscopy; polyps; post-menopausal bleeding

Menopause is defined as the permanent cessation of menses. The diagnosis is made retrospectively after 12 months from the last menses. Abnormal uterine bleeding in menopause, namely post-menopausal bleeding (PMB), is a relatively common gynecologic complaint. The prevalence is 42/1,000 women year 3 years after menopause.<sup>1</sup> PMB usually occurs due to benign conditions such as endometrial atrophy or polyps. However, endometrial cancer can also cause PMB, and the risk of endometrial cancer in women with PMB is approximately 10-15%. Therefore, the presence of PMB merits further evaluation, and di-

lation and curettage was considered the gold standard diagnostic method for PMB.<sup>1</sup> On the other hand, endometrial curettage is a blind procedure and can be incomplete in more than 50% of the patients.<sup>2</sup>

Hysteroscopy is a minimally invasive procedure that allows direct visualization of the endocervical canal and endometrial cavity. Hysteroscopy is considered the gold standard method to evaluate the endometrial cavity. However, a high failure rate of office hysteroscopy up to 22% has been reported in patients with PMB, mainly due to cervical stenosis and pain.<sup>3</sup>

**Correspondence:** Özge Senem YÜCEL ÇİÇEK

Department of Obstetrics and Gynecology, Kocaeli University Faculty of Medicine, İzmit, Türkiye

**E-mail:** ozgesenemyucl@gmail.com



Peer review under responsibility of Journal of Clinical Obstetrics & Gynecology.

**Received:** 28 Mar 2022

**Received in revised form:** 06 May 2022

**Accepted:** 04 Oct 2022

**Available online:** 13 Oct 2022

2619-9467 / Copyright © 2022 by Türkiye Klinikleri. This is an open access article under the CC BY-NC-ND license (<http://creativecommons.org/licenses/by-nc-nd/4.0/>).

There is no consensus on the optimal diagnostic strategy for PMB. Every diagnostic method has its advantages and potential drawbacks. This study aimed to investigate the complementary role of hysteroscopy in the management of PMB and the sensitivity of hysteroscopy compared to histopathologic examination in PMB.

## MATERIAL AND METHODS

### ETHICS

This study has been reviewed and approved by the Institutional Review Committee of Kocaeli University Faculty of Medicine (approval date: March 10, 2022, approval number: KU GOKAEK-2022/05.05). Informed consent was obtained from all patients. All procedures performed in this study were in accordance with the 1964 Helsinki Declaration and its later amendments.

### STUDY DESIGN

This was a retrospective cross-sectional study conducted at Kocaeli University Obstetrics and Gynecology Department. The study population included patients undergoing hysteroscopy and endometrial curettage for PMB between July 2018 and December 2021. PMB is defined as the occurrence of vaginal bleeding after 12 months of amenorrhea after the age of 45. The inclusion criteria were undergoing hysteroscopy and endometrial curettage in the same session and having a histopathologic examination. The exclusion criteria were undergoing hysteroscopy for any reason other than PMB, and operations without histopathologic evaluations.

### HYSTEROSCOPY PROCEDURE

Patients were administered 200 mcg sublingual misoprostol (Cytotec, Pfizer, İstanbul, Türkiye) 2 hours before the procedure. The hysteroscopy and endometrial curettage procedures were carried out under general anesthesia. The patient was placed in the lithotomy position and a speculum was inserted to visualize the cervix. The cervix is grasped with a tenaculum and cervical dilatation was performed using Hegar dilators. The dilatation was continued until the 6 mm Hegar dilator fit comfortably. A rigid 6-mm outer sheath hysteroscope with an optic of 30 degrees (Karl

Storz, Tuttlingen, Germany) was inserted through the introitus, and the endocervical canal, endometrial cavity, and bilateral tubal ostia were examined via the hysteroscope. If a local lesion like polyp or myoma uteri was detected, hysteroscopic resection was performed and the tissue was sent for histopathologic examination. If no local lesion was detected, the endometrial cavity was classified as normal, hyperplastic (thickened, irregular cavity), or atrophic (thin and pale cavity). After the hysteroscopic evaluation was completed, a vacuum curettage with a 4-mm or 5-mm Karman curette (Medbar medical products, İzmir, Türkiye) was performed. The material was sent for pathological examination.

### STATISTICAL ANALYSIS

All statistical analyses were performed using IBM SPSS Statistical Package version 21.0 (IBM Corp., Armonk, NY, USA). The data were expressed as mean±standard deviation, and the categorical variables were expressed as counts (percentages). The histopathologic result was considered the gold standard diagnostic procedure. The sensitivity, specificity, positive predictive value (PPV), negative predictive value (NPV), and diagnostic accuracy of hysteroscopy were calculated for every histopathologic finding.

## RESULTS

A total of 1,063 hysteroscopies were performed between July 2018 and December 2021. Of these, 124 were performed for the evaluation of PMB (Figure 1). In 6 (4.8%) cases, the endometrial cavity could not be visualized due to cervical stenosis. In 9 (7.3%) cases, the histopathologic examination could not be carried out due to insufficient material. In these cases, the hysteroscopy showed atrophic (5 cases) or normal endometrium (4 cases). In 2 (1.6%) cases, endometrial cavity could not be evaluated properly due to collection of blood in the cavity. Uterine rupture occurred in one case (0.8%) and no major complication occurred in any other. Therefore, hysteroscopic evaluation could be carried out in 115 cases and both hysteroscopy and endometrial curettage could be performed in 106 cases.

The mean patient age was 57.4±7.9. The age distribution of patients with PMB is shown in Table 1.

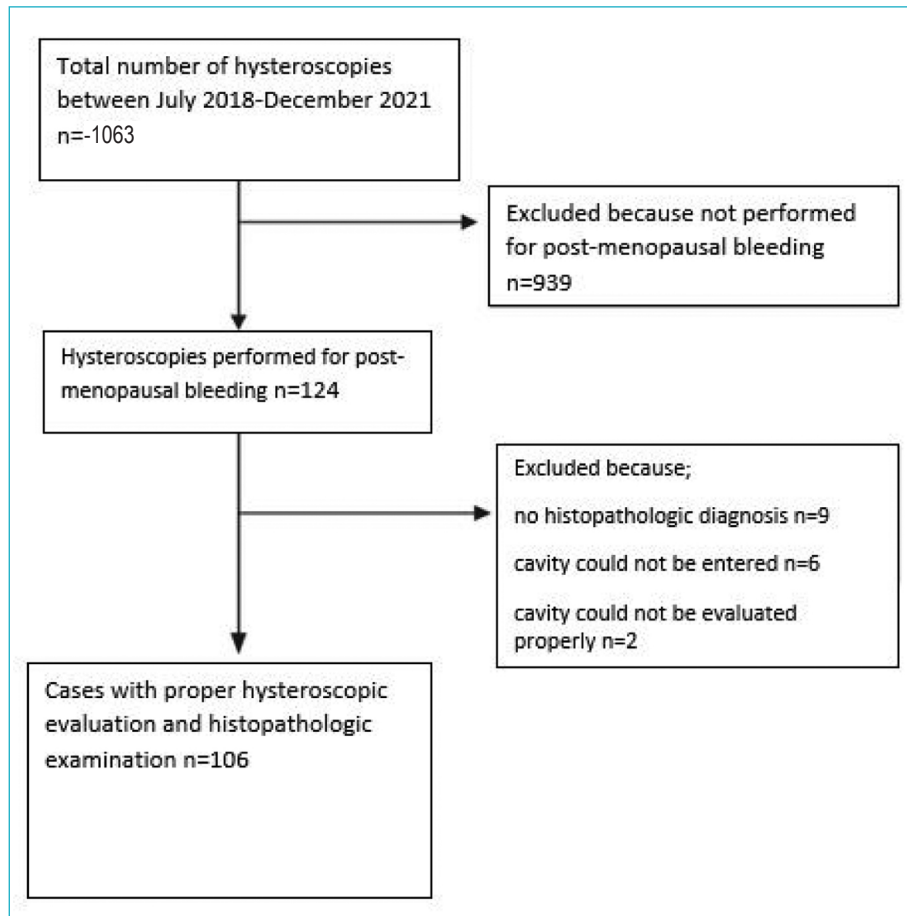


FIGURE 1: The flowchart of the study.

The main hysteroscopic findings were endometrial polyp in 54 (47%) cases, normal cavity in 26 (22.6%), atrophy in 14 (12.1%) cases, hyperplastic endometrium in 11 (9.6%) cases and myoma uteri in 10 (8.7%) cases (Table 2). The histopathological examination showed endometrial polyp in 59 (55.7%) cases, normal histopathology or atrophy in 26 (24.5%) cases, myoma uteri in 8 (7.5%) cases, endometrial hyperplasia in 7 (6.6%) cases and cancer in 6 (5.7%) cases.

The sensitivity, specificity, PPV, NPV and diagnostic accuracy of hysteroscopy for endometrial polyps were 70.0%, 72.0%, 76.0%, 65.0%, and 71.0%, respectively (Table 3). In 3 cases, histopathological examination showed endometrial hyperplasia within polyps.

The sensitivity, specificity, PPV, NPV and diagnostic accuracy of hysteroscopy for myoma uteri were

**TABLE 1:** Age distribution of patients with postmenopausal bleeding.

Patient age (y)	Number of patients (n=124)	
45-49	20	16%
50-59	62	50%
60-69	32	26%
70-90	10	8%

87.5%, 96.9%, 70.0%, 99.0% and 97.2%, respectively. In 3 cases where hysteroscopy diagnosed the lesion as myoma uteri, histopathologic examination identified endometrial polyp.

The sensitivity, specificity, PPV, NPV and diagnostic accuracy of hyperplastic endometrium for endometrial carcinoma and its precursors were 46.2%, 95.0%, 55.0%, 93.0%, and 89.0%, respectively.

**TABLE 2:** Correlation of hysteroscopic and histopathologic findings.

Hysteroscopy	Histopathology				Endometrial carcinoma and precursors	Total
	Normal findings	Atrophy	endometrial polyp	Myoma uteri		
Normal findings	8	0	9	0	5	22
Atrophy	0	8	1	0	0	9
Polyp	10	0	41	1	2	54
Myoma uteri	0	0	3	7	0	10
Hyperplastic endometrium	0	0	5	0	6	11
Total	18	8	59	8	13	106

**TABLE 3:** Statistical evaluation of hysteroscopy as a diagnostic test for post-menopausal bleeding.

Hysteroscopy	Normal	Atrophy	Endometrial polyp	Myoma uteri	Endometrial carcinoma and precursors
Sensitivity % (95% CI)	44 (22-69)	100 (63-100)	70 (56-81)	88 (47-100)	46 (19-75)
Specificity % (95% CI)	84 (75-91)	99 (94-100)	72 (57-84)	97 (91-99)	95 (88-98)
PPV % (95% CI)	36 (22-54)	89 (53-98)	76 (66-84)	70 (43-88)	55 (30-77)
NPV % (95% CI)	88 (83-92)	100	65 (55-74)	99 (94-100)	93 (88-95)
Accuracy % (95% CI)	77 (68-85)	99 (95-100)	71 (61-79)	96 (91-99)	89 (81-94)

CI: Confidence interval; PPV: Positive predictive value; NPV: Negative predictive value.

The sensitivity, specificity, PPV, NPV and diagnostic accuracy of normal hysteroscopy for normal histopathology were 44.0%, 84.0%, 36.4%, 88.0%, and 77.0%, respectively. The sensitivity, specificity, PPV, NPV and diagnostic accuracy of atrophic endometrium finding for endometrial atrophy were 100%, 99.0%, 89.0%, 100%, and 99%, respectively.

## DISCUSSION

PMB is the most common symptom of intrauterine pathologies in post-menopausal women.<sup>4</sup> The main concern in a patient with PMB is endometrial cancer. Therefore PMB warrants further investigation.<sup>5</sup> This study explored the visual accuracy of hysteroscopy compared to histopathological examination. Our results have shown that hysteroscopy alone showed excellent diagnostic accuracy for myoma uteri and endometrial atrophy. However, hysteroscopic evaluation was moderately accurate for diagnosing endometrial polyps, endometrial carcinoma and its precursors.

Endometrial polyps are the most commonly seen intrauterine lesions and can be present in up to 20% of post-menopausal women.<sup>4</sup> In line with the literature, the most common endometrial pathology was

polyps in the present study. Hysteroscopy has been considered the ideal diagnostic method for endometrial polyps.<sup>6</sup> We found that the sensitivity of hysteroscopy for endometrial polyps was 70%. In the literature, a sensitivity ranging between 58-99% has been reported for endometrial polyps.<sup>6</sup> Endometrial polyps can be associated with pre-malignant and malignant conditions. The malignancy rate associated with polyps ranges from 0.8 to 8% depending on the diagnostic method and other factors.<sup>7</sup> In our study, endometrial hyperplasia within a polyp was reported in 3 cases (5%). Hysteroscopy alone may fail to recognize hyperplasia and/or neoplasia within an endometrial polyp as previously described in the literature, which amplifies the need to obtain a biopsy.<sup>8,9</sup>

We verified that hysteroscopic diagnosis of myomas is highly accurate with high sensitivity and specificity.<sup>10-12</sup> Furthermore, hysteroscopy gives the chance to remove the submucous myomas. Therefore, hysteroscopy is the ideal method to diagnose and treat myoma uteri. In agreement with the literature, our results show that hysteroscopic myomectomy is a minimally invasive and safe procedure.<sup>13</sup> In the present study, the histopathologic examination diagnosed

myoma uteri in 8 cases. No major complication including heavy bleeding or perforation occurred in any.

The most important objective of hysteroscopic examination should be distinguishing carcinoma from other endometrial pathologies. In the present study, hysteroscopy showed high specificity and NPV for endometrial carcinoma and its precursors. However, the sensitivity and PPV were disappointingly low at 46.2% and 54.5%, respectively. These results are similar to other studies' who have found low sensitivity and PPV for hyperplasia but they reported better outcomes for endometrial carcinoma.<sup>9,14,15</sup> Two studies reported endometrial hyperplasia separately in premenopausal and postmenopausal patients, in the premenopausal population they both reported lower sensitivity and PPV similar to ours, both studies had much better results in the postmenopausal group.<sup>16,17</sup> However, in the present study, we assessed the diagnostic accuracy of hyperplastic endometrium for endometrial carcinoma. Specific hysteroscopic findings such as whitish/grayish color pattern, atypical vascularization were shown to be distinctive of endometrial carcinoma.<sup>18</sup> Therefore, hysteroscopic evaluation based on these morphological features rather than solely hyperplastic endometrium appearance would improve diagnostic accuracy for endometrial cancer.

Although hysteroscopy has been considered the gold-standard technique for endometrial pathologies, and the studies reported excellent results for the diagnostic accuracy of hysteroscopy, our results have shown that hysteroscopy alone is not ideal in discerning diseased and healthy endometrium.<sup>13</sup> Surgeon's experience has been shown to affect hysteroscopy success.<sup>19</sup> The present study was conducted in a training hospital which might have affected the results. Especially, when his/her experience is limited, the surgeon should not rely solely on the hysteroscopic findings and perform a biopsy.

On a different note, recently Zhang et al. constructed a model for classifying endometrial lesions. They have put a training set of 6,478 images into the model. Thereafter compared the results with gynecologists' and came up with a diagnostic accuracy of 80%. Then they split the test set equally at random

and compared direct diagnosis to model aided diagnosis by gynecologists, the accuracies of model aided diagnosis was 8 to 14% higher compared to gynecologists' alone.<sup>20</sup> Further studies on the subject could help improve diagnostic accuracy of hysteroscopic images.

This study has several limitations, including its retrospective nature and small sample size of 106 women. Execution of larger studies on the subject are essential to better understand the issue. Despite its limitations, the present study presents valuable data since all of the subjects included had histopathological examination.

## CONCLUSION

In conclusion, hysteroscopy alone showed lower diagnostic accuracy for endometrial pathologies in our study, especially endometrial cancer, validating the need for histopathologic examination. The diagnosis cannot depend on hysteroscopic assessment alone and histopathologic examination should be performed in all PMB cases.

### Source of Finance

*During this study, no financial or spiritual support was received neither from any pharmaceutical company that has a direct connection with the research subject, nor from a company that provides or produces medical instruments and materials which may negatively affect the evaluation process of this study.*

### Conflict of Interest

*No conflicts of interest between the authors and / or family members of the scientific and medical committee members or members of the potential conflicts of interest, counseling, expertise, working conditions, share holding and similar situations in any firm.*

### Authorship Contributions

**Idea/Concept:** Özge Senem Yücel Çiçek; **Design:** Özge Senem Yücel Çiçek, Mehriban Zeynalli; **Control/Supervision:** Özge Senem Yücel Çiçek; **Data Collection and/or Processing:** Mert Doğan Filinde, Mehriban Zeynalli; **Analysis and/or Interpretation:** Simay Fidan, Hayal Uzelli Şimşek; **Literature Review:** Simay Fidan; **Writing the Article:** Özge Senem Yücel Çiçek, Simay Fidan; **Critical Review:** Özge Senem Yücel Çiçek; **References and Fundings:** Hayal Uzelli Şimşek; **Materials:** Hayal Uzelli Şimşek.

## REFERENCES

- Carugno J. Clinical management of vaginal bleeding in postmenopausal women. *Climacteric*. 2020;23(4):343-9. [[Crossref](#)] [[PubMed](#)]
- Stock RJ, Kanbour A. Prehysterectomy curettage. *Obstet Gynecol*. 1975;45(5):537-41. [[PubMed](#)]
- Capmas P, Pourcelot AG, Giral E, Fedida D, Fernandez H. Office hysteroscopy: A report of 2402 cases. *J Gynecol Obstet Biol Reprod (Paris)*. 2016;45(5):445-50. [[Crossref](#)] [[PubMed](#)]
- Fagioli R, Vitagliano A, Carugno J, Castellano G, De Angelis MC, Di Spiezio Sardo A. Hysteroscopy in postmenopause: from diagnosis to the management of intrauterine pathologies. *Climacteric*. 2020;23(4):360-8. [[Crossref](#)] [[PubMed](#)]
- Clarke MA, Long BJ, Del Mar Morillo A, Arbyn M, Bakkum-Gamez JN, Wentzensen N. Association of endometrial cancer risk with postmenopausal bleeding in women: a systematic review and meta-analysis. *JAMA Intern Med*. 2018;178(9):1210-22. [[Crossref](#)] [[PubMed](#)] [[PMC](#)]
- American Association of Gynecologic Laparoscopists. AAGL practice report: practice guidelines for the diagnosis and management of endometrial polyps. *J Minim Invasive Gynecol*. 2012;19(1):3-10. [[Crossref](#)] [[PubMed](#)]
- Godoy CE Jr, Antunes A Jr, Morais SS, Pinto-Neto AM, Costa-Paiva L. Accuracy of sonography and hysteroscopy in the diagnosis of premalignant and malignant polyps in postmenopausal women. *Rev Bras Ginecol Obstet*. 2013;35(6):243-8. [[Crossref](#)] [[PubMed](#)]
- Mencaglia L, Perino A, Hamou J. Hysteroscopy in perimenopausal and postmenopausal women with abnormal uterine bleeding. *J Reprod Med*. 1987;32(8):577-82. [[PubMed](#)]
- Garuti G, Sambruni I, Colonnelli M, Luerti M. Accuracy of hysteroscopy in predicting histopathology of endometrium in 1500 women. *J Am Assoc Gynecol Laparosc*. 2001;8(2):207-13. [[Crossref](#)] [[PubMed](#)]
- Patil SG, Bhute SB, Inamdar SA, Acharya NS, Shrivastava DS. Role of diagnostic hysteroscopy in abnormal uterine bleeding and its histopathologic correlation. *J Gynecol Endosc Surg*. 2009;1(2):98-104. [[PubMed](#)] [[PMC](#)]
- Acharya V, Mehta S, Rander A. Evaluation of dysfunctional uterine bleeding by TVS, hysteroscopy and histopathology. *J Obstet Gynecol India*. 2003;53(3):170-7. [[Link](#)]
- Panda A, Parulekar S, Gupta A. Diagnostic hysteroscopy in abnormal uterine bleeding and histopathological correlation. *J Obstet Gynaecol India*. 1999;49:74-6.
- Giampaolino P, Della Corte L, Di Filippo C, Mercurio A, Vitale SG, Bifulco G. Office hysteroscopy in the management of women with postmenopausal bleeding. *Climacteric*. 2020;23(4):369-75. [[Crossref](#)] [[PubMed](#)]
- Uno LH, Sugimoto O, Carvalho FM, Bagnoli VR, Fonseca AM, Pinotti JA. Morphologic hysteroscopic criteria suggestive of endometrial hyperplasia. *Int J Gynaecol Obstet*. 1995;49(1):35-40. [[Crossref](#)] [[PubMed](#)]
- Bar-On S, Ben-David A, Rattan G, Grisaru D. Is outpatient hysteroscopy accurate for the diagnosis of endometrial pathology among perimenopausal and postmenopausal women? *Menopause*. 2018;25(2):160-4. [[Crossref](#)] [[PubMed](#)]
- Torrejon R, Fernandez-Alba JJ, Carnicer I, Martin A, Castro C, Garcia-Cabanillas J, et al. The value of hysteroscopic exploration for abnormal uterine bleeding. *J Am Assoc Gynecol Laparosc*. 1997;4(4):453-6. [[Crossref](#)] [[PubMed](#)]
- Loverro G, Bettocchi S, Cormio G, Nicolardi V, Porreca MR, Pansini N, et al. Diagnostic accuracy of hysteroscopy in endometrial hyperplasia. *Maturitas*. 1996;25(3):187-91. [[Crossref](#)] [[PubMed](#)]
- Garuti G, De Giorgi O, Sambruni I, Cellani F, Luerti M. Prognostic significance of hysteroscopic imaging in endometrioid endometrial adenocarcinoma. *Gynecol Oncol*. 2001;81(3):408-13. [[Crossref](#)] [[PubMed](#)]
- Campo R, Molinas CR, Rombauts L, Mestdagh G, Lauwers M, Braekmans P, et al. Prospective multicentre randomized controlled trial to evaluate factors influencing the success rate of office diagnostic hysteroscopy. *Hum Reprod*. 2005;20(1):258-63. [[Crossref](#)] [[PubMed](#)]
- Zhang Y, Wang Z, Zhang J, Wang C, Wang Y, Chen H, et al. Deep learning model for classifying endometrial lesions. *J Transl Med*. 2021;19(1):10. [[Crossref](#)] [[PubMed](#)] [[PMC](#)]