

Ovarian Pregnancy: Case Report

Ovaryan Gebelik

Hale GÖKSEVER ÇELİK,^a
Recep Emre OKYAY,^a
Didem SOYSAL,^a
Meral KOYUNCUOĞLU^b

Departments of
^aObstetrics and Gynecology
^bPathology,
Dokuz Eylül University Faculty of Medicine,
İzmir

Geliş Tarihi/Received: 11.02.2011
Kabul Tarihi/Accepted: 29.04.2011

Yazışma Adresi/Correspondence:
Hale GÖKSEVER ÇELİK
Dokuz Eylül University Faculty of Medicine,
Department of Obstetrics and
Gynecology, İzmir,
TÜRKİYE/TURKEY
hgoksever@yahoo.com

ABSTRACT Ectopic pregnancy is location of gestational sac in any location other than uterine cavity. The fallopian tube is the most common site of ectopic implantation. Ovarian ectopic pregnancy is a rare form of ectopic pregnancy, with an estimated incidence ranging from 0.5% to 3% of the extrauterine pregnancies. Diagnosis of ovarian pregnancy is too difficult and it is many times an intraoperative diagnosis. Diagnosis can be made only with surgery and microscopic examination of tissue specimens. Surgery presently remains the mainstay of treatment for ovarian ectopic pregnancies. We present a 31-year-old woman with ruptured ovarian pregnancy who underwent laparoscopic ovarian wedge resection. She was normal on gynecologic examination except sensation on lower abdominal quadrants. Her vital signs and physical examination were normal. Transvaginal ultrasound examination revealed an image on right adnexial region that was suitable with ruptured ectopic pregnancy. Histopathological examinations of the tissue specimens revealed ovarian pregnancy.

Key Words: Ectopic pregnancy; laparoscopy

ÖZET Ektopik gebelik tanımı, gestasyonel kesenin uterin kavite dışında herhangi bir yerde yerleşimi ile yapılmaktadır. Ektopik implantasyonun en sık yerleşim yeri, fallopian tüplerdir. Ovaryan ektopik gebelik, insidansı %0,5 ile %3 arasında değişmekle birlikte ektopik gebelikler arasında en nadir görülen formdur. Ovaryan ektopik gebelik tanısını özellikle cerrahi öncesi koymak oldukça zordur, çoğunlukla operasyon esnasında tanı almaktadır. Tanısı sadece cerrahi yolla ve doku örneklerinin mikroskopik incelenmesiyle konulmaktadır. Cerrahi tedavi, günümüzde ovaryan ektopik gebeliğin asıl ve esas tedavisi olarak gözükmektedir. Bu yazıda, 31 yaşında laparoskopik yolla overin wedge rezeksiyonu yapılmış rüptüre ovaryan ektopik gebelik olgusu sunulmaktadır. Batında alt kadrantlardaki hassasiyet dışında hastanın jinekolojik muayenesi normaldi. Vital bulgular ve fizik muayene normaldi. Transvajinal ultrasonografik incelemede sağ adneksiyal bölgede rüptüre ektopik gebelikle uyumlu görünüm izlendi. Doku örneklerinin histopatolojik incelenmesi ile ovaryan ektopik gebelik tanısı konulmuştur.

Anahtar Kelimeler: Ektopik gebelik; laparoskopi

Türkiye Klinikleri J Gynecol Obst 2012;22(3):184-7

An ectopic pregnancy is a complication of pregnancy in which the pregnancy implants outside the uterine cavity. They are dangerous for the mother, internal bleeding being a common complication. Most ectopic pregnancies occur in the fallopian tube (so-called tubal pregnancies), but implantation can also occur in the cervix, ovaries and abdomen. Detection of ectopic pregnancy in early gestation has been achieved

mainly due to enhanced diagnostic capability. An ovarian pregnancy is differentiated from a tubal pregnancy by the Spiegelberg criteria. **These criteria are: 1) an intact ipsilateral tube, clearly separate from the ovary, 2) a gestational sac occupying the position of the ovary, 3) a gestational sac connected to the uterus by the uteroovarian ligament, 4) ovarian tissue in the wall of the gestational sac.**¹ The diagnosis of an ovarian ectopic pregnancy is seldom made before surgery. At the time of surgery, it is diagnosed when a haemorrhagic mass is seen attached to one of the ovaries in the presence of normal looking fallopian tubes. With early detection and good surgical techniques the amount of ovarian tissue lost will be insignificant and the resulting pelvic adhesions will be minimal. Surgery presently remains the mainstay of treatment for ovarian ectopic pregnancies.

CASE REPORT

A 31-year-old woman was admitted to our clinics with pain on pelvic region that had developed acutely. She has been married for two years. Her medical and family histories were unremarkable. Her menstrual cycle was normal and her last menstrual period was eight weeks ago. She had no child, no abortus or curettage. She and her husband had not used any contraception and they had wanted to have a baby. Last month, her pregnancy test was positive and she had not any complaint related to pregnancy. But with transvaginal or transabdominal ultrasound, any gestational sac or yolk sac was not observed yet. She had no vaginal bleeding, no vaginal discharge, no pain until that time. On that day, her pain associated with nausea developed acutely and increased substantially.

She was normal on gynecologic examination except sensation on lower abdominal quadrants. Her vital signs and physical examination were normal. She did not obtain any relief from her pain despite conservative treatment that was given in emergency service.

Transvaginal ultrasound examination revealed an image on right adnexial region that was suitable with ruptured ectopic pregnancy (Figure 1). Left adnexa was observed as normal. Endometrial thick-

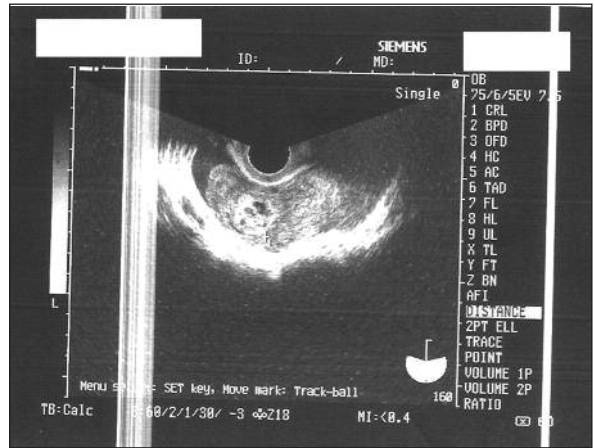

FIGURE 1: Ruptured ovarian ectopic pregnancy.

ness was 23.3 mm (Figure 2). The most importantly, there was widespread fluid in Douglas space (Figure 3). **Complete blood count showed that she was anemic** (hemoglobin: 8.9 g/dL, hematocrit: %25.8). Serum beta human chorionic gonadotropin (hCG) level was 13339 mIU/mL.

She had laparoscopic surgery under general anesthesia. There was common blood clots in abdominal cavity. At first, the blood clots were aspirated and abdominal cavity was cleaned. Then when right adnexial region was looked, the ruptured ectopic gestational sac was observed that was located to the right ovary. A bleeding mass of 2x1.5 cm was seen on the right ovary. A wedge resection of the right ovary was performed with preservation of most of the ovarian tissue. Right tube, left tube and left ovary were observed as normal. At the end

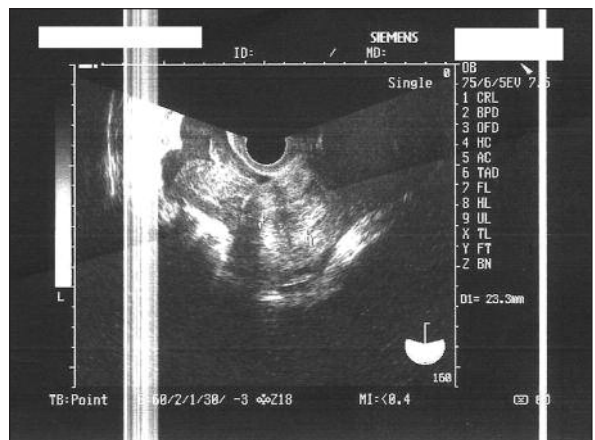


FIGURE 2: Endometrial thickness.

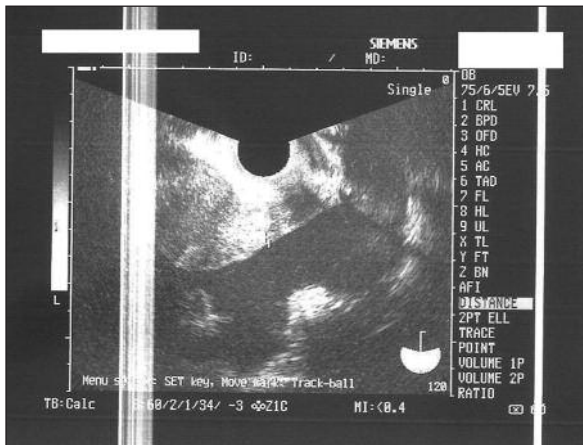


FIGURE 3: Common fluid in douglas space.

of the laparoscopic surgery, the dilatation and curettage was performed. The postoperative course was uneventful.

Histopathological examinations of the tissue specimens revealed ovarian pregnancy. Within ovarian tissue, chorionic villi and blood clots were found. The tissue from curettage was diagnosed to be endometrium with decidual changes, without chorionic villi or trophoblasts and Arias Stella phenomenon was showed.

The patient received 500 ml of red blood cell suspension. She had been asymptomatic postoperatively. Ultrasound examination did not reveal any pathology. Serum beta hCG level was 3928 mIU/mL 48 hours later, 361 mIU/mL one week later.

DISCUSSION

Ectopic pregnancy is location of gestational sac in any location other than uterine cavity. Ectopic pregnancy is associated with a classic triad of symptoms: delayed menses, irregular bleeding and lower abdominal pain. The fallopian tube is the most common site of ectopic implantation, accounting for more than 95% of all ectopic pregnancies. Ectopic pregnancies in other sites are relatively rare; approximately 3% of all ectopic implantations are ovarian and the small remainder is split between the cervix and abdominal sites.²

Ovarian ectopic pregnancy is a rare form of ectopic pregnancy, with an estimated incidence ranging from 0.5% to 3% of the extrauterine pregnan-

cies. Incidence has been estimated at 1 per 7000 pregnancies.³ Generally it occurs as a single event in an otherwise healthy woman. Several studies indicated that the risk was considerably higher for intrauterine device (IUD) users. The manner in which IUDs enhance the risk of ovarian pregnancy is unknown.⁴ de Vries et al reported that the type of IUD associated with ovarian pregnancy varies. The increasing association of ovarian pregnancies with copper IUDs seems simply to be related to the increasing prevalence of this type of IUD.⁵

Diagnosis of ovarian pregnancy is too difficult and it is many times an intraoperative diagnosis.⁶ Ultrasound examination and beta hCG assays are useful for diagnosis. But mostly, these pregnancies are understood as tubal ectopic pregnancies that are the most common type of ectopic pregnancy. Differentiation can be made only with surgery and microscopic examination of tissue specimens. To diagnose ovarian ectopic pregnancy correctly, the traditional criteria proposed by Spiegelberg in 1878 must be fulfilled. These criteria are: 1) an intact ipsilateral tube, clearly separate from the ovary, 2) a gestational sac occupying the position of the ovary, 3) a gestational sac connected to the uterus by the uteroovarian ligament, 4) ovarian tissue in the wall of the gestational sac. Our case was compatible with ovarian pregnancy according to Spiegelberg criteria. Sergent et al clarified the clinical features of ovarian pregnancy and showed the incapacity of Spiegelberg criteria to establish the diagnosis. They described criteria other than these described by Spiegelberg. These are serum beta hCG level ≥ 1000 IU/L and uterine vacuity at transvaginal ultrasonography; ovarian implication confirmed by surgical exploration, with bleeding, visualisation of chorionic villi or presence of an atypical cyst on the ovary, normal tubes and absence of serum beta hCG after treatment of the ovary.⁷

75% of ovarian pregnancies are terminated in first trimester, 25% of them are terminated in second and third trimester equally. Rarely, these pregnancies reach term without any problem. Dane et al reported an ovarian pregnancy at 32 weeks gestation that was understood as abdominal pregnancy before surgery. But at the laparotomy, the diagno-

sis of ovarian pregnancy was made and a live female infant, weighing 1400 gram was delivered.¹

Treatment of all known ovarian ectopic pregnancies has been surgical that is via laparoscopy or laparotomy. **Laparoscopy provides better visualization, shorter hospitalization and recovery time, also causes less tissue injury and adhesions.** The preferred therapeutic procedure is ovarian cystectomy or ovarian wedge resection.⁸ If this is impossible,

ipsilateral salpingoopherectomy may be performed. Fertility after surgery will be unaffected.⁹

In conclusion, the diagnosis of an ovarian ectopic pregnancy is seldom made before surgery.¹⁰ During surgery (laparoscopy or laparotomy), an ovarian pregnancy should be differentiated from a tubal pregnancy by the Spiegelberg criteria. Surgery presently remains the mainstay of treatment for ovarian ectopic pregnancies.

REFERENCES

1. Dane C, Dane B, Yayla M, Çetin A, Dural S, Tarlacı A. [An ovarian pregnancy with delivery of a live infant]. *Perinatal Journal* 2005;13(2): 125-7.
2. Speroff L, Fritz MA. Ectopic pregnancy. *Clinical Gynecologic Endocrinology and Infertility*. 7th ed. Philadelphia: Lippincott Williams and Wilkins; 2005. p.1275-302.
3. Riethmuller D, Sautière JL, Benoit S, Roth P, Schaal JP, Maillet R. [Ultrasonic diagnosis and laparoscopic treatment of an ovarian pregnancy. A case report and review of the literature]. *J Gynecol Obstet Biol Reprod (Paris)* 1996;25(4):378-83.
4. Chidiac A, Buka N, Ravinsky E, Garulla R. Ovarian ectopic pregnancy in association with a copper-7 intrauterine device in situ. *Fertil Steril* 1979;32(1):127-9.
5. de Vries K, Shapiro I, Degani S, Levitan Z, Mitrani A, Sharf M. Ovarian pregnancy in association with an intrauterine device. *Int J Gynaecol Obstet* 1983;21(1):65-70.
6. Salas Valien JS, Reyero Alvarez MP, González Morán MA, García Merayo M, Nieves Díez C. [Ectopic ovarian pregnancy]. *An Med Interna* 1995;12(4):192-4.
7. Sergent F, Mauger-Tinlot F, Gravier A, Ver-spyck E, Marpeau L. [Ovarian pregnancies: reevaluation of diagnostic criteria]. *J Gynecol Obstet Biol Reprod (Paris)* 2002;31(8):741-6.
8. Grimes HG, Nosal RA, Gallagher JC. Ovarian pregnancy: a series of 24 cases. *Obstet Gynecol* 1983;61(2):174-80.
9. al-Meshari AA, Chowdhury N, Adelusi B. Ovarian pregnancy. *Int J Gynaecol Obstet* 1993;41(3):269-72.
10. Altunyurt S, Güçlü S, Koçoğlu Ş, Yörükoğlu K. [Primary ovarian pregnancy: a case report]. *Türkiye Klinikleri J Gynecol Obst* 2000;10(3):172-3.