

Hysteroscopic treatment of intrauterine septum

INTRAUTERIN SEPTUMUN HISTEROSKOPIK TEDAVİSİ

Mustafa UĞUR, Havva ÇEÜKKANAT, Sertaç BATIOĞLU,
Yaşar ŞAHİN, Güzin NUHOĞLU, Oya GÖKMEN

Dr. Zekai Tahir Burak Women's Hospital

SUMMARY

Objective: To present the results of hysteroscopic septum resection of 41 patients including the technique used, complications, postoperative follow-up and pregnancy results.

Institution: Dr. Zekai Tahir Burak Women's Hospital, Ankara, Turkey.

Materials and methods: Between January 1993 and January 1994, forty-one patients underwent hysteroscopic division of the uterine septum monitored by concomitant laparoscopy. All procedures were performed under general anesthesia. Uterine cavity was distended with 1.5 % glycine and electrocautery was used for the incision of the septa. Recurrent abortion and primary infertility were the main indications for septum resection. Two of the forty-one patients had previous unsuccessful abdominal operations for the correction of the uterine anomaly. In one patient hysteroscopic division of the septum was followed by abdominal myomectomy for a concomitant intramural myoma in the same session. Intrauterine device was applied and sequential estrogen+progesterone therapy was given for 1 month in all patients.

Results: The procedure was carried out successfully in most of the cases which was verified by hysterosalpingography performed one month after the operation. No hemorrhage or infection was observed. One patient required a second hysteroscopic operation because a partial residual septum was observed on the post treatment hysteroqram. There were a total of 18 pregnancies after a mean period of 14.6 months following the procedure, of which 11(61.1%) were carried to term, 3(16.6%) ended with spontaneous abortion, and 4(23%) are ongoing.

Conclusion: Hysteroscopic metroplasty using electrocautery, is a safe and effective procedure for the treatment of uterine septum even in patients who had a previous laparotomy for the correction of the anomaly. It has few complications and satisfactory pregnancy results.

Key words: Metroplasty/Hysteroscopy/Uterine septum

T Klin J Gynecol Obst 1995, 5:105-110

Geliş Tarihi: 27.06.94

Yazışma Adresi: Mustafa Uğur

Atatepe Sitesi B-2 Blok No: 32 Ankara

T Klin J Gynecol Obst 1995, 5

ÖZET

Amaç: Histeroskopik septum rezeksiyonu uygulanan 41 hastanın semptomları, uygulanan teknik, komplikasyonları, post-operatif takip ve gebelik sonuçlarını araştırmak.

Çalışmanın Yapıldığı Yer: Dr.Zekai Tahir Burak Kadın Hastanesi Ankara

Materyal ve Metod: Ocak 1993 ve Ocak 1994 tarihleri arasında 41 hastaya genel anestezi altında laparoskopik eşliğinde histeroskopik septum kesilmesi operasyonu uygulandı. Distansiyon ortamı olarak %1.5 glisin kullanıldı; insizyon elektrokoter ile yapıldı. Primer infertilite ve tekrarlayan düşükler esas endikasyonları oluşturmaktaydı. Kırkbir hastanın ikisinde daha önceden abdominal yolla müdahale yapılmıştı. Bir hastada septum rezeksiyonunu takiben abdominal myomektomi uygulandı. İşlemden sonra tüm hastalara Rahim İçi Araç uygulandı ve bir ay süreyle estrogen+progesteron feda visi verildi.

Bulgular: Olguların çoğunda işlemden 1 ay sonra çekilen Histerosalpingografi de düzelleme saptandı. Kanama ve infeksiyon gözlenmedi. Bir hastada ise rezidüel septum sağlandığından ikinci bir histeroskopik müdahale yapıldı. Septum rezeksiyonundan sonra 12 hastada gebelik oluştu. Bunların 8 tanesi habituel abortus, 3 tanesi primer infertilite grubundaydı. Halen devam eden 10 gebelik mevcuttur.

Sonuç: Uterin septum nedeniyle elektrokoter kullanılarak uygulanan histeroskopik metroplasti, güvenli ve etkin bir cerrahi işlemdir. Komplikasyonların azlığı ve gebelik oranlarının yüksekliği bu işlemi daha önce öpere edilen hastalarda dahi tercih nedeni yapmaktadır.

Anahtar Kelimeler Metroplasti, Histeroskopi, Uterin septumu

T Klin Jinekolo Obst 1995, 5:105-110

Uterine malformations, resulting from partial or complete failure of the mullerian ducts to fuse or cana-
... interfere with normal reproduction in

about 20 to 25 % of the patients with these conditions (1). Of such uterine anomalies, the septate uterus is frequently associated with reproductive wastage (2).

Although uterine septa may be present in asymptomatic women who conceive and are delivered uneventfully, they may also be associated with infertility and menstrual disorders. Among symptomatic patients, the most common complaint is pregnancy failure, mostly with losses in the first and second trimesters. Until the use of hysteroscopy, surgical correction of the septate uterus was performed only by transabdominal metroplasty, using different techniques (3-5). The transabdominal route had the disadvantage of prolonged postoperative course, risk of postoperative pelvic adhesions, long waiting period before attempting conception and the necessity of cesarean section if pregnancy reaches full term.

Nowadays, operative hysteroscopy has become the procedure of choice in the management of intrauterine septum. Different instruments (scissors, electrocautery, laser) and distention mediums (CO₂, dextran, glycine) can be used. Although hysteroscopy is the treatment of choice for the correction of intrauterine septum, there are still arguments regarding the technique and instruments used, pre and postoperative hormonal therapy, use of intrauterine device (IUD) and in the management of other co-existing infertility related disorders such as, endometriosis, myoma uteri, adhesions or cervical incompetence.

This article describes our experience and the results of 41 patients during a 1 year period who were managed hysteroscopically for intrauterine septum.

MATERIALS AND METHODS

Forty-one patients underwent hysteroscopic division of uterine septa between January 1993 and January 1994. All operations were performed in the Dr. Zekai Tahir Burak Women's Hospital Reproductive Endocrinology Clinic. The patients ages ranged from 22 to 37 years (mean 27). The presenting complaint was, repeat pregnancy loss in 24 (58.5 %) and primary infertility in 15 (36.5%) patients. Two patients were infertile, for 2 and 4 years respectively after a term vaginal delivery.

Two patients, in whom HSG revealed septum persistence, had undergone an abdominal procedure for the correction of uterine septum previously.

All patients underwent a thorough evaluation for infertility or repeat abortion. Eight patients had complete septa and 33 patients had incomplete septa (Classes V a and Vb, respectively according to the American Fertility Society (AFS) Classification for uterine anomalies) (6). One patient with complete uterine septum had two separate cervixes, and 15 patients had broad septa (more than 3 cm at the base).

Septum was diagnosed preoperatively by hysterosalpingography (H.S.G.). Thirteen patients were erroneously diagnosed to have bicornuate uteri according to the HSG appearance, in whom intraoperative uterine septum diagnosis was established with the combined laparoscopy and hysteroscopy procedure (figure 1)

Associated symptoms and pelvic pathologies of the patients are listed in table 1. In 25 (60%) patients there was no co-existing pelvic or cervical pathology. No intrauterine adhesions were encountered except for the 2 pre-operated cases, in whom adhesions were observed in the fundal area during hysteroscopy.

Operations were carried out in the follicular phase of the cycle. No preoperative therapy was given to suppress the endometrium. Preoperative antibiotic prophylaxis was prescribed for 24 hours in all patients.

Under general endotracheal anesthesia and laparoscopic control, the cervix uteri was dilated to 9.5 Hegar and a rigid hysteroscope (model 27005, Storz Endoscopy, Tuttlingen, Germany) was introduced, mounted with a 26 F gauge resectoscope (Storz model 27040). Cuttingloop (model 27040 G) or coagulating electrode (model 27040 XH) were used for the division process. The uterine cavity was distended with a 1.5 % glycine solution. The fluid was introduced under manometric control with pressure generated by a pneumatic cuff around a 5 liter bag.

After cervical dilatation the hysteroscope was inserted to the level of external os. It was advanced into the cavity under direct vision and, after all of the cavity was explored, the endoscope was withdrawn to the level of the internal os. The inferior point of the septum was identified, and septa were lysed using 30-50 w/second cutting current. Incision was carried out cephalad making small cuts. When the base of the septum was reached, the relatively fibrous, bloodless septum gave way to more pink appearing myometrium and some bleeding was observed. The procedure was considered complete, when the hysteroscope could be moved freely across the top of the endometrial cavity without obstruction, and each ostium viewed. Then the hysteroscope was withdrawn and intrauterine device (Copper T-250 or Multiload Cu 250) was applied.

In one patient who had a complete septum with two separate cervixes, the septum was sectioned as described in other studies using a foley catheter (7,8). Postoperative therapy consisted of conjugated estrogen (Premarin 2.5 mg/day Fako-Turkey) for 30 days with medroxyprogesterone acetate (Farlutal 10 mg/day Deva-Turkey) added on days 20 to 30. After the first menstrual period, IUD were removed and control HSG were performed. We performed control hysteroscopy in addition to HSG for the first 10 patients, in order not to overlook an intrauterine synechia that is not demonstrated by HSG. We were convinced that control HSG and hysteroscopy correlation was good, and the-

refore gave up performing hysteroscopic control, unless an intrauterine pathology was suspected by HSG.

One patient underwent abdominal myomectomy after septum was incised, in the same session.

RESULTS

The mean operating time was 16 minutes (range 12-40 min.), which was calculated from the insertion to the removal of the hysteroscope. Distention medium used was, average 1200 ml (range 700-2600 ml). No significant intraoperative bleeding occurred to obscure the vision or necessitate to take additional measures. We had one case of uterine perforation, that occurred in the fundal area due to the pressure of the distention medium, just after the septal incision was completed. This patient required abdominal suturing of the perforation area.

Minimal vaginal bleeding and vague abdominal pain were the only postoperative complaints. No postoperative infection was observed (fever above 38 C, vaginal discharge, supra pubic tenderness). Average hospital stay was 24 hours postoperatively.

Technically, the thin subseptus was easiest to dissect while the broader and complete septa cases were more difficult. Hysteroscopic division using the pointed electrode was used in 25 patients, while resecting the septum with the cutting loop was performed in 15 patients. Although septum was resected more often in the cases of thicker and broader septa, adhesion formation did not occur in any of the techniques used. Figure 2 and 3 presents the pre and postoperative HSG of a patient, who underwent hysteroscopic septum division.

Operations which had been performed early in the proliferative phase, were quite satisfactory in terms of quality of vision and flow of medium. Nine of our procedures were performed late in the proliferative or luteal phase of the cycle for non-medical reasons. In 7

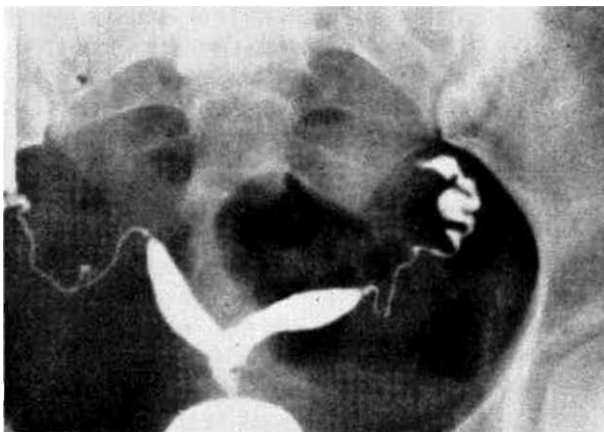


Figure 1.
Sekil 1.

T Klin J Gynecol Obst 1995, 5

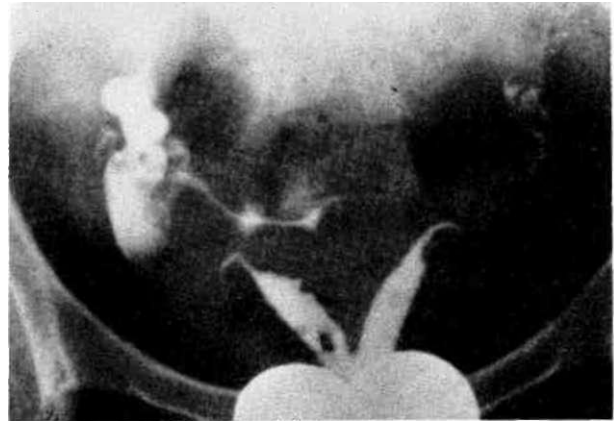


Figure 2.
Şekil 2.

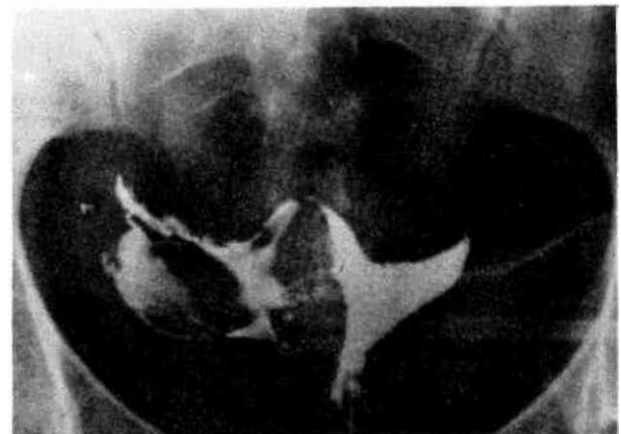

Figure 3.
Şekil 3.

of these patients, the vision was so troublesome that, sharp curettage of the cavity had to be performed before division of the septum was initiated. Post operative HSGs revealed satisfactory cavities (less than 1 cm notch) in most of the patients. In only 1 patient, a 2 cm fundal notch was present who underwent a repeat resection.

Forty-seven percent of the dysmenorrhic patients were symptom-free after the procedure. As we stated previously, polycystic ovaries (PCO), endometriosis and tubal pathologies were co-existing uterine septa in some of the patients. Ovulation induction using clomiphene was used for the PCO patients, while, fulguration of the endometriotic implants was used for the 7 patients who had endometriosis. Pelvic adhesions were laparoscopically, and 3 patients with severe tubal pathology were involved in the IVF programme. Patients who were thought to have cervical incompetence, (cervix dilated to 8 mm Hegar during the initial

Table 1. Symptoms and pelvic pathology in association with uterine septa

Tablo 1. Uterin septum ile birlikte görülen semptom ve pelvik patolojiler.

Dysmenorrhea	19(46.3%)
Abnormal uterine bleeding:	3(7.3%)
Polycystic ovaries:	13(31.7%)
Endometriosis	7(17%)
Pelvic adhesion	7(17%)
Tubal pathology	3(7.3%)
Cervical incompetence	6(14.6%)
Endometrial polyp	3(7.3%)
Myoma uteri	1 (2.4%)

Table 2. Pregnancies after the hysteroscopic septum resections.

Tablo 2. Histeroskopik septum rezeksiyonu sonrasında ki gebelikler.

	Number of pregnancies	Live birth	Spontaneous abortion	Ongoing
pregnancies				
Repeat Abortion	12	7*	2	3
Primary infertility	5	3	1	1
Secondary infertility	1	1		

*1 patient in this group had cervical cerclage in 14 weeks pregnancy.

evaluation) were scheduled for a cervical cerclage when they become pregnant.

There were a total of 18 pregnancies after a mean period of 14.6 months following the procedure (Table 2). One patient, who was infertile for 4 years after a term vaginal delivery, conceived 3 months after the septum resection. Two patients in the recurrent abortion group, and one patient in the primary infertility group aborted in the first trimester of their pregnancies. Up to now there have been 11 live births all ending with elective cesarean section. There are 4 ongoing pregnancies.

DISCUSSION

The uterine septum is composed of fibromuscular tissue characterized by being less cellular and more collagenous, with scant vasculature and a poorly developed endometrium. Probably, this structure is responsible for the increased incidence of repeat abortions and primary infertility. Early abortion may be due to placental ischemia, caused by the scant vasculature of the septum, while in the late pregnancy loss, the space-occupying effect of the septum is an additional feature. The association of the septum with primary infertility is rather difficult to explain, but may be related to implantation failure caused by a relative deficiency of estrogen and progesterone receptors.

In the past decade, hysteroscopic metroplasty has become the method of choice to correct septate uteri.

Although ultrasound or fluoroscopy guided division are also used, hysteroscopic septum division under direct visual control seems to be the most reliable method (9).

The differentiation between the two horns would be of particular help (10). In our series, 13 (31%) patients had the preoperative HSG diagnosis of bicornuate uterus, who were in fact uterine septum. As the treatment to be used is completely different, preoperative correct diagnosis is of particular importance. Ultrasonography and MRI may also be used in the differential diagnosis as an alternative to laparoscopy (11,12). In our series, we preferred to perform laparoscopy in every case, not only for the correct diagnosis, but also for documenting the coexisting pelvic pathologies, and if a complication occurs during the operation (ie. perforation) to reassure that, all is well in the abdominal cavity. Fayet mentioned that, laparoscopic monitoring during hysteroscopic cutting of the septum may not be necessary once experience is obtained (13). We feel, however, that laparoscopic monitoring is very helpful because of the above mentioned reasons.

Preoperative hormonal therapy seemed unnecessary because, with the use of glycine solution quality of vision was satisfactory and, electrocautery enabled quite bloodless operations, unless the procedure is performed early in the proliferative phase.

Resection or division of the septum yielded comparable results. Resection, by definition, requires additional operative intervention, thus, increasing the chance of bleeding or perforation. Resection, theoretically may be associated with less intrauterine synechia, for, the removal of a segment may avoid adhesion formation. On the other hand, incision exactly in the middle of the septum keeps the surgical procedure within the relatively fibrous, bloodless area and reduces the complications. Except for the cases of thick and broad septa, incision should be preferred to resection.

Postoperative HSG or hysteroscopy did not show any difference between the incision or resection group of patients in terms of intrauterine adhesion formation. We do not know whether post operative IUD application or estrogen therapy has any effect on this issue because we used IUD and estrogen in all patients.

There is a controversy on the use of IUD and estrogen+progesterone regimens postoperatively. The pioneers of hysteroscopic metroplasty favored the use of both measures by reasoning that, an intrauterine splint prevents adherence of the walls of the uterine cavity in the incised areas, and that, estrogens induce endometrial growth, which promotes epithelization of the retracted septal walls (14).

Valle and Sciarra prescribed post operative hormonal therapy but did not insert an IUD after division of the septum, because they did not observe adhe-

sions and they considered that, the chance of both uterine and tubal infection was decreased, if one avoided placing a foreign body in the uterus (15). Other authors have suggested either using or avoiding both ancillary measures (16-18). Of the cases presented in this article, no complication could be attributed to the use of either IUD or estrogen therapy, (infection, bleeding or adhesion formation).

With the availability of hysteroscopic approach, the indications of surgical correction for this anomaly have been more liberalized. We performed the procedure in 10 patients with less than 3 abortions who normally wouldn't be called habitual abortion. We have 4 pregnancies and 3 live births in this particular group of patients. If the septum, by exclusion remains the only abnormality, we believe that one shouldn't hesitate to eliminate it. The same rule applies for the primary infertile patients, or to patients who had a previous term delivery.

Previous unsuccessful abdominal metroplasty was another indication for hysteroscopic repair. In our series, intrauterine and pelvic adhesions were observed more frequently among this group of patients. In addition to this, even if an abdominal procedure was required for another indication (myomectomy in 1 patient), septum division was done through hysteroscopy. We believe that, the shortest access to the septum results in least trauma to the surrounding structures.

The two important complications that occurred were due to excessive or incomplete cutting of the septum in our series, which is in consistent with the findings of other studies. (17,19) There incomplete resection. Other possible complications of hysteroscopic surgery like, Infection, hemorrhage, or the ones that result from the distention medium are not common in septum resection because of the simplicity of the procedure and the short operation time.

There are varying pregnancy and live birth rates after the procedure in the literature. Pregnancy rates are greatly influenced by the characteristics of the population (primary infertility or recurrent abortion group of patients, and the presence or absence of other co-existing pathologies). In the last 10 years, various authors have analyzed the pregnancy outcome after hysteroscopic metroplasty and reported live birth rates that ranged 57% to 100% (20-24) Our live birth rate of 61 % (four ongoing pregnancies are not included) is in consistent with these findings.

An unsettled question regarding the outcome of pregnancies after hysteroscopic metroplasties is that, excessive incision through the myometrium during septum resection, which results in uterine scar, may cause uterine rupture during pregnancy or in labor (23). Therefore, we preferred to perform elective cesarean section in our patients though vaginal delivery can be accomplished safely in most of the cases (25).

As the result of our experience we conclude that, hysteroscopic septum resection is an easy and safe procedure with few complications and satisfactory results.

Acknowledgement: We thank Mrs. Sally King For revising this article in English.

KAYNAKLAR

1. Rock JA, Jones HW. The clinical management of the double uterus. *Fertil Steril* 28:798,1977
2. Musich JR, Behrman S.J. Obstetric outcome before and after metroplasty in women with uterine anomalies. *Obstet. Gynecol* 52:63,1978
3. Jones HW. Reproductive impairment and the malformed uterus. *Fertil Steril* 36:137,1981.
4. Strassmann EO. Fertility and unification of double uterus. *Fertil Steril* 17:165,1966
5. Tompkins P: Comments on the bicornuate uterus and twinning. *Surg. Clin. North Am* 42:1049,1962
6. The American Fertility Society classifications of adnexal adhesions, distal tubal occlusion secondary to tubal ligation, tubal pregnancies, Mullerian anomalies and intrauterine adhesions. *Fertil Steril.* 49:944-956,1988
7. Rock JA Murphy A, Copper W. Resectoscopic techniques for the lysis of a class V complete uterine septum. *Fertil. Steril* 48:495-496,1987
8. Daly DC, Tohan N, Walters C, Riddick D. Hysteroscopic resection of the uterine septum in the presence of a septate cervix. *Fertil. Steril.* 39: 560-563,1983
9. Valle A, Lifchez S, Moise J. A simpler technique for reduction of uterine septum. *Fertil. Steril* 56:5,1991
10. Siegler A. Diagnosis of the bicornuate uterus. In: *Hysterosalpingograph* (ed Am Siegler) p: 123. Harper and Row, New York, London 1967.
11. Forstner R, Hricak H. Congenital malformations of the uterus and vagina. *Radiologie* 34:397-404,1994.
12. Fedele L, Ferazzi E, Dorta M, Vercellini P, Candiani GB. Ultrasonography in the diagnosis of double uteri. *Fertil Steril* 50: 361-364, 1988
13. Favez J. Comparison between abdominal and hysteroscopic metroplasty. *Obstet Gynecol* 68:399-403,1986
14. Israel R, March CM. Hysteroscopic incision of the septate uterus. *Am J. Obstet Gynecol* 149:66,1984
15. Valle RF, Sciarra JJ. Hysteroscopic treatment of septate uterus. *Obstet Gynecol.* 67:253,1986
16. Perino A, Mencaglia L, Hamou J. Hysteroscopy for metroplasty of uterine septa. *Fertil Steril* 48:321,1987
17. Decherney AH; Rusell JB, Graebe RA. Resectoscopic management of mullerian fusion defects. *Fertil Steril* 45: 726, 1986

18. Vercellini D, Fedele L, Arcaini L. Value of intrauterine device insertion and Estrogen administration after hysteroscopic metroplasty. *Journal of Reprod. Med.* 34: 7 447-450.1989
19. Vercellini P, Vendola N, Colombo A, Passadore C, Tresipidi L, Fedele L. Hysteroscopic metroplasty with resectoscope or microscissors for the correction of septate uterus. *Surg Gynecol Obstet* 176:439-443,1993
20. March CM, Israel R. Hysteroscopic management of recurrent abortion caused by septate uterus. *Am J Obstet Gynecol* 61: 392-397, 1987
21. Carach M, penella J, Ubeda A, Labastkja R. Hysteroscopic incision of the septate uterus: Scissors versus resectoscope. *Hum Reprod* 9:87-89, 1994
22. Choe JK, Baggish MS. Hysteroscopic treatment of septate uterus with Neodymium-YAGlaser. *Fertil Steril* 57:81-84. 1992
23. Labaugh ML, Bammel BM, Duke D, Webster BW. Uterine rupture during pregnancy in a patient with a history of hysteroscopic metroplasty. *Obstet Gynecol* 83:838-840, 1994
24. Chervenak FA, Neuwirth RS. Hysteroscopic incision of septate uterus. *Am J Obstet Gynecol* 141:351-353,1981
25. Fedele L, Arcaini L, Parazzini F, Vercellini P, di Nola G. Reproductive prognosis after hysteroscopic metroplasty in 102 women: Life table analysis. *Fertil Steril* 59: 768-772, 1993