

Coexistence of Tubo-Ovarian Abscess with Adnexal Torsion in a Virgin Patient with a History of 10 cm Endometrioma: Case Report

10 cm Endometrioma Öyküsü Olan Bir Virgo Hastada Tuboovaryen Apse ve Adneksiyel Torsiyon Birlikteliği

Erhan KARAALP,^a
Neşe YÜCEL,^a
Fuat DEMİRCİ,^b
Esra AYDIN,^a
Bilge ÖĞÜTÇÜOĞLU,^b
Birgül KARAKOÇ^b

^aDepartment of Obstetrics and Gynecology,
İstanbul Medeniyet University
Göztepe Training and Research Hospital,
^bClinic of Obstetrics and Gynecology,
Kadıköy Şifa Health Group,
İstanbul

Geliş Tarihi/Received: 04.04.2012
Kabul Tarihi/Accepted: 28.08.2012

Yazışma Adresi/Correspondence:
Erhan KARAALP
İstanbul Medeniyet University
Göztepe Training and Research Hospital,
Department of Obstetrics and Gynecology,
İstanbul,
TÜRKİYE/TURKEY
drerhankaraalp@hotmail.com

ABSTRACT Tubo-ovarian abscess and adnexal torsion are uncommon causes of gynecological emergencies. Here, we reported a case of coexistence of tubo-ovarian abscess with adnexal torsion in a virgin patient. Tubo-ovarian abscess can be diagnosed in women even if they are virgin or sexually inactive and large ovarian masses, no matter solid or cystic, must be treated when they are diagnosed. Although tubo-ovarian abscess and adnexal torsion are rare gynecological disorders in patients with lower abdominal pain, they are always have to be kept in mind for differential diagnosis.

Key Words: Abdominal abscess; torsion abnormality; sexual abstinence; endometriosis

ÖZET Tuboovaryen apse ve adneksiyel torsiyon jinekolojik aciller içinde nadir görülen durumlardır. Burada biz, virgo bir hastada tuboovaryen apse ve adneksiyel torsiyon birlikteliğini rapor ettik. Virgo ya da seksüel olarak inaktif durumda olsalar bile tuboovaryen apse kadın hastalarda görülebilir ve solid ya da kistik büyük ovaryen kitleler, tam konulduğu anda tedavi edilmelidir. Her ne kadar tuboovaryen apse ve adneksiyel torsiyon alt karın ağrısı ile gelen hastalarda nadir görülen jinekolojik problemler olsalar da ayırıcı tanıda mutlaka akılda tutulmalıdırlar.

Anahtar Kelimeler: Abdominal apse; torsiyon anormalliği; seksüel perhiz; endometriyoz

Türkiye Klinikleri J Gynecol Obst 2013;23(1):39-42

Tubo-ovarian abscess (TOA) and adnexal torsion are uncommon causes of gynecological emergencies.¹

TOA is a result of acute pelvic inflammatory disease that is caused by an infectious inflammatory mass including the fallopian tube, ovary and periton of the anterior abdominal wall where adnexal torsion is characterized as the rotating of adnexal organs on their pedicles compromising their blood supplies leading to stasis and venous congestion, haemorrhage and necrosis respectively.^{2,3}

In the literature, cases of TOA involving endometriomas have been reported, and women with stage 3-4 endometriosis have been found to have an increased existence of TOA.⁴ *E. coli* is more frequently isolated from abscess materials in patients with concomitant endometriosis than the patients with no endometriosis present.⁵

Otherwise, adnexal torsion usually occurs during reproductive age with an incidence of %3 of all gynecological emergencies. The clinical symptoms are non-specific and could be confused with other acute abdominal emergencies which can lead to a delay in diagnosis and surgical management. While the exact etiology of adnexal torsion is obscure, a pre-existing ovarian cyst is one of the major causes.⁶

Here, we reported a case of tubo-ovarian abscess with adnexal torsion in a virgin patient. To our knowledge, this is the first report of coexistence of a tubo-ovarian abscess with adnexal torsion occurring in a virgin female.

CASE REPORT

A 26 year old virgin patient is presented to our emergency department with lower abdominal pain and a 15-day history of nearly 10 cm endometrioma. She had no fever and she had no history of vaginal bleeding, diarrhea, constipation and urinary complaints. There was no history of any operation before. After consultation, acute appendicitis and renal colic were excluded by the department of general surgery and urology.

On examination, the patient was afebrile and her vital signs were stable. Abdominal examination revealed serious tenderness on palpation in right lower quadrant. Deep palpation on this side provoked abdominal defense. Vaginal examination and vaginal ultrasound were not performed because of intact hymen. On abdominal ultrasound scan, 10.3x10.2 cm solid-cystic right adnexial mass extending to cul-de-sac was seen with no detectable periappendicular inflammation and bowel dilatation or ascites. Free fluid in the pouch of douglas was also visible (Figure 1).

The Colour Doppler sonogram did not demonstrate any significant information. The laboratory workup showed a white blood cell count of 15,700/mm³, haemoglobin of 10.2 g/dl, hematocrit 31.6%, c-reactive protein of 22.0 mg/dl whereas liver-kidney enzymes and ionogram were within the normal range. Urine analysis showed normal parameters. With the provisional diagnosis of ad-

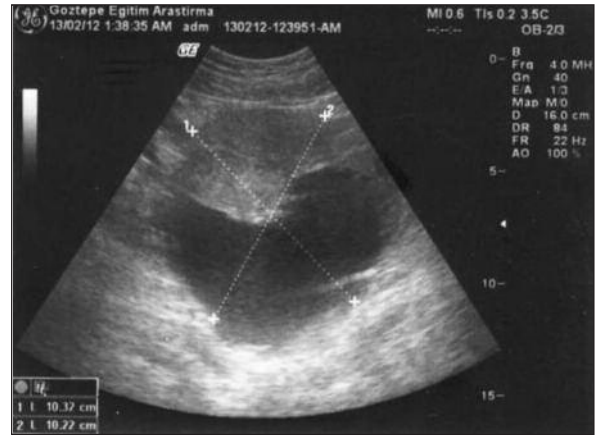

FIGURE 1: Abdominal ultrasound view, a solid-cystic right adnexial mass.

nexal torsion, emergency laparotomy was performed under general anaesthesia with Phaneustiel incision. Minimal blood-stained dirty-yellow and bad smelling peritoneal fluid was noted on opening the abdomen. The operative findings revealed nearly 8x8 cm right ovarian abscess neighbouring a gangrenous part and had undergone torsion three times on its pedicle ovarian tissue, right hydrosalpinx, and no pelvic adhesions (Figure 2).

The left adnexia was normal in appearance and the appendix was intact. After decision that untwisting the adnexa will be ineffectual because of the extensive abscess and widespread necrosis, a right salpingo-ovariectomy was performed. Intraoperative spill of the abscess cavity occurred, so the pelvis was copiously irrigated. A hemovac drain was placed to the pouch of douglas at the end of the operation. The material was sent to pathology for examination. Her histopathology report demonstrated acute inflammation involving the right fallopian tube and ovary and gangrenous ovarian part next to the hydropic tube. The culture of the abscess revealed *E. coli*. The patient, experiencing an uneventful postoperative period, was discharged from the hospital after six days of entrance.

MANAGEMENT

Postoperatively, the patient was treated with intravenous (IV) sulperazone 2x1 g for five days. In

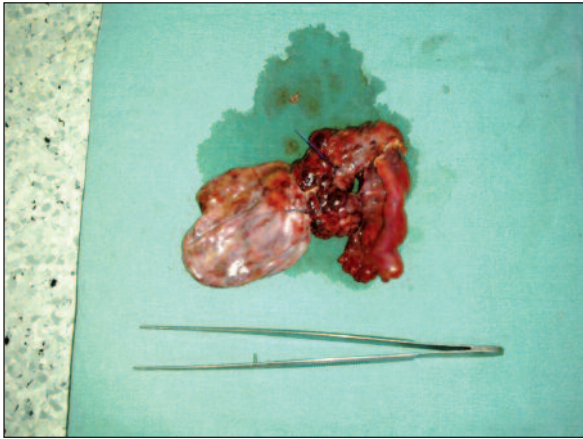


FIGURE 2: Macroscopic view, note the empty abscess sac, hydrosalpinx and torsion gangrenous part of the material.

(See for colored form <http://jinekoloji.turkiyeklinikleri.com/>)

the progress, vital signs were stable, C-reactive protein decreased to 3,0 g/dl, white blood cell count regressed to 8,800/mm³. The patient was discharged with oral amoxicillin-clavulanat therapy on post-operative day 6.

DISCUSSION

Usually, TOA spreads mainly through an ascending mechanism, although other ways of spread (hematogenous, lymphatic, direct etc.) are possible. In this case, TOA formation may seed via hematogenous infection. Infection extending from another nearby organ was not likely in this patient because there was no evidence of diverticulitis or appendicitis. Hematogenous infection is much less likely apart from exceptional cases, such as tuberculosis. However, there was either no evidence of tuberculosis infection found in this case.⁷

Otherwise, the development of TOA among women with endometriomas may be due to an increased susceptibility of an infection, particularly in the altered immune environment seen with ec-

topic endometrial glands and stroma, although there are no epidemiologic data available to support this theory. Also, previous surgical procedures involving the pelvic organs have been found to increase the risk of TOA formation in patients with endometriosis. Interestingly, in this patient, TOA was occurred although she is sexually inactive that the main route ascending mechanism was not thought priorly and she had no previous abdominal operation for inseminating microorganisms directly.^{8,9}

From past to present, laparoscopic surgery is admitted as a gold standard in almost all gynecologic procedures. So, laparoscopic approach could be thought as the first choice as if the patient was stable for hemodynamics. Furthermore, a long period usage of antibiotic therapy and leaving tuba with ovary could be an other way of treatment if no necrosis was found.

More study is necessary to illuminate tubo-ovarian abscess pathogenesis in sexually inactive young women and since the diagnosis is essential as it maintains a conservative approach, professionals have to be educated seriously in diagnosis of tubo-ovarian abscess and adnexal torsion also.

CONCLUSION

This case proves that tubo-ovarian abscess can be diagnosed in women although they are virgin or sexually inactive, and, large ovarian masses, no matter solid or cystic, must be treated when they are diagnosed. Although tubo-ovarian abscess and adnexal torsion are rare gynecological cases in patients with lower abdominal pain, they are always have to be kept in mind for differential diagnosis to be able to save adnexal structures like tube and ovary, and also to save fertility.

REFERENCES

1. Lin YH, Hwang JL, Seow KM, Chong KM, Huang LW. Tubo-ovarian abscess with septic shock in a case of endometrioma following diagnostic hysteroscopy. *Taiwan J Obstet Gynecol* 2010;49(3):359-60.
2. Onan MA, Taskiran C, Karabacak O, Acar A, Korucuoglu U, Tiras B. Retrospective analysis of laparoscopically treated cases of tubo-ovarian abscess. *Turkiye Klinikleri J Med Sci* 2009;29(4):872-6.
3. Kavoussi SK, Pearlman MD, Burke WM, Lebovic DI. Endometrioma complicated by tubo-ovarian abscess in a woman with bacterial vaginosis. *Infect Dis Obstet Gynecol* 2006;2006:84140. doi: 10.1155/2006/84140.
4. Kubota T, Ishi K, Takeuchi H. A study of tubo-ovarian and ovarian abscesses, with a focus on cases with endometrioma. *J Obstet Gynaecol Res* 1997;23(5):421-6.
5. Dewitt J, Reining A, Allsworth JE, Peipert JF. Tuboovarian abscesses: is size associated with duration of hospitalization & complications? *Obstet Gynecol Int* 2010;2010:847041.
6. Giulini S, Dante G, Xella S, La Marca A, Marsella T, Volpe A. Adnexal Torsion during Pregnancy after Oocyte In Vitro Maturation and Intracytoplasmic Sperm Injection Cycle. *Case Report Med* 2010;2010. doi:10.1155/2010/141875.
7. Tohya T, Yoshimura T, Onoda C. Tubo-ovarian abscess occurring 16 years after supracervical hysterectomy. *Infect Dis Obstet Gynecol* 2003;11(3):167-9.
8. Toglia MR, Schaffer JI. Tubo-ovarian abscess formation in users of intrauterine devices remote from insertion: a report of three cases. *Infect Dis Obstet Gynecol* 1996;4(2):85-8.
9. Chen MJ, Yang JH, Yang YS, Ho HN. Increased occurrence of tubo-ovarian abscesses in women with stage III and IV endometriosis. *Fertil Steril* 2004;82(2):498-9.