

A 17 – Week Tubal Pregnancy

17 HAFTALIK TUBAL GEBELİK

Mert GÖL*, Çetin AYDIN*, Cenk GÜVEN*, Ali BALOĞLU*

*Assoc.Prof., İzmir Atatürk Training and Research Hospital Obstetrics and Gynecology Department 1st Clinic, İZMİR

Summary

Objective: In this case report we presented a 20 – year - old woman with a 17 – weeks tubal pregnancy, who was asymptomatic in early gestational weeks, but had laparotomy for acute abdomen in the advanced gestational week. Our aim was to make clear that ectopic pregnancies can be asymptomatic even in advanced gestational weeks, and tried to discuss encountered diagnostic and surgical problems in these cases.

Institution: Izmir Atatürk Research and Training Hospital, 1st Clinic of Obstetrics and Gynecology.

Results: At laparotomy it was revealed that ampullary portion of the left fallopian tube was ruptured and there was a well developed placenta inside. The right fallopian tube was normal and the uterus was in six gestational weeks. There was a fetus lying in the pelvis, attached to the placenta with the umbilical cord. Also there was severe hemorrhage in the abdomen. We delivered a well developed stillborn infant, weighing 300 gr, and measuring 17 cm (crown to heel). Left fallopian tube with the placenta was removed by salpingectomy. The patient had an uneventful postoperative course and was discharged on the fifth postoperative day.

Conclusion: It should be kept in mind that ectopic pregnancies can be seen in advanced gestational weeks. Ectopic pregnancy should be in the differential diagnosis of acute abdomen in pregnant women, even in advanced gestational weeks. Emergent surgery is the choice of treatment in most of the patients.

Key Words: Tubal pregnancy, ectopic pregnancy

T Klin J Gynecol Obst 2003, 13:241-244

Özet

Amaç: Bu vaka taktiminde 20 yaşında hamile bir kadında erken gebelik haftasında bulgu vermeyen, fakat ilerlemiş gebelik haftasında akut batın nedeniyle laparotomi yapılan, 17 haftalık tubal gebelik olgusu sunuldu. Amacımız ektopik gebelik olgularının ileri haftalara kadar semptom vermiyebileceğini belirtmek ve bu olgularda tanı koymada ve cerrahide karşılaşılan problemleri tartışmaktır.

Çalışmanın Yapıldığı Yer: İzmir Atatürk Eğitim ve Araştırma Hastanesi, 1. Kadın Hastalıkları ve Doğum Servisi.

Bulgular: Laparotomi sırasında sol tuba ampullar bölgenin rüptüre olduğu ve içinde plasentanın bulunduğu saptandı. Sağ tuba normal görünümdeydi ve uterus yaklaşık 6 haftalık gebelik cesametindeydi. Batın içinde plasentaya umbilikal kordon ile bağlı bir fetus mevcuttu. Ayrıca batın içinde yaygın kanama izlendi. Baş – topuk mesafesi 17 cm olan ve 300 gr ağırlığındaki ölü infant doğurtuldu. Sol fallopian tüp plasentayla birlikte salpenjektomi yapılarak çıkarıldı. Operasyon sonrası dönemi hasta sorunsuz olarak geçirdi ve 5. günde taburcu oldu.

Sonuç: Ektopik gebeliğin ileri gebelik haftalarında da görülebileceği akıldan çıkarılmamalıdır. Bu olgularda tanı koymak güç olabilir. İlerlemiş gebelik haftalarında olsa bile, akut batın nedeniyle başvuran gebe kadınlarda ektopik gebelik ayırıcı tanıda yer almalıdır. Acil cerrahi müdahale çoğu hastada uygulanan tedavi yöntemidir.

Anahtar Kelimeler: Tubal gebelik, Ektopik gebelik

T Klin Jinekoloj Obst 2003, 13:241-244

Ectopic pregnancy is an important health problem and still is the leading cause of maternal mortality in developing countries. Diagnosis of ectopic pregnancy continues to be a challenging problem for physicians, particularly in the second trimester of pregnancy. More than 98% of ectopic pregnancies are tubal and of these approximately 93% occur in the ampullary portion. If an ectopic pregnancy implants in the ampullary portion of the fallopian tube, the trophoblastic tissue rapidly invade through the epithelium of the endosalpinx and develop between the tubal lumen and serosa, and usually becomes symptomatic in the first

trimester and rarely progress to the second trimester (1). Ectopic pregnancies in advanced gestational weeks cause higher maternal morbidity and mortality rates, for this reason early diagnosis is imperative in these cases.

We report on a tubal ampullary pregnancy in the 17 th gestational week in a patient who was admitted to our emergency department with acute abdominal pain and vaginal bleeding. At laparotomy, the fetus was lying in the pelvis and attached inside of the ruptured ampullary portion of the left fallopian tube with the umbilical cord. The placenta was completely developed inside of the serosal surface

The aim of the present case report is to show that ectopic pregnancies can be seen in the second trimester of pregnancy. Ectopic pregnancy should be considered in the differential diagnosis of acute abdomen in a pregnant woman, even in advanced gestational weeks. Sonographic examination is imperative in the diagnosis of these cases.

Case

A 20 – year – old, nulliparous pregnant woman complained of vaginal bleeding and stabbing pain in the right lower quadrant of the abdomen, admitted to our emergency department. The pain was more than 2 weeks in duration and had severe intensity for the last two hours. Menses were regular and she did not have any menses for 17 weeks. She had been following in an out – patient clinic for routine antenatal care. Because of vaginal bleeding and abdominal tenderness, she was admitted to the same out – patient clinic, before she arrived at our hospital. She was told that she had missed abortion because of no cardiac activity in the sonographic examination. This was the only performed sonographic examination in the out – patient clinic.

Physical examination revealed that the patient was in mild distress. She had moderate rebound tenderness in both of the adnexal regions accompanying with nausea and vomiting. There was a vague of fullness in the left adnexal region with rebound tenderness. Bowel sounds were hypoactive and she had mild abdominal distention. Pelvic examination revealed bilateral pelvic tenderness (more severe on the left side), and also there was a 10 cm semi – solid left adnexal mass. The uterus was in four gestational weeks.

Hemoglobin and Hematocrit levels were 6.3 gm / 100 ml, and 21%, respectively. The blood pressure was 90 / 50 mmHg and she had mild tachycardia. Serum biochemical parameters were within the normal range. Diagnostic pelvic sonography showed an uterus without any sign of a fetus, severe intraabdominal fluid, and a right semi - solid adnexal mass which was 10 x 10 cm in diameter. Also a fetus which was approximately in 16 gestational weeks and with no cardiac activity, lying in the pelvis was seen in the sonographic examination.

Because the signs of acute abdomen established and the patient had collapsed, we performed an emergent laparotomy. Laparotomy revealed approximately 1000 ml of blood in the abdomen, and a ruptured left fallopian tube from the ampullar portion. The placenta was completely developed inside of the left fallopian tube (Figure 1). The uterus, the right fallopian tube and both of the ovaries were normal. We delivered a well developed stillborn infant, weighing 300 gr, and measuring 17 cm (crown to heel), which was lying in the pelvis and attached to the placenta with the umbilical cord (Figure 2). Left fallopian tube with




Figure 1. Ruptured ampullary portion of the fallopian tube. The placenta is seen inside of the ruptured part.

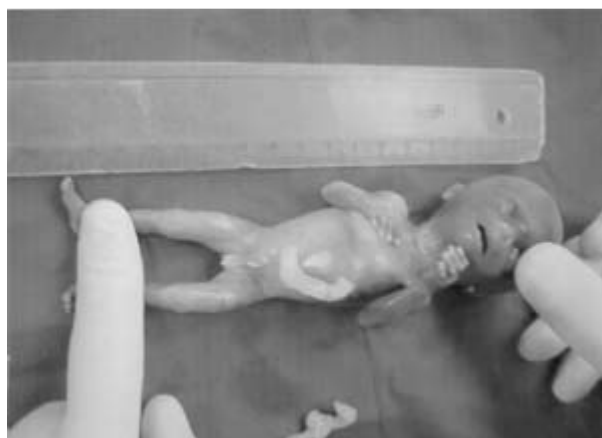

Figure 2. Well developed stillborn infant measuring 17 cm from crown to heel. The fetus was lying in the pelvic cavity and was attached to the placenta with the umbilical cord.

the placenta was removed by salpingectomy. The patient had an uneventful postoperative course and was discharged on the fifth postoperative day.

Discussion

In the present case we aimed to show that tubal pregnancies could be asymptomatic even in advanced gestational weeks. In these cases the diagnosis is usually difficult and rarely made before the laparotomy. Routine sonographic examination is imperative in the first trimester of the pregnancy to find out patients with ectopic pregnancy.

The occurrence of advanced tubal pregnancy is rare, but has higher fetal and maternal mortality rates. A review of tubal pregnancies by McElin and Randall (2) established that the fetus and the placenta be enveloped within the fallopian tube to such a degree that no other pelvic or intra – abdominal organs be involved in the formation of the sac. These authors also proposed that the diagnosis of advanced tubal pregnancies is rarely made before the laparotomy even with sonographic examinations. In another study it has been postulated that nidation to achieve an advanced stage in ectopic pregnancies, must occur along the mesosalpingeal attachment, adjacent to the ovary, because of the increased vascularity and elasticity (3). Although this statement is not true in this case, we believe that ampullary portion of the tuba could have enough elasticity for the development of a fetus until advanced gestational weeks.

There are different clinical manifestations of advanced tubal pregnancies in the literature. Peterson et al. (4) reported an advanced interstitial tubal pregnancy, followed by uterine cornual rupture during the induced mid - trimester abortion. These authors proposed that although the clinical and sonographic diagnosis of advanced ectopic pregnancies may be difficult, the possibility of ectopic pregnancy should be considered in cases with unsuccessful attempts of induced abortion. Another study by Glew et al. (5) showed an advanced ampullary pregnancy which was diagnosed only at laparotomy.

Advanced tubal pregnancies can reach to advanced gestational weeks even with a live fetus. A - 42 gestational weeks, unruptured tubal pregnancy with a dead fetus was reported by Chokroverty et al (6). Augensen (7) reported a case of tubal pregnancy going to term and resulting in a living child. This author also discussed the radiologic diagnostic signs of advanced tubal pregnancies, however he was not able to have diagnosis with the radiologic examination, and could only be able to reveal the diagnosis at cesarean section. Steyn et al. (8) reported an advanced tubal pregnancy who had fimbrial expulsion of the fetus and with complete placental development in the fallopian tube.

The diagnosis of advanced ectopic pregnancy could be a challenging problem. We believe that within the development of radiologic techniques and devices in the recent years, the diagnosis of ectopic pregnancies should not be made in advanced gestational weeks, even in asymptomatic patients. However despite the development of radiologic devices, particularly in ultrasonography, in the recent years, the diagnosis may be still difficult for inexperienced physicians on sonographic examination. For this

reason we believe that routine and careful sonographic examinations should be performed in every pregnant woman to find out patients with asymptomatic ectopic pregnancy, especially in high risk patients. In this case we were able to diagnose the advanced extrauterine pregnancy, as well as the correct location of the fetus with the sonographic examination. The final diagnosis at laparotomy was consistent with the findings of preoperative sonographic examination. However in this case, routine sonographic examination was not performed in the first trimester of pregnancy at the out - patient clinic. We believe that this is the main reason for late diagnosis in this case.

Also other diagnostic methods could be used in advanced ectopic pregnancies. Grullon et al. (9) reported a case of elevated maternal serum alpha – fetoprotein with an asymptomatic tubal pregnancy at 20 gestational weeks. These authors proposed that differential diagnosis of a second – trimester ectopic pregnancy should be considered in patients with an elevated maternal serum alpha – fetoprotein (MSAFP) levels. However we believe that lucid and elaborate sonographic examination of the pregnancy to exclude an advanced tubal pregnancy seems to be the best diagnostic modality. In support of this statement, Hubner et al. (10) also emphasized that routine use of sonography in the diagnosis of advanced ectopic pregnancies appears to be a justifiable method. Laparoscopy can also be performed for the diagnosis of advanced ectopic pregnancies in hemodynamically stable patients (11).

The treatment options for advanced tubal pregnancies is also challenging. Because the diagnosis of these patients is usually made late, the only treatment option is laparotomy. There are different surgical techniques in these patients during the operation. Kranzfelder et al. (12) reported a case of full – term tubal pregnancy with survival of the mother and the child, following salpingotomy and then salpingectomy to remove the fallopian tube with the placenta. A previous study proposed that more conservative approach could be performed after the diagnosis of advanced tubal pregnancy, to deliver a viable fetus after the 24 gestational week (13).

In summary, advanced ectopic pregnancy should be thought in the differential diagnosis of acute abdomen in the second trimester of pregnancy. We should perform routine sonographic examination to exclude an ectopic pregnancy in the first trimester of pregnancy. But despite the routine use of ultrasonography, the diagnosis could be still challenging in asymptomatic patients. Because of the high incidence in maternal morbidity and mortality of these cases, the treatment should immediately be performed with laparotomy.

REFERENCES

1. Budowick M, Johnson TRB, Genadry R. The histopathology of the developing tubal ectopic pregnancy. *Fertil Steril* 1980; 34: 169.
 2. McEllin T, Randall L. Tubal pregnancy. *Obstet Gynecol* 1951; 61: 130.
 3. Schokman C. Advanced tubal pregnancy; A case of survival of mother and baby. *Aust NZJ Obstet Gynecol* 1996; 6: 171.
 4. Petersen KR, Larsen GK, Norring K, Jensen Fr. Misdiagnosis of interstitial pregnancy followed by uterine cornual rupture during induced midtrimester abortion. *Acta Obstet Gynecol Scand* 1992; 5: 316 – 8.
 5. Glew S, Sivanesaratnam V. Advanced extrauterine pregnancy mimicking intra – uterine fetal death. *Aust NZJ Obstet Gynecol* 1989; 11: 450-1.
 6. Chokroverty M, Caballes R, Gear P. An ruptured tubal pregnancy at term. *Arch Pathol Lab Med* 1986; 5: 250-1.
 7. Augensen K. Unruptured tubal pregnancy at term with survival of mother and child. *Obstet Gynecol* 1983; 2: 259–61.
 8. Steyn P, Gebhardt G. Advanced extra – uterine pregnancy – a case of fimbrial expulsion of the fetus with complete placental development in the fallopian tube. *Eur J Obstet Gynecol Reprod Biol* 1999; 12: 167-8.
 9. Grullon K, Feldstein V, Lim K. Elevated maternal serum alpha – fetoprotein associated with an asymptomatic tubal pregnancy at 20 weeks gestation. *Obstet Gynecol* 1997; 11: 682-5.
 10. Hubner F, Haiges P, Reger S. The value of sonography in advanced, intact extra – uterine pregnancy. *Geburtshilfe Frauenheilkd* 1990; 7: 71–2.
 11. Harms E, Stressig R, Friol K. Unusual course of an advanced extra – uterine pregnancy. *Z Geburtshilfe Neonatol* 1999; 3: 86–9.
 12. Kranzfelder D, Beier H, Albert P. A full – term pregnancy with survival of mother and child. *Geburtshilfe Frauenheilkd* 1988; 5: 369-71.
 13. Aydoğdu M, Heilmann I, Schutte P, Trams G. Advanced ectopic pregnancy – clinical management. *Zentralbl Gynakol* 2001; 11: 585–7.
-

Geliş Tarihi: 15.07.2002

Yazışma Adresi: Dr.Mert GÖL
 Mithatpaşa cad. No:1131 / 4
 Üçkuyular, İZMİR
 mertgol@egenet.com.tr