

Investigation of TRPM7 Immunoreactivity as a Biomarker to Predict Treatment-Resistant Endometrial Hyperplasia: A Retrospective Case-Control Study

¹ Mesut Ali HALİŞÇELİK^a, ² Remzi ATILGAN^a, ³ Şehmus PALA^a, ⁴ Gökhan ARTAŞ^b,
⁵ Tuncay KULOĞLU^c

^aDepartment of Obstetrics and Gynecology, Fırat University School of Medicine, Elazığ, Türkiye

^bDepartment of Pathology, Fırat University School of Medicine, Elazığ, Türkiye

^cDepartment of Histology, Fırat University School of Medicine, Elazığ, Türkiye

ABSTRACT Objective: In our study, we investigated transient receptor potential melastatin 7 (TRPM7) immunoreactivity in pre- and post-treatment pathology samples of patients with endometrial hyperplasia (EH) who responded to progesterone therapy and were resistant to progesterone therapy. **Material and Methods:** In this retrospective, comparative and single-center case-control study, endometrial tissue TRPM7 immunoreactivity was evaluated in sections obtained from paraffin blocks of 60 cases diagnosed with EH and proliferative endometrium. Randomly selected proliferative endometrium group for control [(Group(G)1, n=20)], The first [(G2, n=20)] and second [(G3, n=20)] biopsy results of the group diagnosed with EH and recovered with progesterone therapy. The first [(G4, n=20)] and second [(G5, n=20)] biopsy results of the group that was diagnosed with EH but did not recover with progesterone treatment. SPSS version 22 program (SPSS Inc., Chicago, IL) was used for statistical analysis. Intergroup evaluation was carried out with one-way ANOVA and post-hoc tukey test. $p < 0.05$ values were considered statistically significant. **Results:** TRPM7 immunoreactivity was found to be significantly increased in G2, G4, and G5 compared to G1. However, no significant difference was observed between G2, G4, and G5. When compared with these groups, TRPM7 immunoreactivity was observed to be significantly decreased in G3, and it was observed to be similar to G1. **Conclusion:** In EH cases, the unchanged TRPM7 immunoreactivity before and after treatment may be an immunohistochemical biomarker for determining resistance to progesterone therapy.

Keywords: Biomarker; endometrial hyperplasia; immunohistochemistry; TRPM7

The sixth most frequent malignancy in women worldwide is endometrial cancer (EC).¹ There is currently no reliable EC screening program. Endometrial hyperplasia (EH) may be helpful for an early identification of EC because it is a precursor lesion of endometrioid adenocarcinoma, the most frequent type. An endometrial biopsy alongside a dilatation and curettage surgery should be carried out when there is a simultaneous risk of EC in order to rule out any cancers.^{2,3}

In EH, there is an increase in the gland-stroma ratio and excessive endometrial gland development as a result of ongoing estrogenic action on the endometrium, which is not under the influence of pro-

gesterone.⁴ EH can develop into endometrial cancer, but how quickly it does so depends on a variety of variables, including the degree of architectural abnormalities and whether or not nuclear atypia is present.⁵

The most popular medicinal strategy for treating women with EH is progesterone. Progesterone receptors are activated by progestin support, which causes endometrial stroma to decidualize and the endometrium to shrink.⁶ Progesterone treatment should be preferred in women with EH without atypia who want to preserve their fertility. Progesterone should not be used in women with thrombophilia, liver failure, pregnancy, progesterone receptor positive breast cancer, and allergic conditions.³

Correspondence: Remzi ATILGAN

Department of Obstetrics and Gynecology, Fırat University School of Medicine, Elazığ, Türkiye

E-mail: remzi_atilgan@hotmail.com



Peer review under responsibility of Journal of Clinical Obstetrics & Gynecology.

Received: 14 Dec 2022

Received in revised form: 21 Feb 2023

Accepted: 24 Feb 2023

Available online: 02 Mar 2023

2619-9467 / Copyright © 2023 by Türkiye Klinikleri. This is an open access article under the CC BY-NC-ND license (<http://creativecommons.org/licenses/by-nc-nd/4.0/>).

The plasma membrane's ion channels play a key role in cellular electrogenesis and electrical conduction. All fundamental cell behaviors necessary for the preservation of tissue homeostases, including apoptosis, proliferation, and differentiation, are carried out by these channels. Ion channels participate in these important processes via a number of key mechanisms, these include assuring fundamental signal transduction by maintaining membrane potential, controlling cell volume, and allowing ions into the cell. The main reasons of abnormal tissue growth are malignant cell transformation, defective differentiation, and decreased ability of cell death as a result of increased proliferation. Consequently, there may be uncontrolled proliferation and invasion.⁷ Some changes in physiological processes such as apoptosis, cell division, migration, invasion, and angiogenesis result in tumor growth. Transient receptor potential (TRP) channels and calcium homeostasis regulate these processes.⁸ TRP channels are involved in some physiological events as well as their relationship with some malignant and serious diseases. Some changes in TRP protein expression play an important role in cancer initiation and invasion.⁹

The aim of this study is to investigate TRP melastatin 7 (TRPM7) immunoreactivity in endometrial biopsies of cases with EH as an immunohistochemical marker to investigate its effectiveness in predicting the transition possibility from EH to EC.

MATERIAL AND METHODS

This retrospective case-control study was approved by the local Ethics Committee of Firat University (date: July 21, 2020, no: 11-04). In this study, the file details of all cases diagnosed with EH in the last 10 years at the Firat University Medical Faculty Hospital, Gynecology and Obstetrics Clinic were examined. Helsinki Declaration principles were followed in the study. Endometrial biopsy results of the cases diagnosed with EH without atypia were obtained pre-treatment and after 6-month progesterone (oral medroxyprogesterone acetate was given at a daily dose of 10 mg for 14 days every month for 6 months) treatment. In this way, biopsy results and file details

of 40 patients were obtained. Twenty randomly selected cases with proliferative endometrium as a result of the biopsy were determined as the control group. Paraffin blocks were obtained from all cases in the pathology laboratory. TRPM7 immunostaining was performed on the preparations obtained from all groups.

Randomly selected proliferative endometrium group for control [(Group(G)1, n=20)],

The first [(G2, n=20)] and second [(G3, n=20)] biopsy results of the group diagnosed with EH and recovered with progesterone therapy.

The first [(G4, n=20)] and second [(G5, n=20)] biopsy results of the group that was diagnosed with EH but did not recover with progesterone treatment.

IMMUNOHISTOCHEMICAL EVALUATION

Sections of 4-6 µm thickness obtained from paraffin blocks were placed on polylysine slides. Deparaffinized tissues were passed through a graded alcohol series. It was then boiled for 12 minutes in a microwave oven (750 W), and citrate buffer solution at pH 6 for antigen retrieval.¹⁰ After Ultra V Block (TA-125-UB, Lab Vision Corporation, USA) solutions were applied to prevent surface staining, tissues were incubated for 60 minutes with TRPM7 primary antibodies purchased from Abcam (Goat Anti-TRPM7 antibodies, ab729, Abcam, Cambridge, UK). After the application of primary antibodies, tissues were incubated with secondary antibodies (30 min) (biotinized anti-mouse/rabbit IgG, Diagnostic BioSystems, KP 50A, Pleasanton, USA), streptavidin alkaline phosphatase (30 min) (TS-060-AP, the Lab Vision Corporation, USA) and Fast Red Substrate System (TA-125-AF, the Lab Vision Corporation, USA). After the tissues were left for contrast staining with Mayer's hematoxylin, they were treated with PBS (phosphate buffered saline) distilled water and then sealed with a capping solution. Leica DM500 (Leica DFC295) brand microscope was used for microscopic examinations and photographs. Immunohistochemical scoring (Histoscore)=distribution [(0.1=under 25%; 0.4=26-50%; 0.6=50-75%; 0.9=76-100%)]×staining intensity [(0=no; +0.5=very little; +1=little; +2=medium; +3=very strong)].¹⁰

STATISTICAL ANALYSIS

Data were presented as mean±standard deviation. Statistical analyses were performed with the program SPSS 22.0 (IBM Corporation Armonk, NY, USA). Intergroup evaluation was carried out with one-way ANOVA and posthoc tukey test. $p < 0.05$ values were considered statistically significant.

RESULTS

With regard to TRPM7 immunoreactivity, a statistically significant increase was observed in G2 (Figure 1b) ($p < 0.001$), G4 (Figure 1d) ($p < 0.001$) and G5 (Figure 1e) ($p < 0.001$) compared to G1 (Figure 1a). However, TRPM7 immunoreactivity was similar among G2, G4, and G5 and no statistically significant difference was observed. When compared with these groups, statistically significantly decreased TRPM7 immunoreactivity was

observed in G3 (Figure 1c) ($p < 0.001$), and this decrease was similar to G1 ($p = 0.938$). Values for all groups are shown in Table 1.

TABLE 1: TRPM7 immunoreactivity histoscore in all groups (mean±standard deviation).

Groups	Histoscore (prevalence x severity)
G1	0,21±0,08
G2	0,75±0,14 ^a
G3	0,23±0,09 ^b
G4	0,72±0,19 ^a
G5	0,69±0,16 ^a

Values are given as mean±standard deviation; ^aCompared with the proliferative endometrium group; ^bCompared with G3 ($p < 0.05$); G1: Proliferative endometrium group; G2: First biopsy result of the group diagnosed with endometrial hyperplasia and improved with progesterone treatment; G3: Second biopsy result of the group diagnosed with endometrial hyperplasia and improved with progesterone treatment; G4: First biopsy result of the group diagnosed with endometrial hyperplasia and not improved with progesterone treatment; G5: Second biopsy result of the group diagnosed with endometrial hyperplasia and not improved with progesterone treatment.

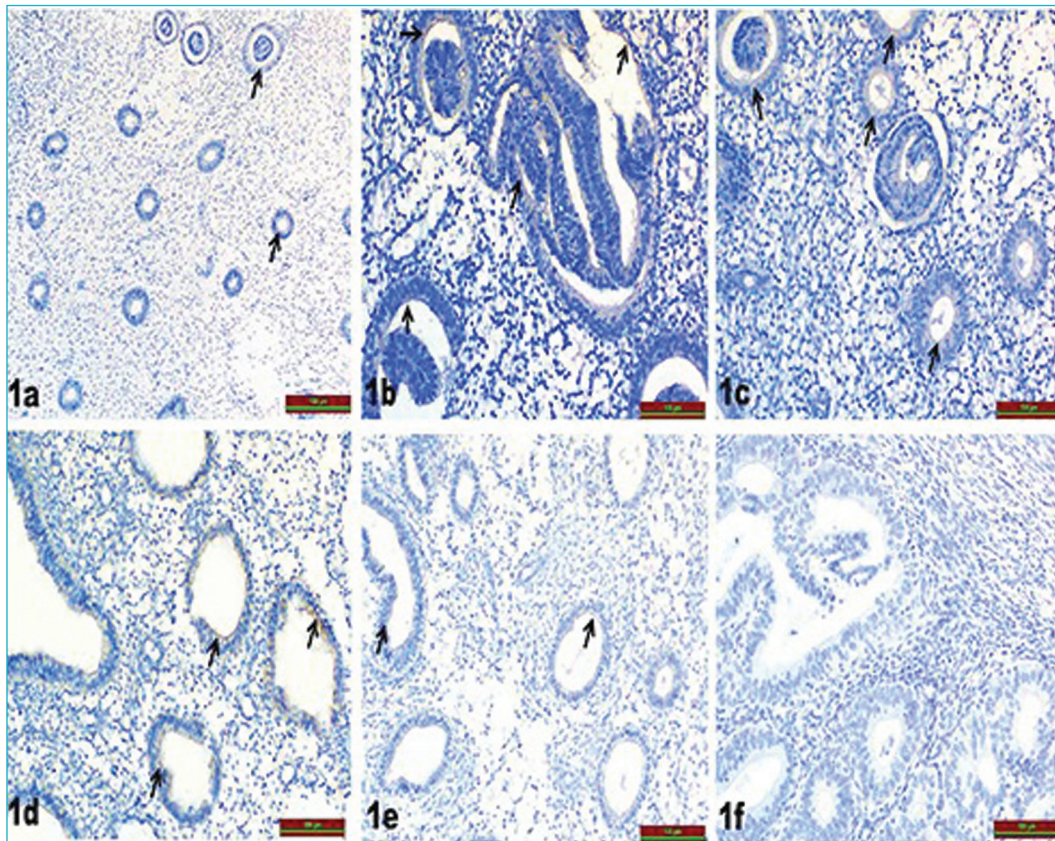


FIGURE 1: a: TRPM7 immune positive cells are observed in Group 1 (black arrow); b: Increased TRPM7 immune positive cells are observed in Group 2 (black arrow); c: Increased TRPM7 immune positive cells are observed in Group 3 (black arrow); d: TRPM7 immune positive cells are observed in Group 4 (black arrow); e: TRPM7 immune positive cells are observed in Group 5 (black arrow); f: Positive control.

DISCUSSION

Our research revealed that, in comparison to the proliferative endometrium group, TRPM7 immunoreactivity increased in all of our EH groups. We showed that, whereas TRPM7 immunoreactivity re-decreased in the group that responded well to progesterone treatment, the treatment-resistant group did not experience a change. The immunohistochemical marker TRPM7 immunoreactivity may be used to identify cases with resistant EH.

EH is an irregular proliferation of endometrial glands that usually precedes endometrioid-type endometrial cancer.² Since progestins promote endometrial cell death and counteract estrogen's growth-promoting effects, they are frequently utilized in conservative EH and early stage EC treatment.¹¹ Progestins are highly effective and safe agents in the treatment of EH without atypia. Oral progestins have a success rate of 85%, and intrauterine device that releases levonorgestrel-intrauterine device about 100%.³ However, a sizable minority of patients remain resistant to conventional therapy or relapse after remission, with a risk of developing an invasive disease.¹² Consequently, there has been an increase in interest in recent years in researching clinical, imaging, histological, and molecular aspects that may have an impact on the course of treatment.¹³ Every 3 to 6 months, endometrial samples should be taken to assess the therapeutic efficacy of progestin medication. A comprehensive follow-up is mandatory, especially in women with atypical EH. Premenopausal patients who want to maintain their fertility can stop taking progestin medication after three to 6 months if their endometrium can show regression and is histologically healthy.¹⁴ We performed endometrial sampling for our cases after 6 months of regular progesterone treatment.

To assess tissue markers used in the diagnosis, prognosis, and treatment of numerous diseases, immunohistochemistry is often utilized.¹⁵ Although several immunohistochemistry markers have been examined, their availability is still unclear.¹⁶ Progesterone was given to the participants in our study for 6 months to treat EH without atypia. Additionally, TRPM7 positivity was examined in light of the possibility of an immunohistochemical marker.

Calcium plays a major role in migration, adhesion, proliferation and neuroangiogenesis.¹⁷ Ion channels control these activities by changing intracellular calcium concentrations. TRP channels play an important role in proliferation, migration, adhesion and neuroangiogenesis.¹⁸ TRP channel expression in endometrial biopsies has been demonstrated to vary over the course of the menstrual cycle.¹⁹ Increased mRNA levels of TRPV2, TRPV4, TRPC1/4, TRPC6, TRPM4, and TRPM7 in human endometrial stromal cells indicate functional expression of these channels.¹⁹ We preferred TRPM7 ion channel activity in our study as a result of its strong relationship with proliferation from the TRP ion channels above.

It may be possible that the sex hormones estrogen and progesterone regulate particular TRP channels based on their distinctive mRNA expression patterns during the menstrual cycle.¹⁹ The transition from the silent phase to the spreading phase is likely made possible by TRPM7. Every menstrual cycle involves the proliferation and differentiation of stromal cells. Although earlier studies have suggested that TRPM7 is essential for proliferating cells, differentiated cells express less TRPM7.^{20,21} Since TRPM7 expression has also been found to decrease in differentiated cells in our investigation, the decrease in TRPM7 activity in our group in response to progesterone treatment suggests that irregular proliferation had also decreased and hyperplasia had regressed. Additionally, we showed in our study that among the group unresponsive to progesterone treatment, TRPM7 activity did not regress in comparison to the first biopsy results. This finding suggests that TRPM7 activity and the persistence of proliferation may be related. Yalçın et al. reported that there was a down-regulation in gene expression and that there was no immunohistochemistry difference between proliferative endometrium and EH without atypia in terms of TRPM7 activity.¹⁰ We demonstrated that there was a considerable increase in TRPM7 immunoreactivity in our EH group compared to our proliferative endometrium group, in contrast to Yalçın et al.'s findings.¹⁰ We may have seen a difference between these trials because we didn't include cases of atypic hyperplasia.

Independent examination of the methylome in each cellular compartment may shed light on the establishment of hormone therapy resistance in addition to the expression of hormone receptors that can mediate the therapeutic effects of progesterone in the stroma or epithelium. DNA methylation is an epigenetic alteration that has the potential to alter gene expression and turn healthy cells into cancerous cells.²² According to some research, these epigenetic modifications may contribute to the initiation or metastasis of cancer.²³ As earlier mentioned, it is obvious that the inability of hyperplasia to respond to treatment may also be due to epigenetic factors. For example, the relationship between insulin resistance and cell proliferation may be a potential therapeutic target in correcting hyperplasia and preventing endometrial cancer.²⁴ This link has been confirmed by numerous investigations, which also show that metformin is effective in inducing endometrial atrophy in benign endometrial proliferative disorders. According to a published study, 96% of women using metformin experienced atrophy, which led to the reversal of EH.²⁵ Among other suggested mechanisms of metformin's anti-cancer activities, there are direct effects on cell signaling pathways, such as inhibition of the mammalian target of rapamycin (mTOR), mitogen-activated protein kinase (MAPK) activity, and Akt activity. These pathways play a crucial role in both hyperplasia and malignant lesions in any tissue because they are engaged in cell proliferation. Given that metformin inhibits these pathways, cell proliferation will be inhibited and the likelihood of developing cancerous lesions will be reduced.²⁶ Many signaling pathways are regulated by TRPM7, such as the signal converter and activator of transcription 3, Notch, PI3K/Akt, and MAPK signaling pathways.²⁷ We believe that TRPM7 inhibition may also be effective in the regression of hyperplasia, similar to the potential of metformin to treat EH through the aforementioned mechanisms.²⁷ It has repeatedly been demonstrated that inhibiting TRPM7 prevents PC-3 cells from proliferating, migrating, and invading. Additionally, research has shown that therapy with carvedol, a non-selective TRPM7 inhibitor, greatly reduces prostate cancer cells' ability to proliferate, migrate, and invade.²⁸ Progestins are essential for

treating EC because they bind to the progesterone receptor, which prevents cell growth and triggers autophagy.²⁹ Long-term exposure to progesterone has been shown to increase resistance to therapy by activating the PIK3CA-AKT-mTOR signaling pathway and inhibiting autophagy.²⁷ Pharmacological suppression of the PIK3CA-AKT-mTOR pathway by RAD001 (everolimus) or mTOR degradation has been shown to re-sensitize progesterone-resistant cells to progesterone. Zhao et al. reported that progestin-resistant cells could be obtained by exposing EC cells to long-term MPA treatment.³⁰ However, MPA administration drastically reduces cell viability and proliferation, with the exception of progestin-resistant cells, and it also causes autophagy in parent Ishikawa cells. This implies that long-term progesterone administration can decrease progesterone receptor expression levels and activate compensatory pathways to promote cell proliferation and prevent autophagy. In our results, TRPM7 activity was also reduced in our hyperplasia cases that improved with progesterone. The aforementioned mechanisms may also be effective in this improvement. Nevertheless, further studies are needed to explain the persistence of high TRPM7 activity in our non-improved EH cases in comparison to the control group. Progesterone has been shown to inhibit TRPM7 expression and suppress cell proliferation in human cervical cancer HeLa cells. These results indicate that progesterone inhibits the proliferation of cervical cancer cells and suppresses TRPM7 expression and activity, converting acidotoxic cell death from necrosis to apoptosis.³¹

There are studies indicating the association of increased TRPM7 immunoreactivity with poor prognosis in various cancers. According to Rybarczk et al., high TRPM7 levels were linked to a poor prognosis in pancreatic ductal adenocarcinoma.³² Overexpression of TRPM7 in ovarian cancer, according to Wang et al., was related with a poor prognosis.³³ Sahni and Scharenberg showed that TRPM7 deficiency suppresses growth in cells, resulting in a secondary arrest in proliferation.³⁴ In addition, suppression of TRPM7 has been shown to induce growth and proliferation for some cell types.³⁵ The best molecular biomarker should be reliable and

reproducible. It should also indicate the transition between normal/benign and malignant and be reliable and usable in predicting this transition. Although there is no perfect biomarker that meets these conditions yet, studies are continuing. Some immunohistochemical markers have been studied to predict the progression of EH to malignancy.¹⁰ TRPM7 immunoreactivity can also be a reliable marker in the detection of resistant EH cases.

The limitations of our study are that it is a retrospective study with a small number of cases, and that atypia EH and endometrial cancers were not included in the study. Another limitation is that we did not evaluate advanced parameters that would prove the pathophysiological effects of TRPM7. These deficiencies can be eliminated in prospective planned studies. We could not follow up with our patients with non-improved hyperplasia for a longer period of time for ethical reasons, since, among these cases, the number of patients who wanted fertility and wanted their uteruses to be preserved was not high enough to create a statistical significance. Therefore, we could not obtain long-term endometrial biopsy results of our non-improved patients.

The strength of our study is the comparison of post-treatment biopsy results of our cases diagnosed with EH and treated. In other words, with the evaluation of TRPM7 immunoreactivity in the first and second biopsies of the same case, this study is the first in the literature. Thus, another strength of our study is showing that a single immunohistochemical evaluation can be an easy method to detect resistant EH cases.

CONCLUSION

The fact that TRPM7 immunoreactivity did not change post-treatment in comparison to pre-treatment in the same case may be an immunohistochemical marker indicating progression in determining resistance to progesterone treatment and progression in EH cases.

Source of Finance

During this study, no financial or spiritual support was received neither from any pharmaceutical company that has a direct connection with the research subject, nor from a company that provides or produces medical instruments and materials which may negatively affect the evaluation process of this study.

Conflict of Interest

No conflicts of interest between the authors and / or family members of the scientific and medical committee members or members of the potential conflicts of interest, counseling, expertise, working conditions, share holding and similar situations in any firm.

Authorship Contributions

Idea/Concept: Remzi Atılğan, Mesut Ali Halisçelik; **Design:** Remzi Atılğan, Mesut Ali Halisçelik; **Control/Supervision:** Mesut Ali Halisçelik, Remzi Atılğan; **Data Collection and/or Processing:** Mesut Ali Halisçelik, Gökhan Artaş, Şehmus Pala, Tuncay Kuloğlu; **Analysis and/or Interpretation:** Mesut Ali Halisçelik, Tuncay Kuloğlu, Gökhan Artaş; **Literature Review:** Şehmus Pala; **Writing the Article:** Mesut Ali Halisçelik; **Critical Review:** Remzi Atılğan, Şehmus Pala; **References and Fundings:** Mesut Ali Halisçelik, Remzi Atılğan; **Materials:** Gökhan Artaş, Tuncay Kuloğlu.

REFERENCES

- Bray F, Ferlay J, Soerjomataram I, Siegel RL, Torre LA, Jemal A. Global cancer statistics 2018: GLOBOCAN estimates of incidence and mortality worldwide for 36 cancers in 185 countries. *CA Cancer J Clin.* 2018;68(6):394-424. Erratum in: *CA Cancer J Clin.* 2020;70(4):313. [[Crossref](#)] [[PubMed](#)]
- Sanderson PA, Critchley HO, Williams AR, Arends MJ, Saunders PT. New concepts for an old problem: the diagnosis of endometrial hyperplasia. *Hum Reprod Update.* 2017;23(2):232-54. [[PubMed](#)] [[PMC](#)]
- Nees LK, Heublein S, Steinmacher S, Juhasz-Böss I, Brucker S, Tempfer CB, et al. Endometrial hyperplasia as a risk factor of endometrial cancer. *Arch Gynecol Obstet.* 2022;306(2):407-21. [[Crossref](#)] [[PubMed](#)] [[PMC](#)]
- Kurman RJ, Kaminski PF, Norris HJ. The behavior of endometrial hyperplasia. A long-term study of "untreated" hyperplasia in 170 patients. *Cancer.* 1985;56(2):403-12. [[Crossref](#)] [[PubMed](#)]
- Kurman RJ, Norris HJ. Evaluation of criteria for distinguishing atypical endometrial hyperplasia from well-differentiated carcinoma. *Cancer.* 1982;49(12):2547-59. [[Crossref](#)] [[PubMed](#)]
- Gunderson CC, Fader AN, Carson KA, Bristow RE. Oncologic and reproductive outcomes with progestin therapy in women with endometrial hyperplasia and grade 1 adenocarcinoma: a systematic review. *Gynecol Oncol.* 2012;125(2):477-82. [[Crossref](#)] [[PubMed](#)]
- Guinamad R, Sallé L, Simard C. The non-selective monovalent cationic channels TRPM4 and TRPM5. *Adv Exp Med Biol.* 2011;704:147-71. [[Crossref](#)] [[PubMed](#)]
- Kraft R, Harteneck C. The mammalian melastatin-related transient receptor potential cation channels: an overview. *Pflügers Arch.* 2005;451(1):204-11. [[Crossref](#)] [[PubMed](#)]
- Everaerts W, Gevaert T, Nilius B, De Ridder D. On the origin of bladder sensing: Tr(ι)ps in urology. *NeuroUrol Urodyn.* 2008;27(4):264-73. [[Crossref](#)] [[PubMed](#)]
- Yalçın E, Pala Ş, Atilgan R, Kuloğlu T, Önalın E, Artaş G, et al. Is there any difference between endometrial hyperplasia and endometrial carcinoma in terms of expression of TRPM2 and TRPM7 ion channels? *Turk J Med Sci.* 2019;49(2):653-60. [[Crossref](#)] [[PubMed](#)] [[PMC](#)]
- Chandra V, Kim JJ, Benbrook DM, Dwivedi A, Rai R. Therapeutic options for management of endometrial hyperplasia. *J Gynecol Oncol.* 2016;27(1):e8. [[Crossref](#)] [[PubMed](#)] [[PMC](#)]
- Gallo ID, Yap J, Rajkhowa M, Luesley DM, Coomarasamy A, Gupta JK. Regression, relapse, and live birth rates with fertility-sparing therapy for endometrial cancer and atypical complex endometrial hyperplasia: a systematic review and meta-analysis. *Am J Obstet Gynecol.* 2012;207(4):266.e1-12. [[Crossref](#)] [[PubMed](#)]
- Penner KR, Dorigo O, Aoyama C, Ostrzega N, Balzer BL, Rao J, et al. Predictors of resolution of complex atypical hyperplasia or grade 1 endometrial adenocarcinoma in premenopausal women treated with progestin therapy. *Gynecol Oncol.* 2012;124(3):542-8. [[Crossref](#)] [[PubMed](#)]
- Wei J, Zhang W, Feng L, Gao W. Comparison of fertility-sparing treatments in patients with early endometrial cancer and atypical complex hyperplasia: a meta-analysis and systematic review. *Medicine (Baltimore).* 2017;96(37):e8034. [[Crossref](#)] [[PubMed](#)] [[PMC](#)]
- Duraiyan J, Govindarajan R, Kaliyappan K, Palanisamy M. Applications of immunohistochemistry. *J Pharm Bioallied Sci.* 2012;4(Suppl 2):S307-9. [[Crossref](#)] [[PubMed](#)] [[PMC](#)]
- Travaglino A, Raffone A, Saccone G, Insabato L, Mollo A, De Placido G, et al. Immunohistochemical predictive markers of response to conservative treatment of endometrial hyperplasia and early endometrial cancer: a systematic review. *Acta Obstet Gynecol Scand.* 2019;98(9):1086-99. [[Crossref](#)] [[PubMed](#)]
- Capiod T. Cell proliferation, calcium influx and calcium channels. *Biochimie.* 2011;93(12):2075-9. [[Crossref](#)] [[PubMed](#)]
- Déliot N, Constantin B. Plasma membrane calcium channels in cancer: alterations and consequences for cell proliferation and migration. *Biochim Biophys Acta.* 2015;1848(10 Pt B):2512-22. [[Crossref](#)] [[PubMed](#)]
- De Clercq K, Held K, Van Bree R, Meuleman C, Peeraer K, Tomassetti C, et al. Functional expression of transient receptor potential channels in human endometrial stromal cells during the luteal phase of the menstrual cycle. *Hum Reprod.* 2015;30(6):1421-36. [[Crossref](#)] [[PubMed](#)]
- Ng NM, Jiang SP, Lv ZQ. Retrovirus-mediated siRNA targeting TRPM7 gene induces apoptosis in RBL-2H3 cells. *Eur Rev Med Pharmacol Sci.* 2012;16(9):1172-8. [[PubMed](#)]
- Lam DH, Grant CE, Hill CE. Differential expression of TRPM7 in rat hepatoma and embryonic and adult hepatocytes. *Can J Physiol Pharmacol.* 2012;90(4):435-44. [[Crossref](#)] [[PubMed](#)]
- Neal AS, Nunez M, Lai T, Tosevska A, Morselli M, Amneus M, et al. Expression of stromal progesterone receptor and differential methylation patterns in the endometrium may correlate with response to progesterone therapy in endometrial complex atypical hyperplasia. *Reprod Sci.* 2020;27(9):1778-90. [[Crossref](#)] [[PubMed](#)] [[PMC](#)]
- Chik F, Szyf M, Rabhani SA. Role of epigenetics in cancer initiation and progression. *Adv Exp Med Biol.* 2011;720:91-104. [[Crossref](#)] [[PubMed](#)]
- Clement NS, Oliver TR, Shiwani H, Sanner JR, Mulvaney CA, Atiomo W. Metformin for endometrial hyperplasia. *Cochrane Database Syst Rev.* 2017;10(10):CD012214. [[Crossref](#)] [[PubMed](#)] [[PMC](#)]
- Tabrizi AD, Melli MS, Foroughi M, Ghojzadeh M, Bidadi S. Antiproliferative effect of metformin on the endometrium—a clinical trial. *Asian Pac J Cancer Prev.* 2014;15(23):10067-70. [[Crossref](#)] [[PubMed](#)]
- Ben Sahra I, Regazzetti C, Robert G, Laurent K, Le Marchand-Brustel Y, Auberger P, et al. Metformin, independent of AMPK, induces mTOR inhibition and cell-cycle arrest through REDD1. *Cancer Res.* 2011;71(13):4366-72. [[Crossref](#)] [[PubMed](#)]
- Liu M, Inoue K, Leng T, Guo S, Xiong ZG. TRPM7 channels regulate glioma stem cell through STAT3 and Notch signaling pathways. *Cell Signal.* 2014;26(12):2773-81. [[Crossref](#)] [[PubMed](#)] [[PMC](#)]
- Luo Y, Wu JY, Lu MH, Shi Z, Na N, Di JM. Carvacrol alleviates prostate cancer cell proliferation, migration, and invasion through regulation of PI3K/Akt and MAPK signaling pathways. *Oxid Med Cell Longev.* 2016;2016:1469693. [[Crossref](#)] [[PubMed](#)] [[PMC](#)]
- Devis-Jauregui L, Eritja N, Davis ML, Matias-Guiu X, Llobet-Navàs D. Autophagy in the physiological endometrium and cancer. *Autophagy.* 2021;17(5):1077-95. [[Crossref](#)] [[PubMed](#)] [[PMC](#)]
- Zhao S, Li G, Yang L, Li L, Li H. Response-specific progestin resistance in a newly characterized Ishikawa human endometrial cancer subcell line resulting from long-term exposure to medroxyprogesterone acetate. *Oncol Lett.* 2013;5(1):139-44. [[Crossref](#)] [[PubMed](#)] [[PMC](#)]
- Numata T, Sato-Numata K, Okada Y. TRPM7 is involved in acid-induced necrotic cell death in a manner sensitive to progesterone in human cervical cancer cells. *Physiol Rep.* 2019;7(13):e14157. [[Crossref](#)] [[PubMed](#)] [[PMC](#)]
- Rybarczyk P, Gautier M, Hague F, Dhennin-Duthille I, Chatelain D, Kerr-Conte J, et al. Transient receptor potential melastatin-related 7 channel is overexpressed in human pancreatic ductal adenocarcinomas and regulates human pancreatic cancer cell migration. *Int J Cancer.* 2012;131(6):E851-61. [[Crossref](#)] [[PubMed](#)]
- Wang J, Liao QJ, Zhang Y, Zhou H, Luo CH, Tang J, et al. TRPM7 is required for ovarian cancer cell growth, migration and invasion. *Biochem Biophys Res Commun.* 2014;454(4):547-53. [[Crossref](#)] [[PubMed](#)]
- Sahni J, Scharenberg AM. TRPM7 ion channels are required for sustained phosphoinositide 3-kinase signaling in lymphocytes. *Cell Metab.* 2008;8(1):84-93. [[Crossref](#)] [[PubMed](#)] [[PMC](#)]
- Inoue K, Xiong ZG. Silencing TRPM7 promotes growth/proliferation and nitric oxide production of vascular endothelial cells via the ERK pathway. *Cardiovasc Res.* 2009;83(3):547-57. [[Crossref](#)] [[PubMed](#)] [[PMC](#)]