

A Sudden Onset of Dysarthria in a Pregnant Woman A Case of Clival Chordoma

*GEBEDE ANI BAŞLANGIÇLI DİSARTRİ
KLİVAL KORDOMA VAKASI*

Zehra KAVAK*, Özgür ÖKTEM*, Nejat CEYHAN*, Türker KILIÇ**

* Assoc.Prof., Marmara University Hospital Department of Obstetrics and Gynecology

** Resident, Marmara University Hospital Department of Obstetrics and Gynecology,

*** Prof., Marmara University Hospital Department of Obstetrics and Gynecology,

**** Assis.Prof., Marmara University Hospital Department of Neurosurgery Institute of Neurologic Sciences, İstanbul, TURKEY

Summary

A 29 year-old pregnant woman developed dysarthria, difficulty in swallowing and neck pain at 22 weeks of gestation. The neurologic examination revealed CN XI palsy and MRI demonstrated a chordoma at clivus. During the follow-up patient's symptoms worsened and cesarean section was performed at 37 weeks of gestation and she delivered a 3100 grams healthy fetus with alleviation of symptoms postoperatively. Tumor was resected four weeks postpartum and she recovered uneventfully from the operation.

Key Words: Chordoma, Clivus, Pregnancy, Dysarthria, CN XI palsy

T Klin J Gynecol Obst 2002, 12:59-60

Özet

29 yaşındaki bir gebe, 22. gebelik haftasında disartri, yutma güçlüğü ve boyun ağrısı ile başvurdu. Nörolojik muayenede 11.kranial sinir palsisi tespit edildi. MRI clivus yerleşimli kordomayı gösterdi. Takipte nörolojik semptomları kötüleşen hastada gebelik 37.haftada sezaryen ile sonlandırılarak 3100 gram sağlıklı bir bebek dünyaya getirdi ve postpartum semptomlarında gerileme izlendi. Tümör doğumdan 4 hafta sonra gerçekleştirilen ikinci bir operasyonla rezeke edildi. Hastanın postoperatif seyri sorunsuz geçti.

Anahtar Kelimeler: Kordoma, Klivus, Gebelik, Disartri, 11.kranial sinir palsisi

T Klin Jinekoloj Obst 2002, 12:59-60

Chordoma is one of the rarest intracranial tumors and develops from sites of remnants of the primitive notochordal cells, namely clivus, sellar and parasellar regions, nasopharynx, foramen magnum, the vertebrae and the sacro-coccygeal region. This slow-growing, locally invasive tumor is usually deeply located at skull base and difficult to remove completely. It therefore should be considered a malignant tumor.

Case

A 29 year-old pregnant woman 2-0-2-2 presented with numbness in her tongue, difficulty in swallowing and neck pain to our clinic. History revealed that she had suddenly developed slurred speech and tongue numbness after one month's history of neck pain. On admission she had normal vital signs. Laboratory values were unremarkable for hematologic, biochemical and urinalysis parameters. Ultrasound showed a normal appearing singleton pregnancy of 22 weeks' size. Having consulted with neurosurgery patient was found to have CN XI palsy manifested by dysarthria and difficult swallowing. MRI demonstrated chordoma at clivus on sagittal sections (figure). Further workup to evaluate the extent of neurologic involvement utilizing cerebral and spinal

evoked potentials yielded normal findings justifying a mild involvement. Then pregnancy was allowed to reach at least to a viable stage under close observation with deferment of an immediate operation. During follow-up, patient's symptoms deteriorated and cesarean delivery was performed at 37 weeks' gestation and she delivered a 3100 gram healthy fetus. Following delivery her symptoms showed a mild regression. The patient was operated on four weeks postpartum with resection of optimal tumor mass and followed an uneventful postoperative course.

Discussion

Chordoma is a rare tumor, representing 0.2% of all intracranial tumors and 40% of chordomas are primarily intracranial (1,2). This invasive tumor is usually arises in the clivus and also found commonly in the sacrococcygeal region and the vertebrae. This case is likely to be unique with regard to unusual presentation of clival chordoma in pregnancy since we failed to find any case of an intracranial chordoma first presenting during pregnancy in a computer-based literature review.

Intracranial tumors newly diagnosed in pregnancy have been found to have a lower incidence compared to general population (3). This may be in part accounted for

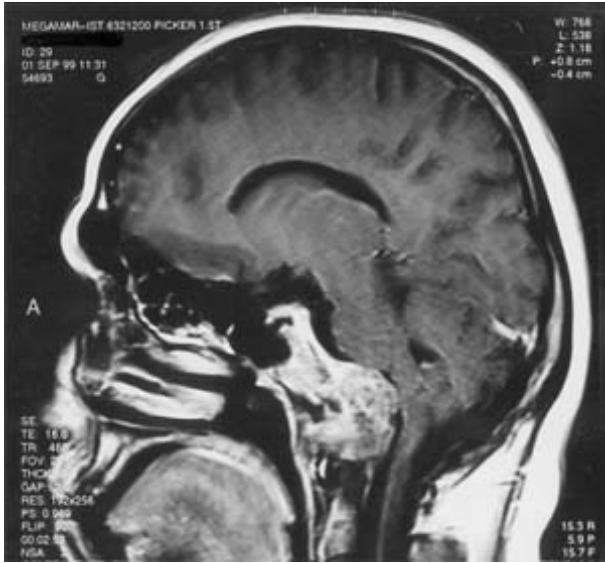


Figure 1. Sagittal section of MRI showing chordoma at clivus.

by increased spontaneous abortion and decreased conception rates reported in pregnant women (4). Management of intracranial tumors detected during gestational period challenges to both neurosurgeon and obstetrician. Although many intracranial neoplasms diagnosed during pregnancy are fortuitously related to pregnancy certain tumors including pituitary adenoma, meningioma, neurofibromatosis, hemangioblastoma and vascular malformations exhibit a closer relation to pregnancy with their symptoms deteriorating during pregnancy and remitting after delivery. However pregnancy may aggravate symptoms of an intracranial neoplasm of any type most likely due to an increase in tumor size. A possible explanation for this pregnancy-related effect may include an accelerated tumor growth rate, venous engorgement and increased fluid content. This may be hormonally-mediated in certain tumors, particularly meningiomas, which has been demonstrated to have increased levels of progesterone receptors (5-6). But it is difficult to conclude whether this mechanism is also operative in other intracranial tumors as in our case.

Management of pregnant women with intracranial tumor should be accomplished on individual basis and definitive neurosurgical operation should not be postponed until after delivery. In general-however, pregnancy can be allowed to proceed until fetus reaches to term or at least to

a viable stage unless there are signs of increased intracranial pressure, increased neurologic deficit or refractory seizures that mandate an early or immediate intervention. Therapeutic abortion may be considered at early weeks of gestation in patients with uncontrollable seizures, infratentorial lesions or malignant tumors if tumor cannot be completely resected.

Mode of delivery should be individualized although several authors have proposed that cesarean section is safer than vaginal delivery in these patients since vaginal delivery may increase the intracranial pressure especially during the second stage of labor. However, vaginal delivery with shortening of the second stage with vacuum extraction or forceps is often considered safe.

In summary, there is no a standart protocol for the obstetric and neurosurgical managements of patients with cerebral neoplasms, which should be determined individually with consideration of gestational age at presentation, neurologic status of the patient ,type and location of the tumor with probable consequences related to mother and fetus. Also of importance is the common manifestations of intracranial neoplasms, namely seizure, headache and neurologic deficits which must be differentiated from pre-eclampsia and eclampsia in the gravid patient.

REFERENCES

1. Heffelfinger MJ, Dahlin DC, Maccarty CS, Beabout JW. Chordomas and cartilaginous tumors at the skull base. *Cancer* 1973;32:410-20.
2. Kravenbühl H, Yasargil M. Cranial chordomas. *Progress in Neurological surgery* 1975; 6:380-434.
3. Haas JF, Janisch W, Staneczak W. Newly diagnosed primary intracranial neoplasms in pregnant women: A population-based assesment. *J Neurol Neurosurg Psychiatry* 1986;49:874-80.
4. Roelvink Ca, Kamphorst W, van Alphen HAM, Rao BR. Pregnancy-related primary brain and spinal tumors. *Arch Neurol* 1987;209-15.
5. Lesch KP, Gross S. Estrogen receptor immunoreactivity in meningiomas. Comparision with the binding of estrogen, progesterone and androgen receptors. *J Neurosurg* 1987; 67:237-43.
6. Lee LS, Chi CW, Chang TJ et al. Steroid hormone receptors in meningiomas of Chinese patients. *Neurosurgery* 1989;25:541-5.

Geliş Tarihi: 22.03.2001

Yazışma Adresi: Dr.Zehra KAVAK
Marmara Üniversitesi Tıp Fakültesi
Kadın Hastalıkları ve Doğum AD, İSTANBUL