

# A Rare Presentation of Down Syndrome: Non Immune Hydrops Fetalis

DOWN SENDROMUNUN ENER GÖRÜLEN BİR PREZENTASYONU:  
NON-İMMÜN HİDROPS FETALIS

Yakup Erkan ERATA, Berrin ACAR,  
Cema! POSÂCi, Atakan TOPUZ, Süien Sanođiu\*

Dokuz Eylül University Medicine Faculty Department of Obstetrics and Gynecology, \*Department of Pathology, İZMİR

## SUMMARY

**Objective:** To discuss a Down syndrome case which presented itself with severe hydrops fetalis,

**institution:** Dokuz Eylül University-Medicine Faculty, Department of Obstetrics and Gynecology.

**Materials and Methods:** 35 year-old woman who was referred to our hospital with the diagnosis of hydrops fetalis in her first pregnancy at 28 weeks of gestation is presented as a case report.

**Findings:** At detailed malformation ultrasound in our clinic no any specific abnormality was detected which might cause to hydrops fetalis. The chromosome analyses of red blood cells of fetus which was obtained by chordosynthesis revealed a 47, XY + 21 karyotype, indicating the diagnosis of Down syndrome. The pregnancy was terminated at 29 weeks of gestation. In autopsy all the systems were evaluated as normal.

**Conclusion:** Because of the association of many chromosomal abnormalities with non immune hydrops we recommend prenatal cytogenetic examination to be performed especially in fetuses with otherwise unexplained causes of non immune hydrops fetalis.

**Key Words:** Down syndrome, Hydrops fetalis

T Klin J Gynecol Obst 1995, 5:280-282

## ÖZET

**Amaç:** Kendini hidrops fetalis tablosu ile prezente eden bir Down sendromu olgusunu tartışmak.

**Çalışmanın yapıldığı yer:** Dokuz Eylül Üniversitesi- Tıp Fakültesi. Kadın Hastalıkları ve Doğum Anabilim Dalı.

**Materyal ve Metod:** 35 yaşında ilk gebeliđi olan ve 28. haftada yapılan ultrasonografik tetkikinde non immün hidrops fetalis saptanması nedeniyle kliniđimize refere edilen hasta olgu sunumu olarak hazırlanmıştır.

**Bulgular:** Kliniđimizde yapılan detaylı malformasyon ultrasonunda hidrops fetalise yol açabilecek herhangi spesifik bir anormallik saptanmadı. Kordosentezle elde edilen fetal kan hücrelerinden yapılan kromozom çalışmasında 47,XY + 21 kromozoma! yapı saptanarak Down sendromu tanısı konuldu. Gebelik 29. haftada sonlandırıldı. Otopside tüm sistemler normal olarak değerlendirildi.

**Sonuç:** Birtakım kromozoma! anormalliklerin non immün hidrops fetalis ile assosiasyonundan dolayı özellikle hidrops mekanizmasının açıklanamadığı non immün hidrops fetalis olgularında prenatal sitogenetik tetkik yapılmasını öneririz.

**Anahtar Kelimeler:** Down sendromu, Hidrops fetalis

T Klin Jinekolo Obst 1995, 5:280-282

Down syndrome represents one of the most common and best understood cytogenetic diseases in humans. The literature on sonographic detection of anomalies commonly found in affected fetus has focused on malformations such as cardiac defects, duodenal atresia, flattened face, fetal nuchal skin thickening, shortened femur, and hypoplasia of the fifth digit.

Geliş Tarihi: 18.1.1995

Correspondence: Dr.Yakup Erkan ERATA  
110. Sok. Simsaroglu sitesi  
Banu apt. No: 2/18  
Göztepe, İZMİR

At present, maternal age is the primary indication for cytogenetic diagnosis of Down syndrome by amniocentesis, CVS or chordosynthesis. Maternal age above which diagnosis is offered varies between 35 and 38 years. This cut-off identifies a high risk population that constitutes about %5 of livebirths. The Down syndrome babies born to this high risk group are about %30 of all Down's syndrome babies; the remaining %70 are born to the younger unscreened mothers (1,2). About 60% of Down syndrome cases show some malformations in the detailed ultrasound examination which is performed at 18 weeks of gestation in most centers. The screening tests for Down syndrome should be applied in all age groups to minimize this disease.

### CASE REPORT

A 35-year-old woman, gravida 1, para 0, was referred to our clinic with the diagnosis of hydrops fetalis which was detected at 28 weeks of gestation in her

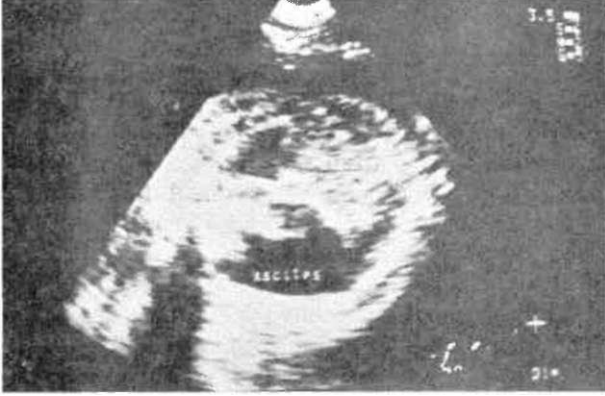

Figure 1. Ultrasonographic appearance of hydrothorax which was detected at 28 weeks of gestation.

Şekil 1. 28. gebelik haftasında saptanan hidrotoraksın ultrasonografik görünümü.

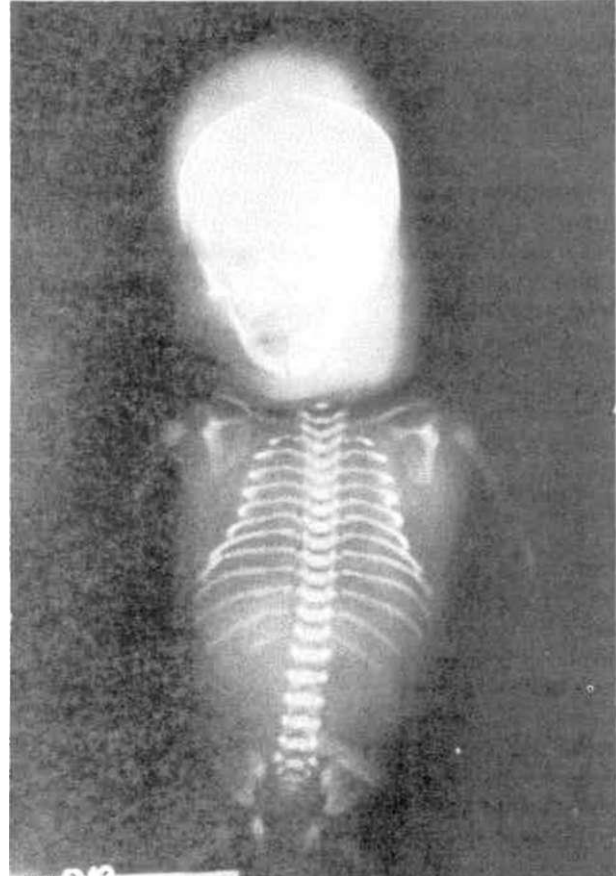
routine examination. The family and pregnancy histories were unremarkable. All the serologic tests (TORCH) which was carried out in the first trimester were normal.

On the initial sonographic examination in our clinic, generalized oedema all around the fetus, moderate hydrothorax and moderate ascites in the abdomen was detected (Figure 1). The nuchal fold thickness was 11 mm.s. The four chamber view of the heart couldn't be identified clearly. At his profile flattened face was identified. The diameters of the extremities corresponded with the gestational age. The kidneys were demonstrated to be normal. By these ultrasound findings no any spesific condition was thought which might cause to hydrops fetalis. Chordosynthesis was carried out to karyotype the fetus. At her second scanning which was performed one week later at 29 weeks of gestation, it was observed that the degree of hydrops fetalis became more severe than it was. Chromosome analysis of red blood cells of fetus revealed a 47 XY + 21 karyotype, indicating the diagnosis of Down syndrome. The couple opted to terminate the

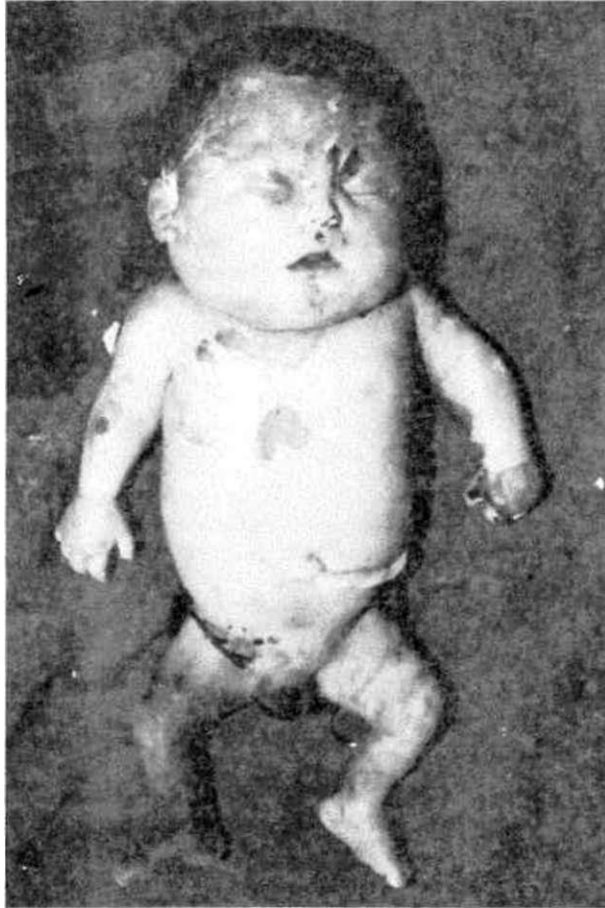

Figure 2. Appearance of hydropic fetus after delivery.

Şekil 2. Hidropik fetusun doğumdan sonraki görünümü.



À

Figure 3. X-Ray of the fetus showing normal skeletal structure.

Şekil 3. Fetusun normal iskelet yapısı gösteren X-Ray filmi.

pregnancy at 29 weeks of gestation (Figure 2). In the X-Ray no any skeletal abnormalities were detected (Figure 3). The fetus underwent to autopsy, in the autopsy no any structural abnormalities was detected other than hydrops. The microscopic pathology was evaluated to be normal in all systems.

## DISCUSSION

Trisomy 21 is one of the most common chromosome abnormalities, with an overall prevalence of 1 in 660 newborns (3). Trisomy 21 comprises nearly half of all chromosome abnormalities detected at the time of second trimester amniocentesis. The precise risk of trisomy 21 varies significantly with maternal age.

An increased incidence of congenital malformations is well known to occur in children with Down's syndrome. A variety of prenatal sonographic abnormalities are associated with Down's syndrome, and the frequency of detecting most abnormalities increases with menstrual age. The morphological features which are diagnosed mostly at detailed ultrasound examination are: thickened nuchal fold (%42), hypoplasia of fifth digit (%50), clinodactyly (%50), cardiac abnormalities (%40), duodenal atresia and shortened femur (4). Among them hydrops fetalis is relatively rare. In a series which was published by Nyberg et. al. only two fetuses in 94 fetuses having Down syndrome presented themselves with hydrops fetalis (1). In another study reported by Holzgreve et. al. only two fetuses had Down syndrome in fifty hydrops fetalis cases and both of these fetuses had cystic neck structure which implicates lymphatic obstruction for the mechanism (5). Anomalies more frequently detected before 20 weeks include cystic hygromas, nuchal thickening, and hyper-echogenic bowel.

Chromosome abnormalities are a relatively common cause of non-immune hydrops, accounting for up to %14 of cases (5). Among them the most common chromosome abnormality is Turner syndrome (XO) accounting for approximately %10 of this rate. Other chromosomal abnormalities associated with Down syndrome are trisomy 13, 18, and 21 (5,6,7). The etiologic mechanism of hydrops may vary from case to case, but congestive heart failure and lymphatic obstruction are most commonly implicated. Atrioventricular septal defect is frequently associated with other cardiac defects and has been strongly linked to trisomy 21. A prenatal study found that 14 of 29 fetuses with atrioventricular septal defect had a chromosome abnormality, and 9 (%64) of these had trisomy 21 (8). In a larger study of 128 liveborn infants with atrioventricular septal defect, %70 had trisomy 21 (9). Conversely, nearly half of the 187 infants with congenital heart di-

seases and a chromosome abnormality had atrioventricular septal defect as the primary diagnosis (9).

In our case there was not any finding which suggests any mechanism for hydrops fetalis. There are many structural abnormalities related with pulmonary, genitourinary or skeletal systems which may cause to hydrops fetalis. But even in these cases the precise mechanism which leads to this entity is not known. Lymphatic obstruction seems to be the most logical explanation for these conditions and for our case.

Because of the association of chromosome abnormalities with non immune hydrops, fetuses with otherwise unexplained causes of hydrops should be considered for chromosome analysis by amniocentesis or choriosynthesis prior to delivery. Awareness of the sonographic findings associated with Down syndrome should result in improved detection of this disorder.

## KAYNAKLAR

1. David A. Nyberg, Robert G Gesta, David A, Luthy, Durlin E, Hickok, Barry S Mahony, Jack H. Hirsch: Prenatal sonographic findings of Down syndrome: Review of 94 cases. *Obstet Gynecol* 1990; 76:370-6.
2. Keeling JW. Examination of the fetus following prenatal suspicion of congenital abnormality. In: Keeling JW ed. *Fetal and neonatal pathology*. Newyork: Springer-Verlag, 1987: 99-122.
3. Kenneth Lyons Jones: Smith's Recognizable patterns of human malformation, in: Kenneth U. Down syndrome. Philadelphia: WB Saunders Company, 1988:10-7.
4. Arthur Fleischer, Roberto Romero, Frank A. Manning, Philippe Jeanty, Everette James: Ultrasonography In: *Obstetrics and Gynecology*. In The antenatal sonographic diagnosis of syndromes. Beryl Benacerraf, Connecticut, Appleton and Lange. 1991: 307-12.
5. Holzgreve W, Curry CJR, Goibus MS, Callen PW, Filly RA, Smith CJ. Investigation of nonimmune hydrops fetalis. *Am J Obstet Gynecol* 1984; 150(7): 805-12.
6. Hutchinson AA, Drew JH, Yu VY Williams ML, Fortune DW, Beischer NA. Nonimmunologic hydrops fetalis: A review of 61 cases. *Obstet Gynecol* 1982; 59(3): 347-52.
7. Romero R, Pihu G, Jeanty P, Ghidini A, Hobbins JC. Prenatal diagnosis of congenital anomalies. In *Nonimmune hydrops fetalis*. Connecticut, Appleton and Lange, 1988; 414-23.
8. Machado MV, Crawford DC, Anderson RH, Allan LD. Atrioventricular septal defect in prenatal life. *Br Heart J* 1988; 59(3):352-5.
9. Ferencz C, Rubin JD, McCarter RJ, Boughman JA, Wilson PD, Brenner JI, Neill CA, Perry LW, Hepner SI, Downing JW. Cardiac and noncardiac malformations: Observations in a population-based study. *Teratology* 1987. 35(3):367-78.