

Isolated Torsion of the Fallopian Tube with Ectopic Pregnancy: Case Report

Ektopik Gebelikle Birlikte Olan İzole Tubal Torsiyon

Nuri YILDIRIM,^a
A. Gülşah ŞAHİNGÖZ YILDIRIM,^b
Ali AKDEMİR,^b
Ahmet Mete ERGENOĞLU,^b
Ahmet Özgür YENİEL^a

^aDepartment of Gynecology and Obstetrics,
Dokuz Eylül University Faculty of Medicine,
^bDepartment of Gynecology and Obstetrics,
Ege University Faculty of Medicine,
İzmir

Geliş Tarihi/Received: 04.06.2013
Kabul Tarihi/Accepted: 10.07.2013

Yazışma Adresi/Correspondence:
Nuri YILDIRIM
Dokuz Eylül University Faculty of Medicine,
Department of Gynecology and Obstetrics,
İzmir,
TÜRKİYE/TURKEY
nuri-yildirim@hotmail.com

ABSTRACT Isolated tubal torsion containing an ectopic pregnancy is a very rare event. Ectopic pregnancy may also cause these symptoms and may impede the diagnosis of tubal torsion when these two coexist. We present a case with isolated fallopian tube torsion containing an ectopic pregnancy. A 25-year-old gravida 2, parity 0 woman presented with left lower abdominal pain and vaginal bleeding. Sonography revealed a 2 cm adnexal mass adjacent to the left ovary. β -hCG level was 157 mIU/ml. Laparoscopy depicted torsion of the left fallopian tube together with an ectopic pregnancy. Left salpingectomy was performed. The clinician should also think about tubal torsion when the pain is intermittent and if he suspicious about the ectopic pregnancy.

Key Words: Pregnancy, ectopic; fallopian tubes; torsion, mechanical

ÖZET Ektopik gebelik ve izole fallopian tüp torsiyonu çok nadiren birarada görülen bir patolojidir. Ektopik gebelik, tuba torsiyonu ile benzer klinik bulgular verebilir ve bu nedenle iki patoloji birarada olduğu zaman tanıyı gizleyebilir. Bu olgu sunumunda, 25 yaşında, gravida 2, parite 0 olan ve kliniğe sol alt kadranda ağrısı ve vajinal kanama ile başvuran bir hasta tartışılacaktır. Hastanın ultrasonografisinde sol adneksiyal bölgede 2 cm kitle izlenmekte olup, β -hCG düzeyi 157 mIU/ml'dir. Laparoskopide sol fallopian tüpün torsiyone olduğu ve ampuller ektopik gebelik barındırdığı izlenmiştir. Sol salpenjektomi uygulanmıştır. Klinisyen özellikle ağrının intermittan olduğu ektopik gebelik olgularında tubal torsiyonu da akla getirmelidir.

Anahtar Kelimeler: Gebelik, ektopik; fallopian tüpler; torsiyon, mekanik

Türkiye Klinikleri J Gynecol Obst 2014;24(2):120-2

Isolated torsion of the fallopian tube is a rare event with the overall incidence of 1 in 1,5 million women and is generally unilateral.¹ The lack of pathognomonic symptoms and clinical findings makes this pathology difficult to diagnose preoperatively. The patient presents intermittent abdominal pain related to torsion and detorsion of the fallopian tube. Nausea and vomiting may also be involved. Ectopic pregnancy is relatively a more common event and it is seen almost 2% of all pregnancies.² Classical symptoms are the lack of menstrual period, vaginal bleeding and abdominal pain. Coexistence of fallopian tube torsion and ectopic pregnancy is very rare and two reports were presented so far. Here, we report a laparoscopic management of a case with isolated torsion of fallopian tube containing an ectopic pregnancy.

CASE REPORT

A twenty-five year old woman, gravida 2, parity 0 applied with the complaint of intermittent abdominal pain and vaginal bleeding for two days. Her last menstrual period was 2 months ago. On physical examination, she had abdominal rebound and tenderness. There was not an active vaginal bleeding. On sonographic examination, there was a 2 cm adnexal mass adjacent to the left ovary and free fluid in the pouch of Douglas. Her β -hCG level was 157 mIU/ml. Then she was taken to the operating room for laparoscopy with the diagnosis of ectopic pregnancy. Laparoscopy revealed that the left fallopian tube was twisted twice at the medial end and contained an unruptured ectopic pregnancy in the ampullary region (Figure 1). There was 100 cc haemoperitoneum. Left salpingectomy was performed. Postoperative period was uneventful. Tubal pregnancy was confirmed histopathologically.

DISCUSSION

Isolated fallopian tube torsion (FTT) is a rare clinical entity. The exact cause of FTT is unknown. There are some theories reported by some authors. Regad surveyed 201 cases of fallopian tube torsion and found a normal appearance in only 24%. Hydrosalpinx was found in 18%, and infection in 13%. In 12% of cases, the diagnosis is made during a normal intrauterine pregnancy.³ Yousef et al, divided the causes of FTT into two parts.⁴ Intrinsic causes may be congenital anomalies of the tube; acquired pathologies such as hydrosalpinx, hematosalpinx, neoplasm, surgery; autonomic dysfunction and abnormal peristalsis. Extrinsic causes may be changes in the neighboring organs such as neoplasm, adhesions, pregnancy; mechanical factors; movement or trauma to the pelvic organs or pelvic congestion. He also mentioned about the possible mechanisms of the torsion. Mechanical disturbance, venous obstruction, lymphatic congestion, diffuse edema and tubal enlargement may cause tubal torsion.

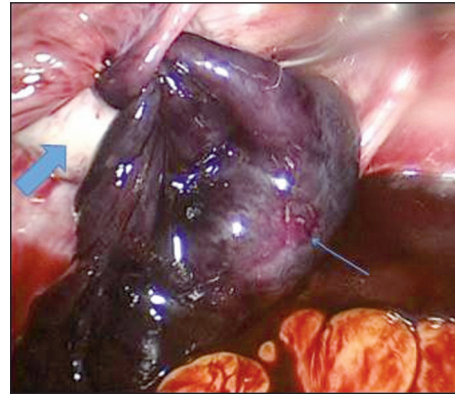


FIGURE 1: Isolated torsion of the fallopian tube with ectopic pregnancy: Thin arrow shows the ectopic pregnancy in the torsioned tube. Thick arrow shows the normal ovary.

(See color figure at <http://www.turkiyeklinikleri.com/journal/jinekoloji-obstetrik-dergisi/1300-0306/>)

The diagnosis is difficult because there no specific symptoms or findings belong to FTT. The typical signs of isolated FTT included acute onset of pelvic pain and the presence of an adnexal mass. According to Lo et al, nausea and vomiting were quite common, occurring in 41%, lower urinary tract symptoms in 24% and cervical motion tenderness during bimanual pelvic examination in 18%.⁵

Coexistence of the FTT and ectopic pregnancy is a very rare entity and there are two reports in the literature.^{6,7} Ectopic pregnancy is more common and the symptoms may mask the tubal torsion symptoms. It is very difficult for clinician to differentiate the fallopian tube torsion from the ectopic pregnancy especially when these two coexist in the same patient. Like the case we present, the clinician may encounter with tubal torsion when he operate the patient for another pathology.

In conclusion, the diagnosis of fallopian tube torsion is very difficult preoperatively. Ectopic pregnancy may cause tubal torsion as an intrinsic cause and an acquired pathology of the tube. The clinician should also think about tubal torsion when the pain is intermittent and if he suspicious about the ectopic pregnancy.

REFERENCES

1. Hansen OH. Isolated torsion of the Fallopian tube. *Acta Obstet Gynecol Scand* 1970;49(1): 3-6.
2. Centers for Disease Control and Prevention (CDC). Ectopic pregnancy--United States, 1990-1992. *MMWR Morb Mortal Wkly Rep* 1995;44(3):46-8.
3. Regad J. [Anatomo-pathological evaluation of torsion of the tuba uterina]. *Gynecol Obstet* 1933; 27:519-35.
4. Youssef AF, Fayad MM, Shafeek MA. Torsion of the fallopian tube. A clinico-pathological study. *Acta Obstet Gynecol Scand* 1962;41: 292-309.
5. Lo LM, Chang SD, Lee CL, Liang CC. Clinical manifestations in women with isolated fallopian tubal torsion; a rare but important entity. *Aust N Z J Obstet Gynaecol* 2011;51(3):244-7.
6. Renjit S, Morale EU, Mathew M. Isolated torsion of a tubal ectopic pregnancy- a rare event. *Oman Med J* 2008;23(4):289-90.
7. Larsen JV, Whittal D. Chronic torsion of the fallopian tube in ectopic pregnancy. *S Afr Med J* 1990;78(1):47-8.