

# Successful Pregnancy with Ovulation Induction After Conservative Treatment in a Woman with Polycystic Ovaries and Endometrial Complex Hyperplasia

## ENDOMETRİAL KOMPLEKS HİPERPLAZİ SAPTANAN POLİKİSTİK OVER SENDROMLU HASTADA KONSERVATİF TEDAVİ SONRASI OVULASYON İNDÜKSİYONU İLE BAŞARILI GEBELİK

Yıldız Ayhan TUNÇAY, MD,<sup>a</sup> Kadir GÜZİN, MD,<sup>a</sup> Cengiz ÖMÜRÇAN, MD,<sup>a</sup>  
Ahmet KİREÇCİ, MD,<sup>a</sup> Tülay İNCE, MD,<sup>b</sup> Neşe YÜCEL, MD,<sup>a</sup>

<sup>a</sup>Clinic of Obstetrics and Gynecology, SSK Göztepe Educational Hospital,

<sup>b</sup>Clinic of Pathology, SSK Göztepe Educational Hospital, İSTANBUL

### Abstract

A 32-year-old woman who had infertility for 9 years and polycystic ovary syndrome (PCOS) associated with endometrial complex hyperplasia without atypia is presented. After progestin treatment for 3 months, histologic examination of the endometrium showed regression of the lesion. For the reducing the clinical manifestations of androgen excess and restoring regular menstrual bleeding, treatment continued with oral contraceptive (cyproterone) and consisted of weight loss by restricted calories diet. Ovulation induction with clomiphene citrate was resulted in a successful pregnancy at the end 12 months after the initial diagnosis of endometrial hyperplasia was made. Conservative treatment with progestin and ovulation induction of patients with PCOS and endometrial complex hyperplasia should be considered in properly selected cases.

**Key Words:** Polycystic ovary syndrome, endometrial hyperplasia, conservative treatment

### Özet

Endometrial atipisiz kompleks hiperplazi saptanan 32 yaşında ve 9 yıllık infertilitesi olan polikistik over sendromlu (PCOS) bir olgu sunulmaktadır. Progestinle 3 aylık siklik tedavi sonrasında endometriyumun histopatolojik incelemesinde hiperplazinin gerilediği saptandı. Androjen fazlalığının klinik belirtilerini azaltmak ve adetleri düzenlemek amacıyla zayıflaması önerildi ve siproteron asetat içeren oral kontraseptif ile tedaviye devam edildi. Hastanın endometrial hiperplazi tanısı almasından 12 ay sonra, klomifen sitrat ile ovulasyon indüksiyonu sonucunda başarılı bir gebelik elde edildi. Sonuç olarak endometrial kompleks hiperplazi saptanan PCOS'lu seçilmiş hastalarda, progestin ile konservatif tedavinin ve ovulasyon indüksiyonunun uygun olabileceğini düşünmekteyiz.

**Anahtar Kelimeler:** Polikistik over sendromu, endometrial hiperplazi, konservatif tedavi

Türkiye Klinikleri J Gynecol Obst 2004, 14:345-348

Polycystic ovary syndrome (PCOS) is characterized by menstrual dysfunction (oligo or amenorrhea), infertility, hirsutismus and obesity. PCOS was first described in 1935 by Stein and Leventhal and was known for decades as Stein-Leventhal syndrome. Recently accepted definition

of PCOS, the diagnostic criteria included hyperandrogenism and chronic anovulation and excluded seconder causes such as neoplasm, hyperprolactinemia, and adult-onset congenital adrenal hyperplasia.<sup>1</sup>

Unopposed persistently elevated estrogen levels in chronic anovulatory patients with PCOS increase the risk of endometrial hyperplasia and carcinoma. The risk of untreated endometrial hyperplasia progressing to carcinoma is ranging from 1% to 29%.<sup>1-3</sup> Therefore, the selected treatment of it for older women may be hysterectomy. For young women who wishing to preserve fertility, medical

Geliş Tarihi/Received: 15.04.2004 Kabul Tarihi/Accepted: 12.10.2004

This case report was presented as a poster presentation in "PCOS Güncel Durum Tedavi ve Ovulasyon İndüksiyonu Uluslararası Sempozyum, 4-7 Eylül 2003, Antalya"

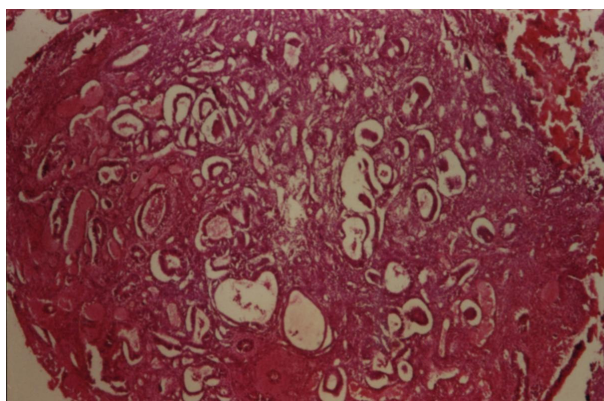
**Yazışma Adresi/Correspondence:** Yıldız Ayhan TUNÇAY, MD  
F Kerim Gökay cad. Ortahar sok. No: 2/25  
34730, Göztepe, İSTANBUL  
ertuncaytr@yahoo.com

Copyright © 2004 by Türkiye Klinikleri

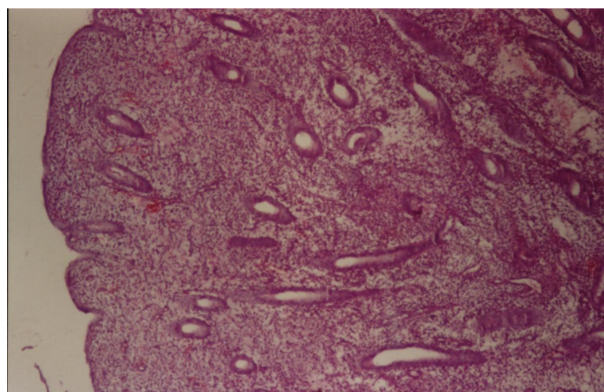
treatment is desirable. Many reports support that progestin therapy is very effective in reversing endometrial hyperplasia. Moreover, a limited body of evidence suggests that well-differentiated endometrial adenocarcinoma may also be treated effectively by progestin.<sup>4-7</sup>

### Case Report

A 32-year-old woman, 9 years infertile, was admitted to our clinic with vaginal bleeding continuing for one month. She had menstrual irregularity (oligomenorrhea) and hirsutism, no diabetes mellitus or hypertension. Her body mass index (BMI) was 35 kg/m<sup>2</sup>. The serum testosterone level (3,9 ng/dl) was upper than normal range, and LH (17 mIU/ml): FSH (7 mIU/ml) ratio was also increased. DHEAS (254 µg/ml) and prolactin (24.7 ng/dl) levels were not increased. Vaginal ultrasonography was revealed bilaterally enlarged ovarian volume within increased number of microcysts and endometrial thickness was 11mm. These findings pointed to the necessity of identifying an increased risk of endometrial hyperplasia in patient with PCOS and endometrial curettage was performed. Histopathological evaluation of the endometrium was revealed complex hyperplasia without atypia (Figure 1). The patient was informed her illness and management of conservative treatment for preserving her fertility. Progestin therapy (medroxyprogesterone acetate 10 mg/day for 20 days per month) was initially began and restricted calories diet was recommended to reduce weight. After 3 months of treatment, endometrial curettage repeated and histological examination showed regression of her lesion to proliferative endometrium (Figure 2). The combination of cyproterone acetate with ethinyl estradiol in oral contraceptive was maintained to reduce plasma testosterone level and restoring regular menstrual pattern. Ovulation induction with clomiphene citrate (CC) was introduced for immediate treatment of the patient's infertility in order to avoid the risk of recurrent hyperplasia of the endometrium. Her BMI was reduced to 28 kg/m<sup>2</sup> (20 kg weight loss). A single pregnancy was achieved at fourth month of ovulation induction with CC and 12 months after the initial diagnosis was made. Pregnancy was compli-



**Figure 1.** Shows microscopic appearance of endometrial complex hyperplasia (x 40 HE).



**Figure 2.** Shows microscopic appearance of proliferative endometrium (x 40 HE).

cated with preeclampsia and glucose intolerance. In 38th weeks of gestation, fetal growth was retarded for 4 weeks and there were loss of variability together with recurrent deceleration spontaneously in the evaluation of nonstress test. For this reason, cesarean section was performed and 2100 g female fetus was born. At follow-up of 3 years postpartum, the patient was healthy with regular menstrual pattern; moreover, she aborted spontaneously second pregnancy, needed no medication.

### Discussion

In chronic anovulatory patients with PCOS, persistently elevated estrogen levels with uninterrupted by progesterone increase risk of endo-

metrial adenocarcinoma. Some authors indicated that women with PCOS have a high incidence of the endometrial cancer of approximately 25%, but actually it is less.<sup>2</sup> Farhi et al found that 7 of their 10 cases who were below 25 years of age had PCOS.<sup>8</sup> In this reason, the presence of obesity, infertility and irregular menstrual periods or an absence of menses in women with PCOS should encourage the physician to search the possibility of underlying endometrial pathology by curettage or biopsy. For predicting endometrial hyperplasia, endometrial thickness on vaginal ultrasound assessment is also useful.<sup>9</sup>

Endometrial hyperplasias are important because they may precede or simultaneously with endometrial cancer. As known for decades, complex hyperplasia is an endometrial cancer precursor lesion. Complex hyperplasia without atypia is characterized by the presence of hyperproliferative endometrial glands with irregular shapes and mitosis, an increased glandular-to-stromal ratio with glandular crowding and diminishing stroma that may be confused with well differentiated adenocarcinoma.<sup>10</sup> This risk of progressing to endometrial carcinoma was found 26.7% in study of Wentz,<sup>2</sup> 16% in study of Campell, 22% in study of Sherman, and 6% in study of Hall.<sup>3</sup> Older women with complex hyperplasia have choiced surgical treatment, hysterectomy, because of high risk endometrial cancer. Organ preserving method in the management of endometrial hyperplasia is considered in young women who desire to preserve their fertility. Conservative treatment of endometrial hyperplasia with progestins is very effective in resolving lesion and a safe alternative to hysterectomy in women under age 40.<sup>1-7</sup> For women with endometrial hyperplasia without atypia; ovulation induction, cyclical progestin therapy (e.g., medroxyprogesterone acetate 10-20 mg/day for 14 days per month), or continuous progestin therapy (e.g., megestrol acetate 20-40 mg/day) all seem to be effective therapies. Continuous progestin therapy is probably the most reliable treatment for reversing complex or atypical hyperplasia.<sup>1,2,3,5</sup> Kobashvili et al. reported that conservative treatment proved to be effective in 96.4% of total 96 cases

with atypical endometrial hyperplasia.<sup>11</sup> Kurabayashi et al. analyzed retrospectively pregnancy rate in infertile women diagnosed with endometrial hyperplasia or carcinoma by endometrial biopsy. Of infertile women, 0.93% have endometrial abnormalities, and those with PCOS have a high risk of endometrial carcinoma. Assisted reproductive technology combined with high-dose medroxyprogesterone acetate.<sup>12</sup>

Goker et al reported a woman with complex hyperplasia with atypia. The patient was treated with several cycles of different gestagens and after repeated endometrial curettage, in vitro fertilization and embryo transfer was achieved a single pregnancy.<sup>7</sup> Muechler et al also achieved successful pregnancy in an infertile woman with PCOS associated with endometrial hyperplasia and well-differentiated adenocarcinoma. They introduced CC for conservative treatment with ovulation induction, but pregnancy didn't occur. Then, treatment with menotropins resulted in a twin pregnancy that aborted spontaneously and a singleton term pregnancy.<sup>13</sup>

PCOS, especially in obese woman, is also associated with insulin resistance and hyperinsulinemia. Improvement of hyperinsulinemia by weight loss or by treatment with the insulin-sensitizing agent (metformin) decreases serum androgen levels and improves menstrual pattern and ovulatory function. 10-kg weight loss results in a 40% decrease in insulin levels and a 35% decrease in testosterone levels.<sup>1</sup>

Our case was an obese woman with PCOS, 9-year infertile, and found endometrial complex hyperplasia without atypia by endometrial curettage. In light of above knowledges, firstly, the patient was effectively treated with progestin during a three months period. For correction of BMI, weight loss by caloric restriction was recommended and her weight loss was 20-kg. After completion hormone therapy, successful pregnancy was achieved by ovulation induction with CC at the end 12 months of initial diagnosis. This interval was 3 ½ years for Muechler's case<sup>13</sup> and 32-79 months in Randall's studies.<sup>5</sup> In our case, weight loss had

improved response to ovulation induction with clomiphene citrate. In some studies, pregnancy was achieved by ovulation induction with menotropins, more expensive treatment, or by assisted reproductive technology.<sup>7,11,12</sup>

In conclusion, conservative treatment with progestin and ovulation induction of patients with polycystic ovaries and endometrial complex hyperplasia should be considered in carefully properly selected cases.

### REFERENCES

1. Hershlag A, Peterson CM. Endocrine disorders. Berek JS, Adashi EY, Hillard PA. In Novak's Gynecology 12th ed. Baltimore, USA Williams & Wilkins. 1996: p.837-45.
2. Bengisu E, Ermiş H. Endometriyal hiperplazi. In: Atasu T, Aydın K. Jinekolojik Onkoloji İstanbul Logos Yayıncılık. 1996: p.312-35.
3. Kişnişçi HA, Gökşin E, Durukan T et al. Temel kadın hastalıkları bilgisi. Ankara. Güneş Kitabevi. 1996: p.958-976:1184-93.
4. Güngör T, Demirtürk F, Özdal B, Aydoğdu T. Five women before 40 years of age with endometrial adenocarcinoma. Gynecol Obstet Reprod Med 2003;9:116-9.
5. Randall TC, Kurman RJ. Progestin treatment of atypical hyperplasia and well-differentiated carcinoma of the endometrium in women under age 40. Obstet Gynecol 1997;90:434-40.
6. Dallenbach-Hellweg G, Czernobilsky B, Alleman J. Medroxyprogesterone acetate in adenomatous hyperplasia of the endometrium. Clinical and morphologic studies on the duration and dosage of gestagen therapy. Geburtshilfe Frauenheilkd 1986;46:601-8.
7. Goker EN, Sendag F, Tavmergen E, Levi R, Zekioglu O. Successful pregnancy in an infertile woman with endometrial hyperplasia and embryo transfer. A case report. J Reprod Med 2001;46:859-62.
8. Fahri DC, Nonsanchuk J, Silverberg S. Endometrial adenocarcinoma in woman under 25 years of age. Obstet Gynecol 1986;68:741-5.
9. Cheung AP. Ultrasound and menstrual history in predicting endometrial hyperplasia in polycystic ovary syndrome. Obstet Gynecol 2001;98:325-31.
10. Schlaen I, Bocanera R, Figueroa-Casas P. Endometrial cancer and its precursors: a comparison of histological and clinical features. Maturitas 1986;8:335-44.
11. Kobashvilli H, Charkviani L, Charkviani T. Organ preserving method in the management of atypical endometrial hyperplasia. Eur J Gynecol Oncol 2001;22:297-9.
12. Kurabayashi T, Kase H, Suzuki M, Sugaya S, Fujita K, Tanaka K. Endometrial abnormalities in infertile women. J Reprod Med 2003;48:455-9.
13. Muechler EK, Bonfiglio T, Chote J, Huang KE. Pregnancy induced with menotropin in a woman with polycystic ovaries, endometrial hyperplasia, and adenocarcinoma. Fertil Steril 1986;44:973-4.