

Can Rectal Indomethacin Be an Alternative Local Anesthetic Method to Intrauterine Lidocaine During Endometrial Biopsy? A Clinical Observational Prospective Study

^{ID} Sinem DEMİRCAN KARADAĞ^a, ^{ID} Cihan KARADAĞ^b, ^{ID} Mehmet Baki ŞENTÜRK^a,
^{ID} Abdülkadir TURGUT^a

^aIstanbul Medeniyet University Göztepe Training and Research Hospital, Department of Obstetrics and Gynecology, İstanbul, TURKEY

^bIstanbul Okan University Faculty of Medicine, Department of Obstetrics and Gynecology, İstanbul, TURKEY

ABSTRACT Objective: Endometrial biopsy is a pain-related gynecological procedure. The aim of this study is to compare the efficacy of rectal indomethacin and intrauterine lidocaine on pain control during endometrial sampling. **Material and Methods:** This clinical observational prospective trial was conducted in 120 patients with the complaint of abnormal uterine bleeding who presented at İstanbul Medeniyet University Göztepe Training and Research Hospital, Obstetrics and Gynecology Department, between January 2017 and June 2017. Patients were divided into two groups. The rectal group had 64 patients, to whom indomethacin was given as a local anesthetic. The intrauterine group had 56 patients, for whom lidocaine was the local anesthetic used. Endometrial biopsy was performed by using a no. 4 Karman cannula. The primary goal of measurement was pain intensity assessed by a visual analog scale before, during, and 10 minutes after the procedure. **Results:** There were no statistically significant differences between the two groups in mean age, body mass index, weight and median levels of gravidity, parity and abortion. The median pain scores of the two groups during and 10 minutes after the procedure were similar ($p > 0.05$). **Conclusion:** In this study, rectal indomethacin was shown to be equal to intrauterine anesthesia for reducing pain during the endometrial biopsy. Rectal indomethacin may be an alternative drug to relieve pain during gynecological procedures. Further researches with larger numbers of patients are needed to confirm our findings.

Keywords: Endometrium, biopsy; indomethacin; visual analog scale; anesthesia

Abnormal uterine bleeding (AUB) is a common gynecological symptom, accounting for one-third of outpatient visits to gynecology polyclinics.¹ Endometrial biopsy is frequently performed to evaluate the causes of abnormal uterine bleeding. It is a pain-related procedure and can cause moderate to severe pain, depending on individual perception.² Today, although ultrasonographic assessment of the endometrium is the initial approach, histopathological examination is still the gold stan-

dard for diagnosis. Traditionally, dilatation and curettage (D&C) is the standard procedure for evaluating the endometrium. However, diverse sampling strategies have been developed that can be less painful, quicker, and more economical for the patient.^{3,4}

Nonsteroidal anti-inflammatory drugs (NSAIDs) block prostaglandin synthesis and have been recommended to reduce the pain with regard to gynecological symptoms and gynecological surgical procedures.^{5,6} The latest studies have researched the use of

Correspondence: Cihan KARADAĞ

Istanbul Okan University Faculty of Medicine, Department of Obstetrics and Gynecology, İstanbul, TURKEY

E-mail: cihankaradag2000@hotmail.com



Peer review under responsibility of Journal of Clinical Obstetrics & Gynecology.

Received: 16 Jan 2020

Received in revised form: 16 Apr 2020

Accepted: 17 Apr 2020

Available online: 20 Apr 2020

2619-9467 / Copyright © 2020 by Türkiye Klinikleri. This is an open access article under the CC BY-NC-ND license (<http://creativecommons.org/licenses/by-nc-nd/4.0/>).

local anesthetics (e.g., lidocaine and mepivacaine) to reduce the pain during minor gynecological procedures, which include endometrial sampling and office hysteroscopy. Most, although not all, of those studies showed decreased pain during the technique.⁷⁻⁹

In randomized trials, intrauterine instillation of a local anesthetic has been determined to be more potent than placebo, even though one trial observed a significant effect only when the anesthetic was combined with an NSAID (5 mL intrauterine 2% lidocaine and 550 mg naproxen sodium).^{5,10} One randomized study showed that using rectal indomethacin was more effective than placebo in reducing pain during hysteroscopy.¹¹

There is no study in the literature that investigates rectal indomethacin as a painkiller during endometrial sampling. The primary goal of the current study is to compare the efficacy of rectal indomethacin with intrauterine lidocaine in reducing pain stemming from endometrial sampling procedures.

MATERIAL AND METHODS

This clinical observational prospective study was conducted at the Obstetrics and Gynecology Department, İstanbul Medeniyet University Göztepe Training and Research Hospital, Turkey, between January and June 2017. The study was approved by the local ethics committee of Medeniyet University (Local Ethics committee of İstanbul Medeniyet University Göztepe Training and Research Hospital, Date: 31.01.2017, No: 2016/0234) and was carried out in accordance with the principles set forth in the Helsinki Declaration 2008. Written and signed informed consent was taken from all participants.

We recruited women with AUB requiring endometrial biopsy. All participants had at least one vaginal delivery. The exclusion criteria were pregnancy, acute cervicitis, active genital bleeding, coagulation disorders, cervical stenosis, vaginismus, an inability to decipher the pain score on a 10 cm visual analog scale (VAS), abnormal uterine shape (e.g., uterine fibroids), adenomyosis, and a known allergy to lidocaine and/or indomethacin. Patients with a history of impaired respiratory or cardiac functions, pep-

tic ulcer disease, epilepsy, cerebrovascular disorders, psychiatric disorders, past or active liver disease, or suspected pelvic inflammatory disease were also excluded.

Before beginning the procedure, patients' demographic features were recorded, including age, gravidity, parity, indication of endometrial biopsy, prior type of delivery, last menstrual date, surgical history, and medical disorders. Hemograms, coagulation parameters (prothrombin time and activated partial thrombin time), and beta-hCG blood tests were checked.

The participants assumed a lithotomy position. The cervix was visualized with a sterile speculum, using aseptic techniques. The cervix and vagina were cleaned with betadine solution (1000 mL Batticon, Adeka, İstanbul, Turkey). After that, the endometrium, uterus, and ovary were evaluated by transvaginal ultrasonography. After the procedure, antibiotics have been prescribed to all of the patients.

Participants were allocated to two groups before endometrial biopsy: participants taking rectal indomethacin (rectal, n= 64) and participants taking intrauterine lidocaine (intrauterine, n= 56). Rectal indomethacin (100 mg Endol, Deva, İstanbul, Turkey) was inserted 30 minutes before starting the procedure to allow the anesthetic to take effect. For the intrauterine group, 5 mL 2% lidocaine was instilled into the uterine cavity via the endocervix with an 18-gauge angiocatheter. The angiocatheter was left in location for 3 minutes before it was withdrawn so that it could restrict backflow and allow the anesthetic to take effect (2 mL Jetokain, Adeka, İstanbul, Turkey). The collum uteri was held by tenaculum, and a no. 4 Karman cannula was placed into the uterine cavity.

Endometrial biopsy was conducted by the same operator (SDK) via Karman cannula. Before starting, patients were informed by a nurse about how to score pain by using Visual Analogue Scale (VAS) where 0 meant no pain and 10 meant worst possible pain. Prior to endometrial biopsy, patients were interrogated about pain before starting to the procedure and their pain status were evaluated by VAS.¹² Any patient who described pain and scored more than one

point before starting to endometrial biopsy was excluded from the study. The pain scores of all patients included in the study was 0 prior to the endometrial sampling. VAS values were recorded before, during (VAS 0) and 10 minutes after the procedure (VAS 10).

All statistical calculations were performed with Statistical Package for Social Sciences Statistics 25 Software (SPSS 25). Sixty two patients were needed in each arm by a calculation accepting type I error as 0.05 with the power of 80%. But 8 participants were found inappropriate for indomethacin group and excluded. Comparisons between the groups were made with Mann Whitney U and Student T-test where appropriate. The level of significance was defined as $p < 0.05$. The descriptive features and VAS scores of groups were defined as median (min.-max), the other results were expressed as mean \pm SD (standard deviation).

RESULTS

Of 132 patients enrolled, 12 were excluded, including 8 participants in the lidocaine group and 4 participants in the rectal indomethacin group, due to their describing pain prior to the procedure ($n = 5$), need for cervical dilatation or cervical stenosis ($n = 3$), or prolonged procedure time (up to 5 minutes; $n = 4$) (Figure 1). Consequently, 120 women were included in the study and were separated into two groups.

The mean ages were 44.78 ± 4.36 in the rectal group and 43.9 ± 4.63 in the intrauterine group. The mean levels of body mass index (BMI), weight and previous vaginal delivery were similar between the groups. The median level of gravidity, parity, previous abortion, and procedure durations were also similar between the two groups. The demographics and clinical features of the patients are summarized in Table 1.

The median pain scores recorded during the procedure (VAS 0) were 5 (1-10) in the rectal group and 6 (2-10) in the intrauterine group. While the VAS 0 was higher in the intrauterine group, no significant difference was found between the VAS 0 of the two groups ($p = 0.104$) (Table 2). Pain scores recorded 10 minutes after the procedure (VAS 10) were 1 (0-6) in

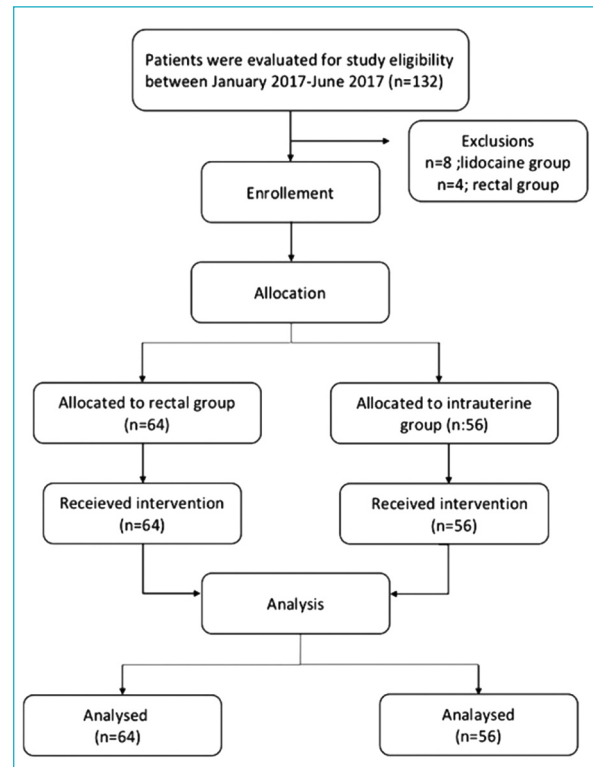


FIGURE 1: Flow chart of participants.

TABLE 1: Demographics and clinical features of the patients.

Age (years)	44.78 \pm 4.36	43.9 \pm 4.63	0.380
Gravidy, median (min.-max.)	3 (1-9)	3 (1-8)	0.768
Parity, median (min.-max.)	2 (1-8)	2 (1-6)	0.678
Abortion, median (min.-max.)	0 (0-5)	0 (0-3)	0.246
BMI (kg/m ²)	28.20 \pm 5.37	29.06 \pm 3.75	0.320
Weight (kg)	73.07 \pm 13.12	75.64 \pm 12.22	0.272
Duration (minute)	5.46 \pm 2.34	5.76 \pm 2.1	0.290
Vaginal delivery	2.53 \pm 0.86	2.78 \pm 1.03	0.467

BMI: Body mass index (kg/m²), kg: kilogram

TABLE 2: Comparison of pain scores between the groups.

	Indomethacin (n=64)	Lidocaine (n=56)	p
VAS 0 median (IQR) (min.-max.)	5 (1-10)	6 (2-10)	0.104
VAS 10 median (IQR) (min.-max.)	1 (0-6)	2 (0-6)	0.080

VAS: Visual analog scale, VAS 0: The pain score during the procedure, VAS 10: The pain score after 10 minutes, IQR: Interquartile range.

the rectal group and 2 (0-6) in the intrauterine group. There was also no significant difference between the levels of VAS 10 of the groups ($p=0.080$). However, the VAS 10 of the groups was significantly lower than their VAS 0.

DISCUSSION

Endometrial biopsy is an invasive procedure that causes different degrees of pain for patients depending on the technique and type anesthesia/analgesia used. In this study we compared the effectivity of rectal indomethacin and intrauterine lidocaine on pain score of patients during and 10 minutes after the procedure. We found similar effectivity on pain scores between the methods.

There are limited number of studies about intrauterine local anesthesia, and most studied intrauterine anesthesia either only during hysteroscopy.^{6,9,11} Endometrial biopsy with hysteroscopy is more invasive and more likely to cause discomfort than endometrial biopsy alone.⁹ The first known study in the literature that discovered the effectiveness of intrauterine lidocaine in the course of endometrial biopsy was achieved by Trolice et al.⁵ In this study the participants received either intrauterine lidocaine (5 mL of 2% lidocaine) or normal saline three minutes prior to endometrial biopsy. Intrauterine lidocaine instillation was found to be effective in lowering the level of pain related to the use of the Pipelle for endometrial biopsy as compared to saline instillation.⁵ For their part, Zupi et al. found that 5 mL of 2% mepivacaine intrauterine instillation effectively decreased the pain related to endometrial sampling performed through hysteroscopy.⁸ Cicinelli et al. assessed 80 patients who received either 2 mL of 2% mepivacaine or normal saline 5 minutes before endometrial sampling and confirmed a decrease in pain in the group of mepivacaine infusion.⁹

In another study, Güler et al. randomly evaluated 120 patients divided into four groups; Group 1 received a paracervical block (3 ml of 2% prilocaine solution), Group 2 received 5 ml of 2% intrauterine lidocaine instillation.¹³ Group 3 received 400 mg of oral etodolac tablet 1 to 1.5 hours before the procedure. Group 4 received neither anesthesia nor anal-

gesia. The authors reported that pain scores in the intrauterine lidocaine group (Group 2) were found significantly lower than in the other 3 groups. In our study, because of the absence of a placebo group, the efficacy of intrauterine lidocaine for pain reduction could not be precisely evaluated. However, pain scores registered during endometrial sampling (VAS 0) of both groups were higher than pain scores 10 minutes after the procedure (VAS 10). This difference between pain scores (VAS 0 > VAS 10) may show the efficacy of intrauterine lidocaine instillation on pain reduction. Additionally, all of the previous four studies had placebo groups, and intrauterine lidocaine or mepivacaine instillation was found to be superior to the placebo group in reducing pain during the course of endometrial sampling.^{5,8,11,13}

A randomized trial by Cengiz et al. was conducted with 120 patients who experienced endometrial sampling.⁴ The trial compared the pain-reducing effects of a paracervical block and intrauterine lidocaine during a pipelle endometrial biopsy. They reported that intrauterine lidocaine was found to be superior in terms of pain reduction and may be the preferred anesthesia for endometrial biopsies. Similarly to our study, this study did not have a placebo group.

In a study by Şentürk et al. 206 patients were placed into random groups which received rectal indomethacin, intrauterine lidocaine and placebo during vaginoscopic hysteroscopy.¹¹ Rectal or intrauterine anesthesia applied with the vaginoscopic procedure was found to be effective in hysteroscopy as compared with the placebo group. In addition, intrauterine anesthesia was found to be more efficient than rectal indomethacin in reducing pain. Our study design was similar, but intrauterine lidocaine was not found to be superior to rectal indomethacin in reducing pain during the endometrial biopsy. Hysteroscopy may be more painful than endometrial biopsy and intrauterine anesthesia might be more efficient to reduce pain regarding hysteroscopy.

Edelman et al. assigned 80 women to receive 10 mL of one percent lidocaine or saline for abortions.¹⁴ They did not find any reduction in pain and reported this method as inadequate. In this study, after the

three minutes waiting period, endometrial curettage was completed in lidocaine group. The three minutes waiting period may be an insufficient amount of time for the intrauterine lidocaine to take effect. Also in our study, no significant distinction in pain reduction between indomethacin and lidocaine was obtained. This results may arise from an insufficient wait time for intrauterine lidocaine to take effect.

To our knowledge, our study is the first research to evaluate the effectiveness of rectal indomethacin and to compare its effectiveness as a pain reliever with intrauterine local anesthesia during endometrial biopsy with a Karman cannula. The participants had similar demographic features, and endometrial sampling was performed only on premenopausal women who had not experienced any pain prior to the procedure. The duration of the endometrial sampling is one of the important factors for evaluating pain during the procedure, because a prolonged period may cause the patients to feel more pain. In both groups, the procedure times were similar. The ease of administration of rectal indomethacin, with its simplicity in use, its absence of noted side effects, and its low cost, has much to commend it in minor gynecological procedures. The peak plasma concentration of indomethacin is reached 30 minutes after its rectal administration, and in our study we began the procedure 30 minutes after rectal administration of indomethacin.^{15,16}

The limitations of this study are the medium sample size and the absence of a control group due to ethical issues. Also, the subjective concept of pain among different patients can be considered as another limitation of the study. In our study, pain scores were checked before the procedure and also during and 10 minutes after the procedure. Our records display a sta-

tistically considerable reduction in pain scores throughout the endometrial sampling of both groups at 10 minutes after the process.

CONCLUSION

Rectal indomethacin was seen to be equal to intrauterine anesthesia for reducing pain during the endometrial biopsy. Rectal indomethacin may be an alternative method for relieving pain during gynecological procedures. Because of its easy administration, its use may be preferable in the future. Additional clinical research with larger sample sizes is needed to verify our findings.

Source of Finance

During this study, no financial or spiritual support was received neither from any pharmaceutical company that has a direct connection with the research subject, nor from a company that provides or produces medical instruments and materials which may negatively affect the evaluation process of this study.

Conflict of Interest

No conflicts of interest between the authors and / or family members of the scientific and medical committee members or members of the potential conflicts of interest, counseling, expertise, working conditions, share holding and similar situations in any firm.

Authorship Contributions

Idea/Concept: Sinem Demircan Karadağ, Mehmet Baki Şentürk; **Design:** Sinem Demircan Karadağ, Abdülkadir Turgut; **Control/Supervision:** Abdülkadir Turgut; **Data Collection and/or Processing:** Sinem Demircan Karadağ; **Analysis and/or Interpretation:** Cihan Karadağ; **Literature Review:** Sinem Demircan Karadağ; **Writing the Article:** Sinem Demircan Karadağ; **Critical Review:** Cihan Karadağ; **References and Findings:** Cihan Karadağ; **Materials:** Sinem Demircan Karadağ.

REFERENCES

- Spencer C, Whitehead MI. Endometrial assessment re-visited. *Br J Obstet Gynaecol.* 1999;106(7):623-32. [[Crossref](#)] [[PubMed](#)]
- Mercier RJ, Zerden ML. Intrauterine anesthesia for gynecologic procedures: a systematic review. *Obstet Gynecol.* 2012;120(3):669-77. PMID: 22914480. [[Crossref](#)] [[PubMed](#)] [[PMC](#)]
- Cooper JM, Erickson ML. Endometrial sampling techniques in the diagnosis of abnormal uterine bleeding. *Obstet Gynecol Clin North Am.* 2000;27(2):235-44. [[Crossref](#)] [[PubMed](#)]
- Cengiz H, Dağdeviren H, Kaya C, Yeşil A, Çaypınar SS. Comparing the efficacy of intrauterine lidocaine and paracervical block in decreasing the pain associated with endometrial biopsy: a randomised trial. *Arch Gynecol Obstet.* 2014;289(3):609-14. [[Crossref](#)] [[PubMed](#)]
- Trolice MP, Fishburne Jr C, McGrady S. Anesthetic efficacy of intrauterine lidocaine for endometrial biopsy: a randomized double-masked trial. *Obstet Gynecol.* 2000;95(3):345-7. [[Crossref](#)] [[PubMed](#)]
- Lau WC, Lo WK, Tam WH, Yuen PM. Paracervical anaesthesia in outpatient hysteroscopy: a randomised double-blind placebo-controlled trial. *Br J Obstet Gynaecol.* 1999;106(4):356-9. [[Crossref](#)] [[PubMed](#)]
- Lau WC, Tam WH, Lo WK, Yuen PM. A randomised double-blind placebo-controlled trial of transcervical intrauterine local anaesthesia in outpatient hysteroscopy. *BJOG.* 2000;107(5):610-3. [[Crossref](#)] [[PubMed](#)]
- Zupi E, Luciano AA, Valli E, Marconi D, Maneschi F, Romanini C. The use of topical anesthesia in diagnostic hysteroscopy and endometrial biopsy. *Fertil Steril.* 1995;63(2):414-6. [[Crossref](#)] [[PubMed](#)]
- Cicinelli E, Didonna T, Ambrosi G, Schönauer LM, Fiore G, Matteo MG. Topical anaesthesia for diagnostic hysteroscopy and endometrial biopsy in postmenopausal women: a randomised placebo-controlled double-blind study. *Br J Obstet Gynaecol.* 1997;104(3):316-9. [[Crossref](#)] [[PubMed](#)]
- Nagele F, Lockwoodb G, Magos AL. Randomised placebo controlled trial of mefenamic acid for premedication at outpatient hysteroscopy: a pilot study. *Br J Obstet Gynaecol.* 1997;104(7):842-4. [[Crossref](#)] [[PubMed](#)]
- Senturk MB, Guraslan H, Babaoğlu B, Yaşar L, Polat M. The effect of intrauterine lidocaine and rectal indomethacin on pain during office vaginoscopic hysteroscopy: randomized double-blind controlled study. *Gynecol Obstet Invest.* 2016;81(3):280-4. [[Crossref](#)] [[PubMed](#)]
- Jensen MP, Chen C, Brugger AM. Interpretation of visual analog scale ratings and change scores: a reanalysis of two clinical trials of postoperative pain. *J Pain.* 2003;4(7):407-14. [[Crossref](#)] [[PubMed](#)]
- Güler A, Şahin HG, Küçükaydın Z, Erdemoğlu E. Comparison of the efficacy of intrauterine lidocaine, paracervical block and oral etodolac for decreasing pain in endometrial biopsy. *J Turk Ger Gynecol Assoc.* 2010;11(4):178-81. [[Crossref](#)] [[PubMed](#)] [[PMC](#)]
- Edelman A, Nichols MD, Leclair C, Astley S, Shy K, Jensen JT. Intrauterine lidocaine infusion for pain management in first-trimester abortions. *Obstet Gynecol.* 2004;103(6):1267-72. [[Crossref](#)] [[PubMed](#)]
- Loza AM, Lomeli XR, Correa JG, Cobain CD, Guevara GC, Munoz FM, et al. Effect of the rectal administration of indomethacin on amylase serum levels after endoscopic retrograde cholangiopancreatography, and its impact on the development of secondary pancreatitis episodes. *Rev Esp Enferm Dig.* 2007;99(6):330-6.
- Tammaro S, Caruso R, Pallone F, Monteleone G. Post-endoscopic retrograde cholangiopancreatography pancreatitis: is time for a new preventive approach? *World J Gastroenterol.* 2012;18(34):4635-8. [[Crossref](#)] [[PubMed](#)] [[PMC](#)]