

# Mucinous Cystadenocarcinoma in Pregnancy

GEBELİK VEMÜSİNÖZ KİSTADENOKARSİNOM

Yrd.Doç.Dr.Cüneyt Eftal TANER\*, Dr.Kemal DOĞAN\*,  
Prof.Dr.Ali Ceylan ERDEN\*, Doç.Dr.Adem ASLAN\*\*

Departnment of Gynecology and Obstetrics Dicle University Faculty of Medicine

\*\* Departnment of Pathology, Dicle University Faculty of Medicine, DİYARBAKIR

## SUMMARY

*Carcinomas of the ovary have been very rarely diagnosed during pregnancy. A bulky mucinous cystadenocarcinoma in 32 weeks gestation is presented.*

**Keywords:** Mucinous cystadenocarcinoma, Pregnancy

Anatolian J Gynecol Obst 1992, 2:176-177

## ÖZET

*Gebelikte över kanserleri çok nadir olarak görülmektedir. 32 haftalık gebelikte görülen büyük bir müsinöz kistadenokarsinom olgusu sunuldu.*

**Anahtar Kelimeler:** Müsinöz kistadenokarsinom, Gebelik

T Klin Jinekoloj Obst 1992, 2:176-177

A 26 years old women, (S.D.) gravida 3 para 2 was referred to our hospital at 32 weeks gestation with the complaint of excessive abdominal distention. In her medical history there was two spontaneous normal labor and appendectomy which was performed a year ago. For the last gestation she had no any medical or obstetrical care. 20 days before admission to our hospital her complaints of excessive abdominal distention had began. She had discomfort of distention, nausea, anorexia and tachipne. Until that, she had no complaints other than physiological discomforts of pregnancy. Abdominal and bimanuel pelvic examination was unsatisfactory because of excessive distention. Ultrasound scan showed a normal fetus with a biparietal diameter 82 mm at 32 weeks gestation. Heart beat, amniotic fluid and fetal mowents were normal. There was a bulky multilobulated, septated cystic mass fulfilling the abdomen with ascites. The abdominal circumference of the patient was undertaken to laparotomy. 8 liters of fluid consisting ascites and boody ruptured cyst fluid was aspirated from the abdominal cavity. There was a bulky multilobulated partially ruptured cystic mass with the dimensions 40 by 50 cm. confining from the right ovary. Low segment cesarean section

was performed and a male infant weighing 1800 grams was delivered with the Apgar score 4/7. Operation was completed with total Hysterectomy and bilateral salpingoopheractomy and partial omentectomy. There were no visible tumoral infiltration on abdominal organs, peritoneum and paraortic lenf nodes. Histologic examination revealed a moderately differentiated mucinous cystadenocarcinoma of the right ovary, Stage IC, Grade II (FIGO). In pathologic investigation there were high cylindrical and low cuboidal epithelial cells which some of them contained mucine. The atypical cells had hyperchromatic nucleus at the basement and some of them had invasion to the stroma. There was no metastases on the tubes other ovary, uterus or placenta. Chemotherapy was given and 6 months after the operation the patient was in a well being condition and she had no metastasis in abdominal CAT.

## Comment

Carcinomas of the ovary have been very rarely diagnosed during pregnancy untill the last decade. The reported incidences vary from one in 12.000 to one in 50.000 with an avarage of, in 25.000 (1,2). In reviewing the world literature Jubb (3) had found 34 case of ovarian cancer associated with pergnancy in 1963. In 1988 T.V.Dessel (1) and associated reported that there were 22 additional cases of which 12 were serous and 4 mucinous carcinomas and they concluded the estimated frequency of mucinous cystadenocarcinoma in pregnancy is one in approximately 125.000. Later in 1989 T. Matsuyoma (4) reported 6 cases and a study

Geliş Tarihi: 14.12,1991

Kabul Tarihi: 11.1.1992

Yazışma Adresi: Yrd.Doç.Dr.Cüneyt Eftal TANER  
Dicle Üniversitesi Tıp Fakültesi Kadın  
Hastalıkları ve Doğum ABD,  
DİYARBAKIR

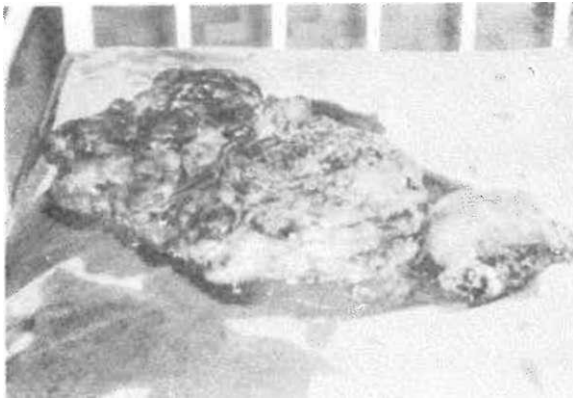


Figure 1 Uterus and mucinous cystadenocarcinoma after cesarean hysterectomy.

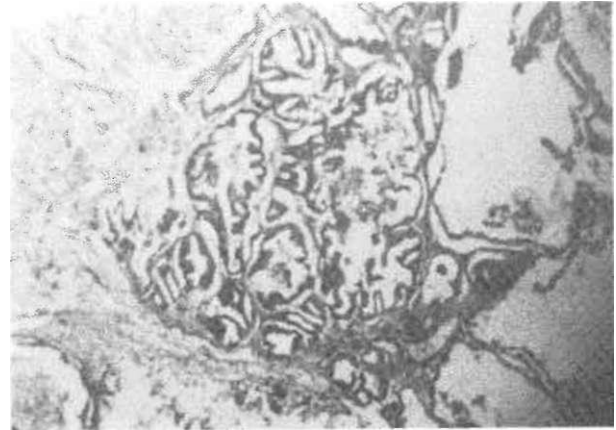


Figure 2. Histologic appearance of mucinous cystadenocarcinoma.

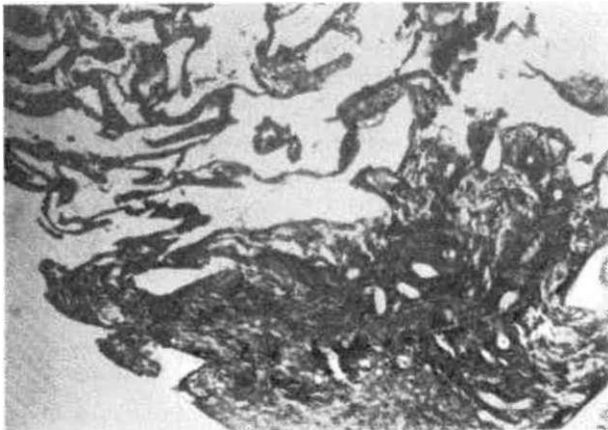


Figure 3. Histologic appearance of decidua in the same patient.

from Israel by R. Ogany (5) reported 23 more carcinomas in pregnancy. The majority of the patients with mucinous cystadenocarcinomas are in their 4th to 6th decades with a median age of 53 (6). This might explain the rarity of these tumors in pregnancy (7). In some cases the diagnosis is made incidentally during cesarean section with a complication like torsion or rupture (2,8). In asymptomatic women the diagnosis is very rare.

The cases after 16 weeks gestation are also very rare (1), and most of them are incidental at cesarean sections. Our case was at 32 weeks gestation and well adjusted with the last menstrual period. And with such a bulky tumor makes it more interesting. The management of ovarian tumors in pregnancy is surgical because of the various complications that may develop such as pelvic impaction, obstructed labor, torsion of the ovarian pedicle hemorrhage into the tumor, rupture

of the cyst, infection and malignancy (9). It can be stated that although very rare, ovarian malignancy is a significant possibility in any pregnant woman and should be undertaken to laparotomy regardless of the stage of gestation.

## REFERENCES

1. Dessel TV, Hameeteman TM, Wagenaar SS. Mucinous cystadenocarcinoma in pregnancy, case report. *Br J Obstet Gynecol* May 1988; 95:527-9.
2. Chung A, Birnbaum SJ. Ovarian Cancer associated with pregnancy *Obstet. Gynecol* Feb 1973; 41:2
3. Jubb ED. Primary ovarian carcinoma in pregnancy *Am J Obstet Gynecol* 1963; 85:345-54.
4. Matsuyama T, Tsukamoto N, Matsukuma K, et al. Malignant ovarian tumors associated with pregnancy report of six cases. *Int J Gynecol Obstet* 1989; 28(1):61-6.
5. Ogani R, Shohman Z. Ovarian carcinoma during pregnancy. A study of 23 cases in Israel between the years 1960 and 1984. *Isr Gynecol Oncol* 1989; 33(3):326-31.
6. Fenoglio CM, Richard RM. Common epithelial ovarian tumors in Sciarra's *Gynecology and Obstetric Rev.* edition 1987 Ed: JJ Sciarra, Harper and Row Publishers Philadelphia 4(30):21.
7. Woodruff SS and et al. Mucinous cystadenocarcinoma of the ovary *Obstet Gynecol* 51 (1):483-9.
8. Ahran J, Lakoffk, Miller R. Serous cystadenocarcinoma as incidental finding a repeat cesarean section. *Am J Obstet Gynecol* 1985; 153:78-9.
9. Disia PJ, Creasman WT. *Clinical Gynecologic Oncology* Third edition. The CV Mosby Company 1989; 11:325-416.